ACH Med J
(2025) 4: 133-137
ISSN:2822-5872
Doi : 10.5505/achmedj.2025.78941

CASE REPORT

Coexisting Complete Hydatidiform Mole and a Viable Fetus: A Rare Twin Pregnancy Case with Favorable Neonatal Outcome

Fikriye Karanfil Yaman[1]

[1]Necmettin Erbakan University Medical School, Department of Obstetrics and Gynecology, Division of Perinatology Konya/Türkiye

Article Info

Received Date : 02.10.2025
Revision Date : 01.12.2025
Accepted Date : 19.12.2025

Keywords:
Complete Hydatidiform Mole,
Twin Pregnancy,
Fetal Growth Restriction.

ORCIDs of the authors:
FKY :0000-0003-2773-7267

Abstract

Introductıon: The purpose of this article is to report a rare case of twin pregnancy complicated by a complete hydatidiform mole with a live fetus and to review the clinical challenges associated with its management.

Case Presentation: A 21-year-old woman in her third pregnancy with a history of one previous birth and one miscarriage was referred to our tertiary clinic at 21 weeks of gestation with a suspected molar pregnancy. Ultrasonography revealed a dichorionic twin pregnancy consisting of a normal fetus and its anterior placenta, along with a posterior placental mass with a "bunch of grapes" appearance. Laboratory findings showed markedly elevated β-hCG levels and suppressed TSH values. Amniocentesis confirmed a normal fetal karyotype, but concurrent mole tissue analysis was initially inconclusive. The pregnancy was closely monitored with weekly β-hCG and ultrasound assessments. At 33+6 weeks, an emergency cesarean section was performed due to vaginal bleeding, and a male baby weighing 1750 g was born. Postnatal histopathology confirmed a complete hydatidiform mole in one placenta and a normal placenta in the other. Postpartum β-hCG levels gradually decreased, and no evidence of gestational trophoblastic neoplasia was observed on follow-up.

Conclusion: Twin pregnancy with a complete hydatidiform mole and a coexisting fetus is an extremely rare condition associated with significant maternal and fetal risks. Careful monitoring t may allow favorable outcomes in selected cases where continuation of pregnancy is chosen.

Correspondence Address: Necmettin Erbakan Unıvercıty 42000 Konya - Türkiye
Phone: +90 506 302 41 51 / **e-mail:** fikriyekaranfilyaman@gmail.com

Copyright© 2025. This article is distributed under a Creative Commons Attribution 4.0 International License.
Follow this and additional works at: https://achmedicaljournal.com

Introduction

Twin pregnancies carry higher risks than singletons, and rare anomalies further complicate management.[1] One such condition is the coexistence of a complete hydatidiform mole (CHM) with a viable fetus. Hydatidiform mole, the most frequent gestational trophoblastic disease, results from abnormal trophoblastic proliferation and is classified as complete or partial, each with distinct features (2–4). The occurrence of CHM alongside a normal fetus is extremely uncommon, estimated at 1 in 20,000–100,000 pregnancies.[2]

Complete hydatidiform moles arise from abnormalities in early fertilization that disrupt normal genomic imprinting and parental gene balance. Most cases develop when an ovum lacking functional maternal chromosomes is fertilized, leading to a diploid conception composed entirely of paternal genetic material. Because maternally expressed imprinted genes such as p57/CDKN1C are absent, trophoblastic tissue proliferates extensively and villous structures become markedly edematous. Less frequently, dispermic fertilization or rare heritable imprinting defects may produce similar androgenetic or biparental patterns, each ultimately resulting in the characteristic overgrowth of molar placental tissue.[3]

In these cases, one placenta sustains normal fetal growth while the other is replaced by abnormal molar tissue.[4] CHM usually causes miscarriage or trophoblastic disease, but when a twin fetus develops normally, the pregnancy poses serious risks such as hemorrhage, preterm birth, and malignant progression.[5] Even when fetuses appear structurally normal, survival rates are low.[6]

Pregnant women in whom a complete mole coexists with a normal fetus are well known for placing both the mother and the fetus at considerable risk. On the maternal side, complications frequently arise from the excessive hormonal activity of the molar tissue, leading to early or recurrent bleeding, the development of preeclampsia often with an unusually early onset, and episodes of biochemical or symptomatic hyperthyroidism.[7,8] In line with previous case-based evidence, Erol et al. documented a CHMCF pregnancy complicated by severe preeclampsia and antepartum bleeding, supporting the view that maternal complications are common and may necessitate early delivery.[9] These pregnancies also carry a greater probability of progressing to gestational trophoblastic neoplasia. From the fetal perspective, impaired placental function is a persistent concern, contributing to growth restriction, intrauterine death, and a markedly increased likelihood of preterm birth. Together, these risks explain why overall outcomes remain guarded, even when the fetus appears structurally normal.

Managing these pregnancies is rarely straightforward. Clinicians are forced to balance maternal safety with the hope of continuing the pregnancy long enough to benefit the unaffected fetus, and this often means very close follow-up and decisions that are adjusted from week to week. In reality, many of these pregnancies are lost early or end because of maternal complications, although there are occasional reports of families choosing to continue and achieving a favorable result under strict monitoring[10]

The information available in the literature also shows that the outcomes in such cases are far from uniform. One of the earlier large-scale reports, a Japanese nationwide study, found that a notable proportion of women eventually developed persistent trophoblastic disease, particularly when the molar tissue was confirmed to be androgenetic.[11] Later publications presented a somewhat different picture. For example, a multicenter cohort from the Americas, which included more than seventy pregnancies, showed that a number of women who continued their pregnancies did reach live birth; however, the risk of post-molar neoplasia remained considerable and did not appear to be reduced in those who opted for termination.[12] More recent institutional series have echoed these findings, reporting frequent antenatal complications and a substantial incidence of GTN even in carefully monitored cases. A contemporary meta-analysis further emphasized how widely outcomes vary across studies, reinforcing that management strategies cannot rely on a single uniform recommendation but must be tailored to each patient's clinical situation.[13]

This report describes a twin pregnancy complicated by CHM and a surviving preterm infant, and reviews available literature to underline the clinical challenges and outcomes of this rare entity.

Case

A 21-year-old woman, gravida 3, parity 1, who had previously given birth vaginally once and had a complete miscarriage in the first trimester, with no chronic medical illnesses and a pre-pregnancy BMI of 24.1 kg/m² was referred to our tertiary health center in her 21st week of pregnancy with a preliminary diagnosis of molar pregnancy. This was a spon-

taneous conception. Ultrasound imaging revealed a dichorionic twin pregnancy with a viable fetus measuring below the 3rd percentile according to Hadlock reference curves with an anterior and normal placenta corresponding to 19 weeks' gestation and a posterior placental mass showing a 'bunch of grapes' appearance (89*34 mm) in the uterine cavity with multiple anechoic spaces, identified as a hydatidiform mole, with some of the placental tissue (figure1).

Initial laboratory tests showed markedly elevated β-hCG (222,771 mIU/mL), suppressed TSH

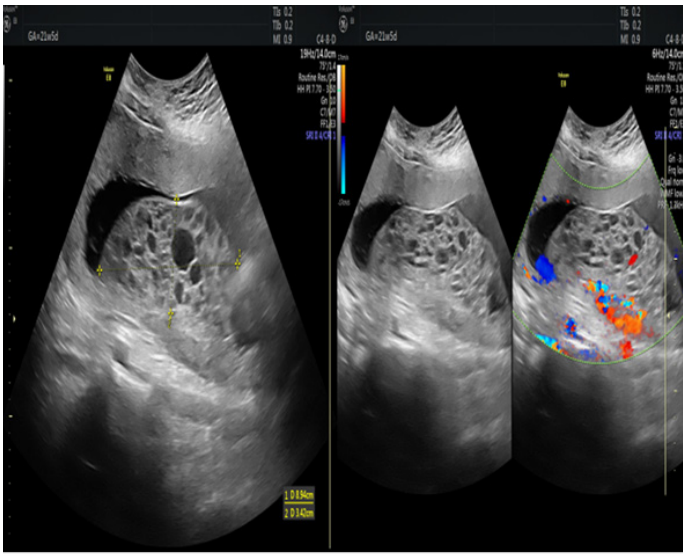

Figure1: A sonographic image of a molar placenta

(0.0647 µIU/mL) with slightly increased free T4, anemia (hemoglobin 10.5 g/dL), and normal tumor markers (CA-125, CA 19-9, CA 15-3).A 6×5 cm cystic mass, highly suggestive of a theca-lutein cyst secondary to excessive β-hCG was noted in the right adnexa. Iron and multivitamin supplementation was initiated. A sample of molar posterior placental tissue was taken using a chorionic villus sampling (CVS) needle for pathological and genetic analysis . Additionally, amniocentesis was performed on the viable fetus for genetic testing. Genetic analysis of the fetus was reported as normal, while pathology and genetic analysis of the molar tissue were did not provide sufficient viable material for molecular testing; therefore, genotyping methods such as SNP array, STR analysis, or PCR-based assays could not be completed, and assessment for paternal uniparental disomy was not feasible during pregnancy. Following delivery, the complete placental specimen became available for full evaluation, and histopathological examination confirmed the diagnosis of complete hydatidiform mole.

The patient and her family were informed about the maternal and fetal risks, including the option of termination. They chose to continue the pregnancy. Weekly β-hCG measurements and ultrasound examinations were performed, showing persistently elevated hormone levels and fetal growth restriction, but stable Doppler findings and amniotic fluid.

At 33+6 weeks of gestation, the patient presented with abdominal pain. Vital signs were stable (blood pressure: 110/70 mmHg, pulse rate :102 bpm). Ultrasound showed a live fetus with 30-week biometry (<1st percentile), normal Doppler flow, and adequate amniotic fluid. In anticipation of potential preterm delivery, Betamethasone (Celestone) was administered intramuscularly at a dose of 12 mg twice, 24 hours apart, for fetal lung maturation. The chest radiograph results were normal and the patient had no symptoms of preeclampsia. During follow-up, active vaginal bleeding was observed on examination, and an emergency cesarean section was performed.

A 1750 g male infant was delivered with a 1-minute Apgar score of 5 and was transferred to the neonatal intensive care unit. The molar placenta and the anterior normal placenta were both removed and sent for pathology

Postoperative β-hCG levels were:

- Day 1: 40.589 mIU/mL
- Day 2: 20.672 mIU/mL
- Day 9: 1.370 mIU/mL
- Day 16: 245 mIU/mL

The final pathology of the placenta was reported as:

Microscopic examination of placental tissues revealed small-diameter chorionic villi without trophoblastic proliferation in the anterior placenta (figure 2A, 2B). Immunohistochemical study showed no loss of immune reaction in the stromal cells of the villi with p57 (figure 2C). In the posterior placenta, chorionic villi showing marked hydropic changes and surrounded by proliferating trophoblastic cells were seen (figure 2D, 2E). Loss of immune expression with p57 was observed in the villous stromal cells and in most of the surrounding trophoblasts (figure 2F).

The baby was admitted to the neonatal unit due to being premature but was discharged 15 days later in good health, weighing 2250 grams. After delivery the patient was followed up closely. Serial β-hCG monitorization was performed weekly for three months, Then β-hCG levels were checked monthly and approximately five months later β-hCG

was negative. Chest imaging performed one month after birth revealed no abnormalities. Due to the ongoing risk of gestational trophoblastic disease in future pregnancies, she was counseled to seek evaluation at a specialized prenatal and gynecologic oncology center if she conceived again.

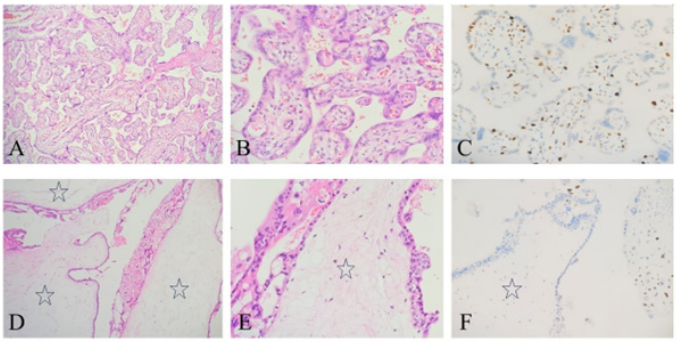

Figure2: Microscopic images of placental tissues are observed. A, B, and C belong to the first placenta; D, E, and F belong to the second placenta. In the first placenta, the trophoblastic cell arrangement and the dimensions of the chorionic villi are of normal histological appearance, and when the villi are examined stromally and seen as trophoblastic, p57 is positive. In the second placenta, trophoblastic cell proliferations are observed around the chorionic villi (stars) showing hydropic expansions, and while intermediate trophoblastic is recorded as positive with p57, there is a loss of reaction in the stromal and trophoblastic involvement in the villi (A, B, D, E: Hematoxylin/Eosin; C, F: Immunohistochemical p57 staining). A, D: 100x; B, C, E: 400x; F: 200x magnification).

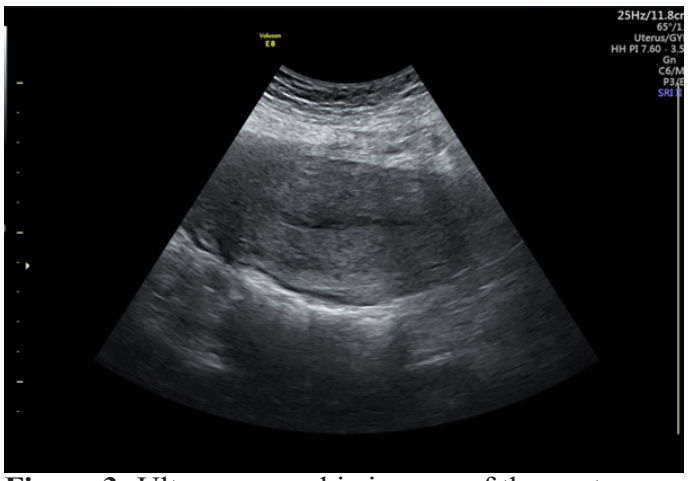

Figure 3: Ultrasonographic images of the postoperative endometrial cavity

Discussion

Twin pregnancies complicated by complete hydatidiform mole with a coexisting fetus (CHMCF) represent an extremely rare and high-risk condition. Complete moles are premalignant lesions characterized by androgenetic diploidy, markedly elevated β-hCG, and higher risks of complications such as hemorrhage, hyperthyroidism, and gestational trophoblastic neoplasia (GTN).[3,14,15] Pregnancies complicated by a complete mole with a coexisting fetus carry a considerably higher risk of developing gestational trophoblastic neoplasia (GTN). The incidence in the main cohorts is generally between 25% and 50%, reflecting variability in diagnostic treatments and follow-up protocols.[12,16]

Placental mesenchymal dysplasia (PMD) is an important differential diagnosis because it can mimic a molar pregnancy on ultrasound and often presents with extensive cystic changes and placental enlargement resembling a “grape-like” pattern.[17] However, PMD typically lacks trophoblastic proliferation and retains normal p57 expression, distinguishing it histologically from complete hydatidiform mole, in which loss of maternally expressed imprinted genes and peripheral trophoblastic hyperplasia are characteristic findings.[18] Furthermore, PMD is usually associated with a chromosomally normal fetus and is not accompanied by markedly elevated β-hCG levels or an increased risk of gestational trophoblastic neoplasia. These features help prevent misclassification when both a cystic placental mass and a viable fetus are present.[19]

The decision to continue or terminate such pregnancies remains controversial. Some reports, particularly from Asia, describe higher rates of GTN in CHMCF and advise termination.[11] Conversely, other series suggest that up to 60% of managed cases can result in live births and that termination does not necessarily reduce the risk of GTN.[12] These findings support an individualized approach, balancing maternal risks against the possibility of favorable neonatal outcomes.

Adverse perinatal outcomes are common, with fetal growth restriction (FGR), preterm delivery, and placental dysfunction frequently reported.[20] In our patient, progressive FGR led to preterm cesarean delivery, consistent with previous observations that molar tissue may compromise placental function. Diagnosis relies mainly on ultrasound, though its accuracy is limited; molecular and pathological evaluation may be required for confirmation.[21,22]

Postpartum surveillance is crucial, as the risk of GTN is higher in CHMCF compared with singleton moles, though most cases respond well to methotrexate-based therapy.[23]

This case emphasizes the need for vigilant antenatal surveillance, multidisciplinary care, and strict postpartum follow-up in achieving favorable outcomes in this rare entity.

References

1. Chauhan, S.P., et al., Twins: prevalence, problems, and preterm births. Am J Obstet Gynecol, 2010. 203(4): p. 305-15.
2. Shazly, S.A., et al., Twin pregnancy with complete hydatidiform mole and coexisting fetus following ovulation induction with a non-prescribed clomiphene citrate regimen: a case report. J Med Case Rep, 2012. 6: p. 95.
3. Berkowitz, R.S. and D.P. Goldstein, Clinical practice. Molar pregnancy. N Engl J Med, 2009. 360(16): p. 1639-45.
4. Braga, A., et al., Presentation, medical complications and development of gestational trophoblastic neoplasia of hydatidiform mole after intracytoplasmic sperm injection as compared to hydatidiform mole after spontaneous conception - a retrospective cohort study and literature review. Gynecol Oncol, 2023. 170: p. 179-185.
5. Lipi, L.B., L. Philp, and A.K. Goodman, A challenging case of twin pregnancy with complete hydatidiform mole and co-existing normal live fetus - A case report and review of the literature. Gynecol Oncol Rep, 2020. 31: p. 100519.
6. Atuk, F.A. and J.B.M. Basuni, Molar pregnancy with normal viable fetus presenting with severe pre-eclampsia: a case report. J Med Case Rep, 2018. 12(1): p. 140.
7. Ramsey, P.S., et al., Eclampsia complicating hydatidiform molar pregnancy with a coexisting, viable fetus. A case report. J Reprod Med, 1998. 43(5): p. 456-8.
8. Soto-Wright, V., et al., The changing clinical presentation of complete molar pregnancy. Obstet Gynecol, 1995. 86(5): p. 775-9.
9. Erol, S.A., et al., Nadir bir preeklampsi nedeni: Komplet tip mol hidatiform ve canlı fetusun birlikte bulunduğu ikiz gebelik vaka sunumu ve literatürün gözden geçirilmesi. Jinekoloji-Obstetrik ve Neonatoloji Tıp Dergisi, 2020. 17(1): p. 320-322.
10. Johnson, C., et al., Expectant Management of a Twin Pregnancy with Complete Hydatidiform Mole and Coexistent Normal Fetus. Case Rep Obstet Gynecol, 2019. 2019: p. 8737080.
11. Matsui, H., et al., Hydatidiform mole coexistent with a twin live fetus: a national collaborative study in Japan. Hum Reprod, 2000. 15(3): p. 608-11.
12. Lin, L.H., et al., Multiple pregnancies with complete mole and coexisting normal fetus in North and South America: A retrospective multicenter cohort and literature review. Gynecol Oncol, 2017. 145(1): p. 88-95.
13. Zorzato, P.C., et al., Hydatidiform Mole with Coexisting Normal Pregnancy: A Systematic Review and Individual Participant Data Meta-Analysis. Medicina, 2025. 61(10): p. 1781.
14. Osathanondh, R., et al., Hormonal measurements in patients with theca lutein cysts and gestational trophoblastic disease. J Reprod Med, 1986. 31(3): p. 179-83.
15. Azuma, C., et al., Application of gene amplification by polymerase chain reaction to genetic analysis of molar mitochondrial DNA: the detection of anuclear empty ovum as the cause of complete mole. Gynecol Oncol, 1991. 40(1): p. 29-33.
16. Zilberman Sharon, N., et al., Obstetric outcomes of twin pregnancies presenting with a complete hydatidiform mole and coexistent normal fetus: a systematic review and meta-analysis. Bjog, 2020. 127(12): p. 1450-1457.
17. Mittal, D., et al., Placental mesenchymal dysplasia: What every radiologist needs to know. Indian J Radiol Imaging, 2017. 27(1): p. 62-64.
18. Duncan, V.E., R.P. Kapur, and O.M. Faye-Petersen, Placental Mesenchymal Dysplasia, in Benirschke's Pathology of the Human Placenta. 2021, Springer. p. 753-770.
19. Tanuma, A., et al., Prenatal imaging and pathology of placental mesenchymal dysplasia: a report of three cases. Case Reports in Perinatal Medicine, 2016. 5(1): p. 9-14.
20. Bursać, D., et al., Prenatal diagnosis and management of pregnancy complicated by a coexisting mole: A case report. Radiol Case Rep, 2023. 18(10): p. 3410-3413.
21. Sheik, S., et al., Twin Pregnancy with a Complete Hydatidiform Mole and a Coexisting Live Fetus: Rare entity. Sultan Qaboos Univ Med J, 2015. 15(4): p. e550-3.
22. Himoto, Y., et al., Prenatal differential diagnosis of complete hydatidiform mole with a twin live fetus and placental mesenchymal dysplasia by magnetic resonance imaging. J Obstet Gynaecol Res, 2014. 40(7): p. 1894-900.
23. Niemann, I., L. Sunde, and L.K. Petersen, Evaluation of the risk of persistent trophoblastic disease after twin pregnancy with diploid hydatidiform mole and coexisting normal fetus. Am J Obstet Gynecol, 2007. 197(1): p. 45.e1-5.