DOI: 10.14744/eer.2025.97659
Eur Eye Res 2026;6(1):29–35

EUROPEAN EYE RESEARCH

ORIGINAL ARTICLE

Analysis of tear meniscus and anterior segment alterations in keratoconus patients after scleral contact lens

Cisil Erkan Pota, Yusuf Samet Atlıhan

Department of Ophthalmology, Akdeniz University Medical Faculty, Antalya, Turkiye

Abstract

Purpose: The objective of the study is to evaluate the effects of scleral contact lenses (ScL) wear on tear meniscus parameters and anterior segment changes in patients with keratoconus (KC).

Methods: This prospective study included 37 eyes of 23 KC patients fitted with ScLs (ICD FlexFit scleral lens, ABB Optical Group, USA). Best-corrected visual acuity (BCVA) and lens fitting parameters were assessed. Tear meniscus depth (TMD), tear meniscus area (TMA) and tear meniscus height (TMH) were evaluated using anterior segment optical coherence tomography (AS-OCT) along with anterior chamber depth (ACD), anterior chamber angle (ACA), anterior chamber volume (ACV), pupil diameter, and central corneal thickness (CCT) were measured before lens application and after 4 h of wear using corneal topography.

Results: According to the ABCD classification, 25 eyes were Stage 1, 9 eyes were Stage 2, and 3 eyes were Stage 3. The fitted ScLs had an average vault of 4369±453 µm, an average diameter of 16.1±0.37 mm, and a mean base curve of 7.64±0.71 mm. BCVA improved significantly after ScL from 0.25±0.11 to 0.018±0.05 logMAR. The mean tear reservoir thickness was 315±50 µm. Although no statistically significant changes were observed in parameters such as ACA, ACD, ACV, and CCT, a significant reduction in TMH, TMD, and TMA values was observed after lens wear ($p<0.001$).

Conclusion: ScLs are an effective treatment option to improve visual quality in patients with KC. Although scleral lenses have no direct contact with the cornea, TMH decreased within hours of wear. Changes in anterior segment parameters, as well as lens fitting, can be evaluated using AS-OCT and corneal topography.

Keywords: Anterior segment parameters; meniscus height; scleral contact lenses; tear fluid reservoir; tear meniscus depth; tear tear meniscus area

Rigid, gas-permeable lenses that are supported by the conjunctival tissue covering the scleral surface and that vault over the limbus and cornea have been defined as scleral contact lenses (ScLs). While ScLs are in direct contact with the conjunctiva, there is a tear reservoir between the limbus and the cornea. A lens that is completely on the sclera is considered a ScL, regardless of its size.[1]

ScL lenses are used to correct corneal irregularities, to treat ocular surface diseases, and for cosmetic purposes. Even after successful corneal surgery, ScL lenses are an effective treatment option to restore vision in most patients due to residual corneal irregularities and astigmatism (AST). They provide a method that improves vision and creates a smooth optical surface by correcting the visual distortions caused by an irregular cornea.[2]

In addition, the tear reservoir between the cornea and the lens ensures continuous hydration of the cornea, protection, and moisture, which is beneficial in the

Cite this article as: Erkan Pota Ç, Atlıhan YS. Analysis of tear meniscus and anterior segment alterations in keratoconus patients after scleral contact lens. Eur Eye Res 2026;6(1):29–35.

Correspondence: Cisil Erkan Pota, M.D. Department of Ophthalmology, Akdeniz University Medical Faculty, Antalya, Turkiye
E-mail: cisilerkann@gmail.com
Submitted Date: 13.06.2025 **Revised Date:** 09.08.2025 **Accepted Date:** 04.09.2025 **Available Online Date:** 29.04.2026

OPEN ACCESS This is an open access article under the CC BY-NC license (http://creativecommons.org/licenses/by-nc/4.0/).

treatment of ocular surface diseases. This is particularly effective in cases of severe dry eye disease, neurotrophic keratopathy and graft-versus-host disease. In addition, it provides mechanical protection in cases such as entropion, trichiasis, and chemical injury and supports the healing of persistent epithelial defects.[1,3]

Another important feature of ScL lenses is their ability to reduce the need for keratoplasty in patients with severe corneal disease.[4] The scope of their clinical applications is constantly expanding. Their role in the tear film and the health of the ocular surface has also attracted considerable interest. Changes in the tear film when wearing contact lenses can directly affect the quality of vision. As the front surface of contact lenses is the most important refractive surface, it is important that the optical surface is always clean and sufficiently hydrated. Disturbing the stability of the tear film can increase light scattering and lead to optical aberrations. However, innovative lens materials and designs, such as those used in ScL, aim to minimize these effects by optimizing the protection of the ocular surface.

Changes in tear film stability during contact lens wear have been associated with factors such as thinning of the lipid component, acceleration of the tear film thinning process, and an increase in evaporation rate.[5] A better understanding of how these changes affect the tear reservoir is critical to discovering the therapeutic potential of ScL. Current studies aim to gain more insight into the clinical efficacy of these lenses, particularly by assessing the height of the tear meniscus and other tear film parameters.[5]

Approximately half of the contact lens wearers report symptoms such as dryness, stinging, and discomfort. ScLs tend to be more demanding in terms of wearing comfort and the fitting process, especially compared to soft contact lenses.[6] In this context, a stable tear film and ocular surface play a crucial role in the successful use of ScLs and in facilitating patient adaptation.[7]

In recent years, the therapeutic potential of ScLs has attracted considerable attention due to their effects on the health of the ocular surface and tear film. Examination of the tear meniscus in ScL wearers using anterior segment optical coherence tomography (AS-OCT) may not only improve the understanding of the clinical efficacy of these lenses, but also provide new perspectives for therapeutic approaches.

Our aim in this study is to investigate the short-term effects of scleral lenses in individuals with keratoconus (KC), to evaluate changes in tear film parameters and anterior segment parameters, and to perform an analysis of clinical findings related to the lens fitting process.

Materials and Methods

This study was conducted at the Akdeniz University Hospital, Department of Ophthalmology. The project was approved by This study was approved by the Akdeniz University Medical Faculty Institutional Ethics Committee (Date: 24.04.2025, Decision no: 378). Informed consent was obtained from all participants after explaining the study requirements. The clinical study adhered to the principles of the Declaration of Helsinki.

Inclusion Criteria

1. Age between 16 and 55 years
2. No contraindications to contact lens use
3. Diagnosis of KC.

Exclusion Criteria

1. Pre-existing systemic or ocular diseases affecting contact lens use
2. History of eye trauma or corneal surgery
3. Previous ScLs use
4. Presence of any anterior segment pathology, corneal abnormalities other than KC, chronic dry eye, Sjögren's syndrome, Meibomian gland dysfunction, ocular cicatricial pemphigoid, or any other disease that may cause dry eye.

Application of the Scleral Lens

The ScLs were manufactured from a cross-linked copolymer (ICD FlexFit Scleral Lens, ABB Optical Group, USA) with diameters ranging from 14.50 to 17.00 mm, a central thickness between 0.10 and 2.00 mm, a refractive index of 1.432 and an oxygen permeability (Dk/t) of 130×10^{-11} (cm^2/s) [(mL O_2/mL × mmHg)].

The ABCD grading system was used to classify KC.[8] Measurements were taken before and 4 h after lens application. Each participant underwent an ophthalmological examination, including visual acuity, refraction measurement, slit lamp biomicroscopy, and corneal topography with the Pentacam (Oculus Optikgeräte GmbH, Wetzlar, Germany). The tear meniscus was assessed using optical coherence tomography (OCT) (Triton, Topcon, Tokyo, Japan).

The subjects were fitted with scleral lenses of different diameters (ICD FlexFit Scleral Lens, ABB Optical Group, Atlanta, USA). All ScLs used in this study were selected from a diagnostic fitting set and fitted according to the instructions. Lens fitting was performed according to the fitting instructions provided by the manufacturer.

An attempt was made to keep the thickness of the fluid reservoir (FR) close to the recommended values for the lens.[9] After insertion of the lens, the initial fitting was assessed with a slit-lamp examination. During this evaluation, the position of the lens, the fluorescein distribution, the presence of air bubbles, the pressure of the lens periphery on the conjunctiva, and conjunctival blanching were assessed to determine the suitability of the lens.

Patients had no previous history of contact lens wear (scleral lenses, rigid gas permeable contact lenses, hybrid lenses, or soft contact lenses). The patients who underwent corneal cross-linking had a postoperative period of more than 1 year. In all participants, the ScL was filled with preservative-free artificial tears before insertion. The thickness of the FR between the cornea and the posterior lens surface was checked using AS-OCT, and the most suitable lenses were fitted for each patient. After fitting, the final overrefraction was performed. All lenses used in this study were spherical; astigmatic lenses were not fitted during the study. The lens fitting was considered acceptable for all subjects involved in the study.

At baseline (without ScL) and 4 h after the application of ScL, tear meniscus depth (TMD), tear meniscus height (TMH), and tear meniscus area (TMA) were analyzed with AS-OCT (Triton, Topcon, Tokyo, Japan) (Fig. 1).

AS-OCT was performed in combination with a slit-lamp to examine the parameters of the tear meniscus of the lower eyelid, with the image taken at the 6 o'clock position just below the center of the pupil. The TMA was calculated based on previous studies as the triangular area bounded by the anterior margin of the lower eyelid, the anterior corneal margin, and the anterior border of the tear meniscus. ImageJ software (version 1.53t; National Institutes of Health, Bethesda, MD, USA) was used for image analysis (http://imagej.nih.gov/ij/).[10] During the measurements, the measurement tool integrated in the OCT software was used to mark the height and depth of the tear meniscus to obtain linear measurements in micrometers (μm).[11] The same anatomical points were then identified in the ImageJ software, and the measurements obtained from the OCT device were entered as a reference scale (Fig. 2). These linear measurements were used to calculate the area of the tear meniscus using ImageJ software. The corresponding region was manually delineated in ImageJ based on the same anatomical landmarks, and the reference length obtained from the OCT device was applied. The software then automatically calculated the enclosed area and reported the result in square micrometers (μm^2) (Fig. 3). To avoid the effects of delayed blinking, OCT measurements were performed immediately after blinking. Measurements were taken between 1 and 2 p.m. to avoid the effects of diurnal variations (ambient lighting was 10 lux).

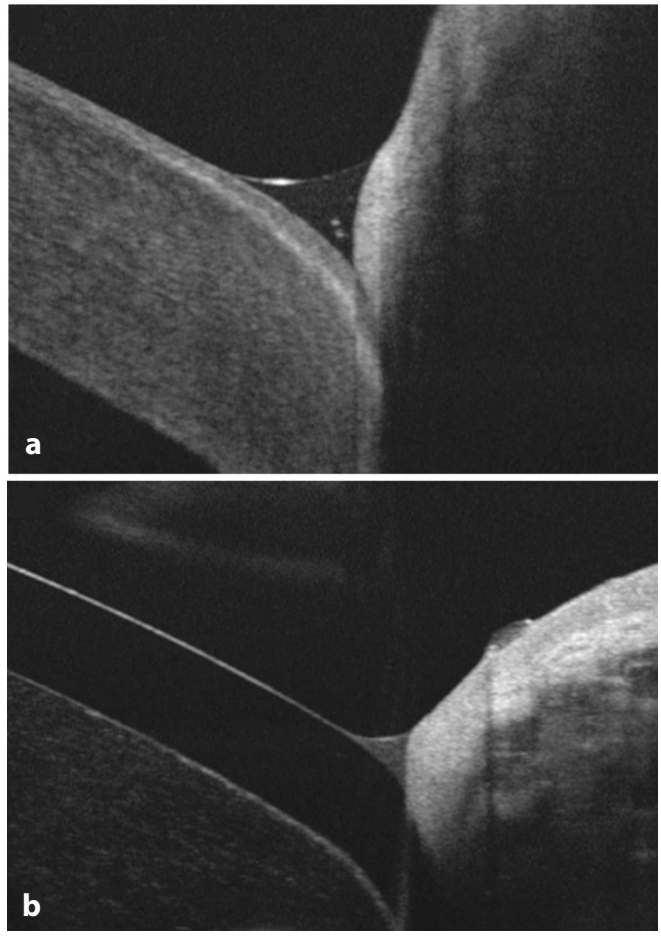

Fig. 1. Visualization of tear meniscus with anterior segment optical coherence tomography; **(a)** Image of tear meniscus before scleral lens. **(b)** Image of a tear meniscus after a scleral lens.

The thickness of the tear reservoir was measured with OCT of the anterior segment by measuring the distance between the corneal apex and the inner surface of the lens (Fig. 4).[12]

Before wearing the ScL, patients' corneal topography was measured, including Kmax (steep keratometric value), Kmean (mean of Kflat and Ksteep), thinnest corneal thickness (TCT), central corneal thickness, and AST.

In addition, anterior chamber parameters such as anterior chamber angle (ACA), anterior chamber volume (ACV), anterior chamber depth (ACD), and pupil diameter were measured and compared using corneal topography both before wearing the ScL and 4 h after fitting the lenses.

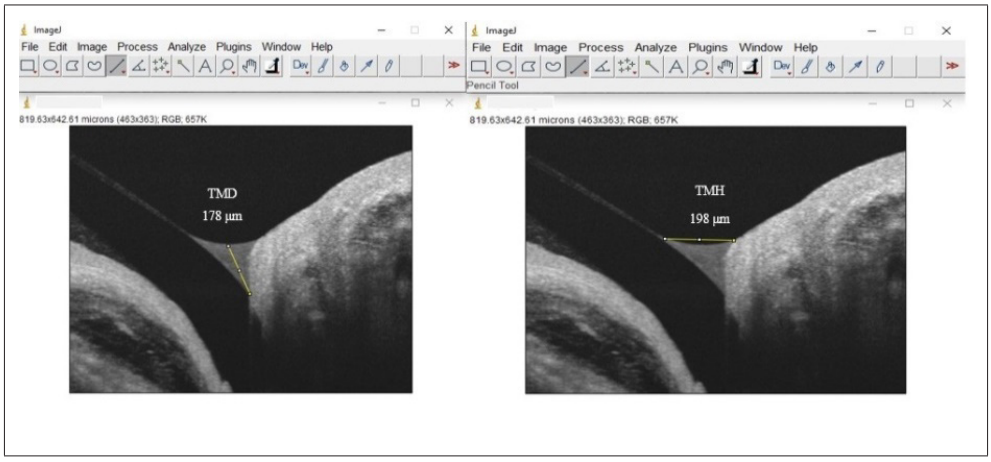

Fig. 2. Measurement of tear meniscus depth and tear meniscus height using ImageJ software.

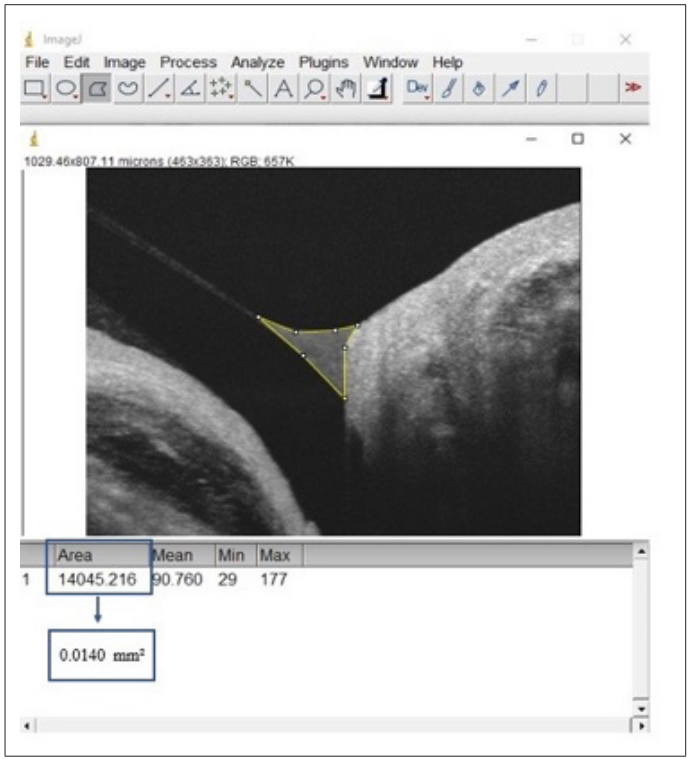

Fig. 3. Measurement of tear meniscus area using ImageJ software, blue box indicating.

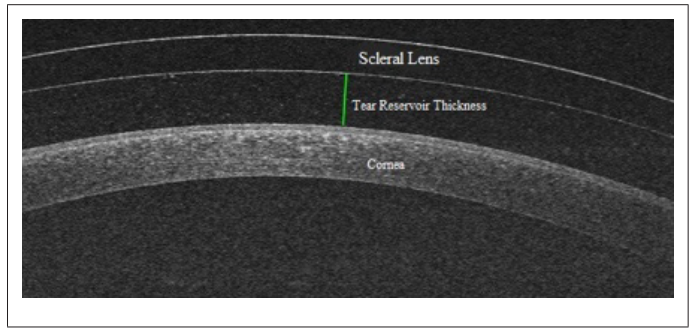

Fig. 4. Evaluation of tear reservoir thickness with anterior segment optical coherence tomography.

Statistical Analysis

The IBM Statistical Package for Social Sciences (SPSS) software (version 26.0; SPSS Inc., Chicago, IL, USA) was used for the statistical analyses. In the power analysis conducted with the GPower 3.1 programme, the effect size was set at 0.90 power (1-beta), 0.05 margin of error (alpha), and the minimum sample size to be included in the study was n=21.[13] The normality of the sample distribution was tested using the Kolmogorov–Smirnov test. For descriptive statistics, non-normally distributed variables were expressed as median (minimum–maximum) and normally distributed variables as mean±standard deviation. For the comparison of continuous variables, the Wilcoxon signed-rank test was used for data that did not follow a normal distribution, and the paired-samples t-test was used for normally distributed data.

Results

The study included 37 eyes of 23 patients diagnosed with KC who showed improved visual acuity after ScL fitting. Of the patients, 12 (52.17%) were male, and 11 (47.83%) were female. Sixteen right eyes (43.25%) and 21 (56.75%) left eyes were included. The mean age of the patients was 33±11.5 years (range: 16–51). According to the ABCD classification, 25 eyes were in Stage 1, 9 eyes in Stage 2, and 3 eyes in Stage 3. Had undergone corneal cross-linking treatment. In total, 12 eyes of 7 patients underwent corneal crosslinking treatment.

Before lens application, the best-corrected visual acuity (BCVA) was 0.25±0.11 logMAR, while after lens application, the BCVA improved to 0.018±0.05 logMAR. In all cases, OCT of the AS-OCT showed an adequate tear reservoir, no significant compression of the midperipheral conjunctiva,

Table 1. Data are expressed as mean±standard deviation (minimum–maximum)

	Mean±standard deviation (minimum–maximum)
Age (years)	33±11.5 (16–51)
Kmax (D)	52.6±4.11 (48–61)
Kmean (D)	46.5±2.3 (44–50)
Astigmatism (D)	4.6±1.9 (2.9–8.6)
TCT (µm)	475±38 (431–555)
Tear reservoir thickness (µm)	315±50 (180–425)
ScL vault (µm)	4369±453 (3800–5200)
ScL diameter (mm)	16.1±0.37 (15.5–16.3)
ScL base curve (mm)	7.64±0.71 (6.25–8.85)

Kmean: Arithmetic mean of the steepest curve (Kmax) and the flattest curve; TCT: Thinnest corneal thickness; ScL: Scleral lens; D: Diopters; µm: Micrometer; mm: Millimeter.

and optimal edge alignment was observed on both slit-lamp biomicroscopy and AS-OCT evaluation.

The mean TCT was 475±38 µm, Kmax was 52.6±4.11 D, Kmean was 46.5±2.3 D and AST was 4.6±1.9 D. The lens-related parameters are summarized in Table 1. The mean thickness of the tear reservoir was 315±50 µm. The fitted ScLs had a mean curvature of 4369±453 µm, a mean diameter of 16.1±0.37 mm, and a mean base curve of 7.64±0.71 mm.

Visual acuity improved significantly after lens wear (from 0.25±0.11 logMAR to 0.018±0.05 logMAR). No statistically significant difference in pupil diameter, TCT, ACA, ACV, or ACD was observed after wearing the ScL. However, a statistically significant decrease in TMH, TMD, and TMA values was observed ($p<0.001$) (Table 2).

Table 2. Evaluation of visual acuity, tear meniscus values, and anterior segment parameters of the patients before and after scleral lens fitting

	Before scleral lens	After scleral lens	*p*
Visual acuity (Snellen)	0.57±0.13 (0.40–0.70)	0.96±0.1 (0.70–1)	<0.001
Visual acuity (logMAR)	0.25±0.11 (0.15–0.40)	0.018±0.05 (0–0.15)	<0.001
TMH (mm)	0.293±0.085 (0.115–0.378)	0.199±0.051 (0.110–0.331)	<0.001
TMD (mm)	0.216±0.059 (0.100–0.270)	0.154±0.042 (0.105–0.218)	<0.001
TMA (mm^2)	0.0268±0.0102 (0.006–0.039)	0.0155±0.0071 (0.0044–0.025)	<0.001
Pupil Diameter (mm)	3.7±1 (2.21–5.66)	3.94±0.98 (2.89–5.35)	0.480
CCT (µm)	485±50.2 (457–556)	486±50.5 (430–550)	0.728
ACD (mm)	3.79±0.4 (3–4.15)	3.71±0.91 (1.44–4.33)	0.543
ACA (°)	35.8±9.1 (21.5–43.8)	34.6±8.4 (23–38)	0.516
ACV (mm^3)	186.2±32.8 (103–251)	183.7±43.1 (105–250)	0.226

SD: Standard deviation; logMAR: Logarithm of the minimum angle of resolution; mm: Millimeter; µm: Micrometer; TMA: Tear meniscus area, TMD: Tear meniscus depth; TMH: Tear meniscus height; CCT: Central corneal thickness; ACV: Anterior chamber volume; ACD: Anterior chamber depth; ACA: Anterior chamber angle are expressed as mean±SD.

Discussion

In this study, the use of ScL improved visual acuity in all patients. We found that OCT imaging of the anterior segment is a useful method to evaluate the thickness of the tear reservoir during ScL fitting. A reduction in tear meniscus parameters was noted 4 h after wearing ScL.

KC leads to irregular AST and distortion of the corneal shape, resulting in visual disturbances.[14] In the early stages of KC, vision can often be corrected with spectacles; however, as the disease progresses, the use of ScL becomes a critical treatment option.[15] Previous studies have investigated lens fitting and tear reservoir using AS-OCT. In one study, the average thickness of the tear reservoir after 5 h of ScL wear was reported to be 294.3±137.5 µm, which is comparable to the results of our study. The study showed that removing and reapplying a scleral lens with fresh saline can increase the thickness of the FR. However, this change in the thickness of the FR had no significant effect on visual acuity, the extent of light disturbance, or the quality of vision.[16]

ScLs have no direct contact with the cornea, which means that the lens is subject to less mechanical stress and is less uncomfortable. Studies have shown that ScLs are more favorable for KC patients in terms of comfort and visual acuity than other lens types.[17] Although the FR between the lens and the ocular surface provides additional comfort by relieving dry eye discomfort, some patients wearing these lenses may experience blurred vision throughout the day.[15,18,19] Although the FR formed between the lens and the cornea generally maintains the moisture balance of the tear film and alleviates dry eye symptoms, some patients wearing ScL may experience blurred vision, foreign-body sensation, and temporary visual disturbances after removing the lens. For this reason, regular follow-up care is important for ScL wearers.

An important cause of blurred vision in ScL wearers is midday fogging (MDF). Previous studies have investigated the effects of these values on MDF. In one study, white blood cells, primarily neutrophils, were found in the tear film under ScLs, and individuals with higher corneal clearance from their ScLs are more likely to suffer from MDF.[18] In another study, an increased concentration of MMP-9 and MMP-10 was found in the FR after wearing ScLs for several hours.[21] It is assumed that changes in the FR during the course of the day can cause this situation. Further studies are needed to investigate the change in fluid in the FR throughout the day and its effects on MDF.

In a study examining anterior chamber changes after ScL application in healthy individuals, a decrease in ACD and ACA values was noted, but the difference was not statistically significant.[9] The aforementioned study found that the clinical significance of anterior chamber and trabecular iris angle changes was limited in healthy individuals with open angles.[9] In our study, there was a similar decrease in ACA, ACV, and ACD values, but the difference was not statistically significant.

In our study, a significant decrease in TMD, TMH, and TMA values was observed after ScL was used. Previous studies have found that the use of soft contact lenses leads to lower TMA values and makes the tear meniscus more unstable and susceptible to evaporation.[22] According to the data obtained in our study, a 42.1% decrease in TMA was observed during the day when wearing ScL.

During the use of ScL, the thickness of the lens and the presence of FR can lead to symptoms of corneal hypoxia. The oxygen permeability values and thin design of modern ScL have led to the notion that this hypoxic effect can be eliminated, but definitive evidence on this topic is not yet available.[15] The thickness of the FR between the lens and the cornea may reduce oxygen delivery.[20] Previous studies have found that the target thickness of the reservoir varies between 200 and 600 µm.[23,24] Taking into account factors such as ScL thickness, oxygen permeability, and tear exchange, the thickness of the FR has been associated with the development of corneal edema. Previous studies have shown that individuals with healthy corneas can generally tolerate ScLs with FR of 700–800 µm during short-term wear (≥100 min), provided the lens material has a high oxygen permeability.[12] It has been reported that central corneal edema in ScL increases with FR thickness, but reaches a plateau at around 600 µm.[12] In our study, the mean thickness of the FR was calculated to be 315±50 µm, similar to the values of 250–400 µm previously reported by manufacturers for lens fitting.[9]

There are some limitations to our study. The first is the small number of patients and the short duration of lens use. The data of the patients after a long-term follow-up are not available. Larger studies are needed to assess long-term outcomes. Another limitation of our study is that there is no subjective or biochemical data on MDF. A final limitation is that no subgroup analysis could be performed because the number of subgroups was unequal, and the number of eyes in some groups was small. The strength of our study is that this is the first study in the literature to prospectively compare TMD, TMA, and TMH values and evaluate them with anterior segment parameters after wearing ScL.

Conclusion

ScL offers significant improvement in vision for people with KL. Although these lenses avoid direct contact with the cornea, a significant reduction in tear meniscus measurements was observed after only a few hours of wear. This emphasizes the need to regularly check the tear film and FR dynamics in patients wearing ScL.

Ethics Committee Approval: This study was approved by the Akdeniz University Medical Faculty Institutional Ethics Committee (Date: 24.04.2025, Decision no: 378).

Informed Consent: Written informed consent was obtained.

Conflict of Interest: None declared.

Financial Disclosure: The author declared that this study has received no financial support.

Use of AI for Writing Assistance: None declared.

Authorship Contributions: Concept: Ç.E.P., Y.S.A.; Design: Ç.E.P., Y.S.A.; Supervision: Ç.E.P.; Resource: Ç.E.P., Y.S.A.; Materials: Ç.E.P., Y.S.A.; Data collection and/or processing: Ç.E.P., Y.S.A.; Analysis and/or interpretation: Ç.E.P., Y.S.A.; Literature review: Ç.E.P., Y.S.A.; Writing: Ç.E.P., Y.S.A.; Critical review: Y.S.A.

Peer-review: Externally peer-reviewed.

References

1. Schornack MM. Scleral lenses: a literature review. Eye Contact Lens 2015;41:3–11. [CrossRef]
2. Pullum KW, Whiting MA, Buckley RJ. Scleral contact lenses: the expanding role. Cornea. 2005;24:269–77. [CrossRef]
3. Bavinger JC, DeLoss K, Mian SI. Scleral lens use in dry eye syndrome. Curr Opin Ophthalmol 2015;26:319–24. [CrossRef]
4. Koppen C, Kreps EO, Anthonissen L, Van Hoey M, Dhubhghaill SN, Vermeulen L. Scleral lenses reduce the need for corneal transplants in severe keratoconus. Am J Ophthalmol 2018;185:43–7. [CrossRef]

5. Montani G, Martino M. Tear film characteristics during wear of daily disposable contact lenses. Clin Ophthalmol 2020 4;14:1521–31. [CrossRef]
6. Guillon M, Maissa C. Dry eye symptomatology of soft contact lens wearers and nonwearers. Optom Vis Sci 2005;82:829–34. [CrossRef]
7. Downie LE, Craig JP. Tear film evaluation and management in soft contact lens wear: a systematic approach. Clin Exp Optom 2017;100(5):438–58. [CrossRef]
8. Belin MW, Duncan JK. Keratoconus: The ABCD grading dystem. Klin Monbl Augenheilkd 2016;233:701–7. [CrossRef]
9. Queiruga-Piñeiro J, Barros A, Lozano-Sanroma J, Fernández-Vega Cueto A, Rodríguez-Uña I, Merayo-LLoves J. Assessment by optical coherence tomography of short-term changes in iop-related structures caused by wearing scleral lenses. J Clin Med. 2023;12:4792. [CrossRef]
10. Czajkowski G, Kaluzny BJ, Laudencka A, Malukiewicz G, Kaluzny JJ. Tear meniscus measurement by spectral optical coherence tomography. Optom Vis Sci 2012;89:336–42. [CrossRef]
11. Karadeniz Ugurlu S, Altın Ekin M, Aytogan H. Assessment of tear meniscus by optical coherence tomography in patients with canalicular laceration repair. Int Ophthalmol 2020;40:13–8. [CrossRef]
12. Fisher D, Collins MJ, Vincent SJ. Fluid Reservoir Thickness and Corneal Edema during Open-eye Scleral Lens Wear. Optom Vis Sci 2020;97:683–9. [CrossRef]
13. Faul F, Erdfelder E, Lang AG, Buchner A. G*Power 3: a flexible statistical power analysis program for the social, behavioral, and biomedical sciences. Behav Res Methods 2007;39:175–91. [CrossRef]
14. Ciftci MD, Degirmenci C, Palamar M. Evaluation of scleral thickness in patients with keratoconus. Eye Contact Lens 2025;51:214–9. [CrossRef]
15. Şengör T, Aydın Kurna S. Update on contact lens treatment of keratoconus. Turk J Ophthalmol 2020;50:234–44. [CrossRef]
16. Seco R, Macedo-de-Araújo RJ, González-Méijome JM. Influence of scleral lens removal and reapplication on fluid reservoir thickness and visual quality after 5 h of lens wear. Cont Lens Anterior Eye 2025;48:102392. [CrossRef]
17. Levit A, Benwell M, Evans BJW. Randomised controlled trial of corneal vs. scleral rigid gas permeable contact lenses for keratoconus and other ectatic corneal disorders. Cont Lens Anterior Eye 2020;430:543–52. [CrossRef]
18. Postnikoff CK, Pucker AD, Laurent J, Huisingh C, McGwin G, Nichols JJ. Identification of leukocytes associated with midday fogging in the post-lens tear film of scleral contact lens wearers. Invest Ophthalmol Vis Sci 2019;60:226–33. [CrossRef]
19. Alipour F, Kheirkhah A, Jabarvand Behrouz M. Use of mini scleral contact lenses in moderate to severe dry eye. Cont Lens Anterior Eye 2012;35:272–6. [CrossRef]
20. Bergmanson JP, Walker MK, Johnson LA. Assessing scleral contact lens satisfaction in a keratoconus population. Optom Vis Sci 2016;93:855–60. [CrossRef]
21. Walker MK, Lema C, Redfern R. Scleral lens wear: Measuring inflammation in the fluid reservoir. Cont Lens Anterior Eye 2020;43:577–84. [CrossRef]
22. Guillon M, Maissa C. Contact lens wear affects tear film evaporation. Eye Contact Lens 2008;34:326–30. [CrossRef]
23. Arlt C. Clinical effect of tear layer thickness on corneal edema during scleral lens wear. Aalen University; 2015. [Article in Master's Thesis].
24. Tan B, Zhou Y, Yuen TL, Lin K, Michaud L, Lin MC. Effects of scleral-lens tear clearance on corneal edema and post-lens tear dynamics: A pilot study. Optom Vis Sci 2018;95:481–90. [CrossRef]