



## Original Research

# Comparison of the Therapeutic Effects of Intra-Articular Injection of Ozone and Corticosteroid in Knee Osteoarthritis

Aylin Ayyildiz,<sup>1</sup> Selda Ciftci Inceoglu,<sup>2</sup> Beril Dogu,<sup>2</sup> Banu Kuran<sup>2</sup>

<sup>1</sup>Department of Physical Medicine and Rehabilitation, Çam and Sakura City Hospital, İstanbul, Türkiye

<sup>2</sup>Department of Physical Medicine and Rehabilitation, University of Health Sciences, Şişli Hamidiye Etfal Training and Research Hospital, İstanbul, Türkiye

### Abstract

**Objectives:** Knee osteoarthritis (KOA) is a chronic condition that gradually reduces functional capacity and limits daily activities. Treatment methods in the early stages of the disease are still under discussion. The efficacy of ozone therapy versus corticosteroid injection in treating KOA is examined in this study.

**Methods:** This randomized clinical trial involved 60 patients aged 40-85 years who had been experiencing knee pain for at least 6 months and had received a clinical diagnosis of knee osteoarthritis through radiologic imaging. The patients were randomly assigned to two groups. One group received an intra-articular injection of 10 mL 15 µg/ml ozone for three sessions with a one-week interval, while the second group received a 1 mL intra-articular injection of betamethasone. All patients were evaluated before treatment, as well as 4 and 12 weeks after the first dose of treatment. The study evaluated treatment efficacy using the Visual Analog Scale (VAS) and the Western Ontario and McMaster Universities Arthritis Index (WOMAC).

**Results:** The study participants had a mean age of 62.2±10 years, and 90% of them were female. Upon comparing the VAS and WOMAC scores with their respective pretreatment scores, both groups showed significant decreases at week 4 and week 12. Notably, the ozone group exhibited a significantly greater improvement in VAS and WOMAC scores at week 4.

**Conclusion:** Intra-articular ozone injections have a rapid effect and provide better short-term results for KOA. In later periods, it has a similar effect to corticosteroids.

**Keywords:** Intraarticular injection, knee, ozone, osteoarthritis, pain

Please cite this article as "Ayyildiz A, Ciftci Inceoglu A, Dogu B, Kuran B. Comparison of the Therapeutic Effects of Intra-Articular Injection of Ozone and Corticosteroid in Knee Osteoarthritis. Med Bull Sisli Etfal Hosp 2026;60(1):30-35".

Osteoarthritis (OA) is the most prevalent form of arthritis globally. It is characterized by the gradual loss of articular cartilage, subchondral bone sclerosis, osteophyte formation, and changes in the synovial fluid and joint membranes.<sup>[1]</sup> OA affects over 240 million adults worldwide.<sup>[2]</sup> Frequently observed in the geriatric population, this disease reduces quality of life and causes serious

functional losses.<sup>[3]</sup> The knee joint is one of the most frequently affected joints.<sup>[4]</sup> While 30% of patients over the age of 45 have radiological findings of knee osteoarthritis (KOA), half of them experience symptomatic knee pain.<sup>[2,5]</sup> The most prevalent symptoms of knee osteoarthritis (KOA) are pain, stiffness, swelling, and joint crepitation, which can lead to joint deformities over time. The disease

**Address for correspondence:** Aylin Ayyildiz, MD. Department of Physical Medicine and Rehabilitation, Çam and Sakura City Hospital, İstanbul, Türkiye

**Phone:** +90 538 503 36 93 **E-mail:** aylin.mrt93@gmail.com

**Submitted Date:** June 5, 2025 **Revised Date:** December 19, 2025 **Accepted Date:** December 26, 2025 **Available Online Date:** March 23, 2026

©Copyright 2025 by The Medical Bulletin of Sisli Etfal Hospital - Available online at [www.sislietfaltip.org](http://www.sislietfaltip.org)

**OPEN ACCESS** This is an open access article under the CC BY-NC license (<http://creativecommons.org/licenses/by-nc/4.0/>).



is diagnosed clinically and supported by radiological evidence.<sup>[6]</sup>

Total knee arthroplasty is currently the only proven and definitive treatment for KOA.<sup>[7]</sup> However, there is no definitive treatment method for patients who do not meet the surgical indications. Nonetheless, medical professionals may attempt to improve the pain and functional status of patients through changes in daily living activities, physical therapy, and intra-articular injections.<sup>[8]</sup> In KOA, intra-articular injections are increasingly popular due to their effectiveness in reducing pain and minimal adverse effects.<sup>[9]</sup> Intra-articular injections commonly used include corticosteroids, hyaluronic acid, ozone, platelet-rich plasma (PRP), dextrose, and prolotherapy.<sup>[7,10,11]</sup>

Ozone gas is a structurally unstable molecule that contains three oxygen atoms. When mixed with oxygen, it can increase tissue oxygenation and reduce the production of proinflammatory cytokines by reactive oxygen and lipid oxidation products. This can lead to an increase in the number of chondrocytes and fibroblasts, as well as the release of antioxidant enzymes and immunosuppressive cytokines synthesized in the lesion area. Additionally, ozone has an analgesic effect by blocking phosphodiesterase A2.<sup>[12-15]</sup> However, there is still a lack of consensus on the effectiveness of ozone therapy in treating KOA. Chronic oxidative stress is considered a cornerstone in the pathogenesis of KOA. It is argued that ozone can be used as an important treatment modality by reducing the damage caused by oxidative stress.<sup>[15]</sup> Unlike corticosteroid injections, which carry risks such as chondrotoxicity and septic arthritis with repeated use, ozone injections may offer a safer alternative for intra-articular therapy in KOA. Although intra-articular corticosteroid injection has been proven to be effective in treating KOA with anti-inflammatory mechanisms, the risks of joint cartilage damage and septic arthritis caused by frequent injections always cast doubt on the injection's effectiveness.<sup>[16,17]</sup> Ozone therapy has emerged as a promising minimally invasive option due to its proposed anti-inflammatory, analgesic, and antioxidant effects, as well as its favorable safety profile. While there have been several studies that have evaluated ozone therapy or corticosteroid injections separately, direct randomized comparisons between these two agents using standardized dosing and follow-up protocols remain limited.

Intra-articular steroid injections are among the proven and effective injection treatments outlined in the guidelines created by the European Society for Clinical and Economic Aspects of Osteoporosis, Osteoarthritis and Musculoskeletal Diseases (ESCEO) and the Osteoarthritis Research Society International (OARSI) for the treatment of KOA.<sup>[18]</sup> In our

study, we sought to compare this treatment with a strong level of evidence with intra-articular ozone injection treatment in terms of pain and functionality in the treatment of KOA. This study uniquely investigates both the rapid early effects and 12-week outcomes of ozone therapy compared to corticosteroids, employing a repeated three-dose ozone protocol to address gaps in the current literature.

The primary objective of this randomized clinical trial was to compare the short-term and mid-term effects of intra-articular ozone injections and corticosteroid injections on pain and functional outcomes in patients with knee osteoarthritis. The hypothesis was that intra-articular ozone therapy would provide a more rapid improvement in pain and functional scores in the early period, while demonstrating comparable efficacy to corticosteroids at 12-week follow-up.

## Methods

This prospective randomized clinical study was conducted between September 2020 and March 2022 at the Department of Physical Medicine and Rehabilitation (PMR) of our hospital. Ethics committee approval was authorized from the Clinical Research Ethics Committee of University of Health Sciences, Şişli Hamidiye Etfal Training and Research Hospital (Date: 03.09.2019, Decision no: 1326), (ClinicalTrials.gov identifier: NCT06328270). All patients were informed and their written informed consent was obtained. The study was conducted in accordance with the Declaration of Helsinki. This trial was organized by the criteria of the CONSORT guideline.

Ninety patients were screened for inclusion in the PMR outpatient clinic based on inclusion and exclusion criteria. To be included, patients had to be between 40-85 years old, have experienced knee pain and/or limited joint range of motion for at least 6 months, and have a diagnosis of KOA supported by radiographic imaging. This study excluded patients who had undergone knee joint surgery, had a history of previous intra-articular injections in the last 1 year, had a history of physical therapy in the last 6 months, had any rheumatological disease or malignancy, were pregnant, or had pain radiating to the knee and leg. Before the randomization, patients with glucose-6-phosphate dehydrogenase deficiency, for whom ozone therapy was contraindicated, and similarly, patients with contraindications to corticosteroids, such as uncontrolled diabetes mellitus or infection, were excluded from the study.

The study included 60 patients who were randomly assigned to receive either intra-articular ozone injection (n=30) or intra-articular corticosteroid injection (n=30). Block randomization was used as the randomization method. The corticosteroid injection was administered as a

single dose, while the ozone injection was given in three sessions with a one-week interval between each session. In their study, Babaei-Ghazani et al.<sup>[17]</sup> administered ozone injection to the knee joint in a volume of 10 ml and a dosage of 15 µg/mL. In response, our team implemented an adjusted protocol. The ozone treatment group received 0.45 mg ozone by way of 10 mL ozonated oxygen at 15 µg/mL at three weekly sessions. The control group received a single injection of 1 mL betamethasone. The ozone was obtained using the Turkozone Blue S Medical Ozone Device from Türkiye. The intra-articular injection procedure was performed with the patient in a sitting position and the knee flexed to 90 degrees using an inferolateral approach. Both groups participated in the exercise program for KOA.

The patients underwent evaluation by a physician who was blinded to the intervention before treatment, 4 weeks after treatment, and 12 weeks after the final dose. Treatment efficacy was evaluated using the Visual Pain Score (VAS) and the Western Ontario and McMaster Universities Arthritis Index (WOMAC).

### Statistical Analysis

The descriptive statistics of the data included mean, standard deviation, median, lowest, highest, and ratio values.

The distribution of variables was measured using the Kolmogorov-Smirnov test. For the analysis of quantitative independent data, the Mann-Whitney U test was used. The Wilcoxon test was used for the analysis of dependent quantitative data. The Chi-square test was used to analyze qualitative independent data, and the Fisher's exact test was used when the conditions for the Chi-square test were not met. The values of  $p < 0.05$  were considered significant. At 95% power and 0.05 alpha significance level, the total sample size was determined as 54. The data were analyzed using SPSS software version 26 (Chicago, IL: SPSS Inc.).

### Results

Our study included sixty patients, and Figure 1 shows the corresponding flow chart. No adverse effects were observed during the injection or follow-up period.

When examining demographic characteristics, the study found that the mean age of the patients was  $62.2 \pm 10$  years, and 90% of them were female. Based on the Kellgren-Lawrence Staging, 45% of the patients were in stage 2, 46.7% were in stage 3, and 8.3% were in stage 4. As demonstrated in Table 1, there was no significant difference between groups in demographic data ( $p > 0.05$ ).

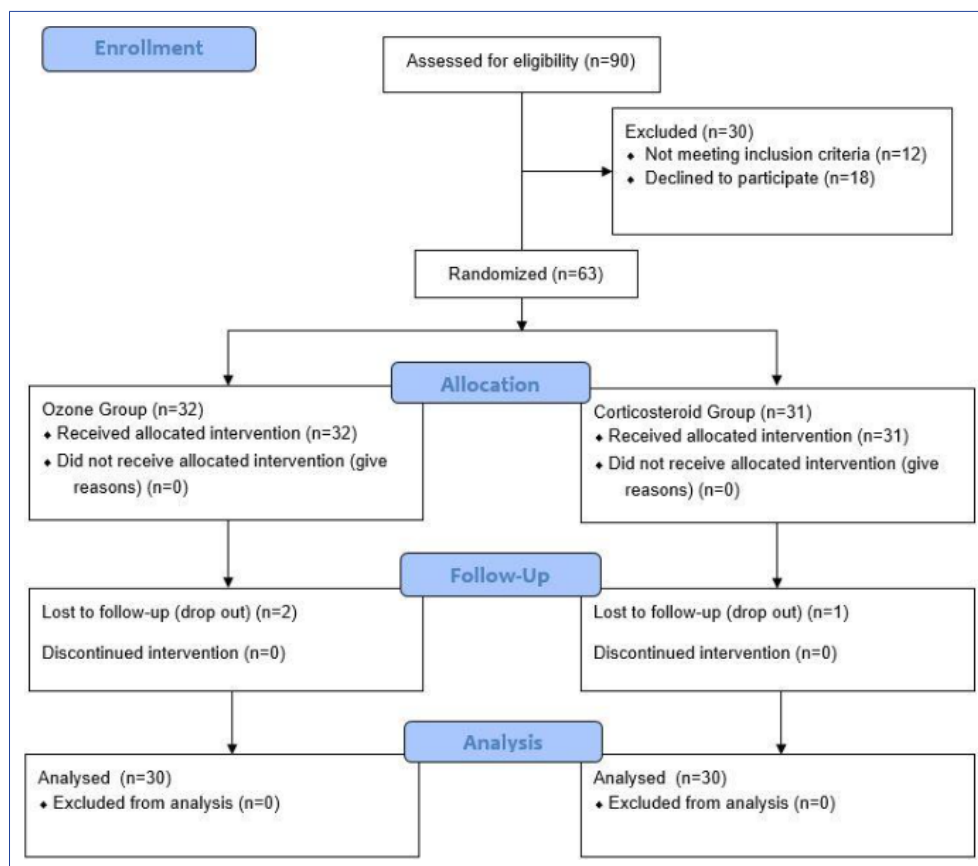


Figure 1. Flow chart of study.

**Table 1.** Comparisons of two groups

	Ozone group Mean±SD / n-%	Corticosteroid group Mean±SD / n-%	p
Age	60.2±7.9	64.1±11.6	0.139 <sup>m</sup>
Sex			
Male	5±16.7	1±3.3	0.085 <sup>x2</sup>
Female	25±83.3	29±96.7	
Kellgren lawrence staging			
II	15±50.0	12±40.0	0.065 <sup>x2</sup>
III	15±50.0	13±43.3	
IV	0±0.0	5±16.7	
VAS			
Pre-treatment	8.0±0.7	7.9±1.0	0.975 <sup>m</sup>
Post-treatment 4 weeks	5.7±1.7	6.6±1.2	<b>0.026<sup>m</sup></b>
Post-treatment 12 weeks	6.4±1.8	6.4±1.2	0.575 <sup>m</sup>
PreT/PoT 4w change	-2.3±1.5	-1.3±1.3	<b>0.014<sup>m</sup></b>
Intra-group change p	<b>&lt;0.001<sup>w</sup></b>	<b>&lt;0.001<sup>w</sup></b>	
PreT/PoT 12w change	-1.5±1.7	-1.5±1.3	0.784 <sup>m</sup>
Intra-group change p	<b>&lt;0.001<sup>w</sup></b>	<b>&lt;0.001<sup>w</sup></b>	
WOMAC			
Pre-treatment	51.0±17.2	44.7±8.7	0.287 <sup>m</sup>
Post-treatment 4 weeks	36.5±16.6	39.6±10.7	0.332 <sup>m</sup>
Post-treatment 12weeks	41.3±17.0	37.9±8.4	0.515 <sup>m</sup>
PreT/PoT 4w change	-14.5±14.8	-5.1±6.8	<b>0.001<sup>m</sup></b>
Intra-group change p	<b>&lt;0.001<sup>w</sup></b>	<b>&lt;0.001<sup>w</sup></b>	
PreT/PoT 12w change	-9.8±12.7	-6.8±3.4	0.302 <sup>m</sup>
Intra-group change p	<b>&lt;0.001<sup>w</sup></b>	<b>&lt;0.001<sup>w</sup></b>	

<sup>m</sup>Mann-whitney u test; <sup>w</sup>Wilcoxon test; <sup>x2</sup> Ki-kare test; VAS: Visual Analog scale; WOMAC: Western Ontario and McMaster Universities Arthritis index.

Significant decreases in VAS and WOMAC scores were observed in both groups at the 4<sup>th</sup> and 12<sup>th</sup> weeks when compared to pre-treatment ( $p < 0.05$ ). In particular, during the fourth week, the ozone group exhibited a significant improvement in VAS and WOMAC scores ( $p < 0.05$ ).

## Discussion

The trial's most significant finding is that intra-articular ozone-oxygen injection has a rapid effect in the early stages, which is not observed with corticosteroid injection. In the long term, it is advisable to choose the fast-acting option since both injection types have similar efficacy levels. This rapid early response highlights the potential of ozone therapy as a first-line option for immediate symptom relief in KOA.

Duymus et al.<sup>[19]</sup> compared the effects of ozone injection, hyaluronic acid injection, and PRP injection in KOA. It is important to note that this study only compared the short-term effects of these treatments and further research is needed to determine their long-term efficacy. Their study showed that ozone injection had a rapid effect in the early period but lost its effect in the 6<sup>th</sup> month. It is believed that the short-term effect of ozone is responsible for its strong anti-inflammatory properties, reducing pain by decreasing edema and swelling in the joint. However, since ozone does not remain in the joint for a long time, its effects are thought to be short-lived. Therefore, it is recommended that it be supplemented with more frequent or alternative injections.<sup>[19,20]</sup> To address this limitation, our study implemented a repeated-dose protocol, with ozone administered three times at weekly intervals, which demonstrated sustained efficacy over 12 weeks. Similarly, Mishra et al.<sup>[21]</sup> found that the ozone effect lasted for six months. They have also demonstrated that ozone is superior to corticosteroids, particularly due to its potent anti-inflammatory effect and lack of side effects.

In a study conducted by Babaei-Ghazani et al.,<sup>[17]</sup> ozone and corticosteroid injections were compared in KOA. Both groups showed a significant improvement in VAS and WOMAC values in the early period, with the ozone group showing continued improvement compared to the corticosteroid group in the WOMAC evaluation at the 3<sup>rd</sup> month. However, the authors argue that steroid injection is more effective and fast-acting in the 1<sup>st</sup>-week controls. While there is no definitive consensus on the frequency of ozone injection in the literature, it is believed that a single dose application is not sufficient. Our study expands on this by directly comparing both treatments using standardized protocols and investigating their effects over a 12-week period, filling a critical gap in the literature.

There is no consensus in the literature regarding the dose of ozone application, just as with the frequency of injection. Raeissadat et al.<sup>[7]</sup> and Duymus et al.<sup>[19]</sup> used a dose of 30 µg/ml in KOA, while Babaei-Ghazani et al.<sup>[17]</sup> used a dose of 15 µg/mL. Oliviero et al.<sup>[22]</sup> emphasized in their review article that 20 µg/mL was frequently preferred in the studies

evaluated. Therefore, further studies are necessary to determine the optimal ozone application dose and duration of follow-up. Our findings provide a preliminary framework for refining these protocols. Raeissadat et al.<sup>[23]</sup> administered PRP, plasma rich in growth factor, hyaluronic acid, and ozone injections to patients with KOA and followed up for 12 months. The study demonstrated that ozone injection was beneficial in the short term, but its long-term efficacy remains uncertain.

A 2019 meta-analysis recommended ozone application for short-term anti-inflammatory effects in KOA. The therapeutic effect of ozone is similar to corticosteroid injection, but repeated intra-articular steroid administration is chondrotoxic.<sup>[24]</sup> To prevent cartilage damage and reduce other corticosteroid side effects, we recommend ozone injection for the early anti-inflammatory effect in KOA when conducting a cost-benefit analysis.

The strength of this study lies in its pragmatic design and direct comparison with a guideline-recommended reference treatment. The findings of this study demonstrate a faster early clinical response with ozone therapy and comparable mid-term outcomes. This provides practical evidence to the limited body of randomized data evaluating ozone as an alternative intra-articular treatment in knee osteoarthritis. This may be of relevance for patients requiring rapid symptom relief, or for whom concerns regarding repeated use of corticosteroids limit their utilization. This study has several limitations. Firstly, the group size is small, and the patient follow-up period is short-term (3 months). Another limitation is the lack of a control group with a sham. On the other hand, there are several studies in the literature comparing these two types of injection. For the future, trials with larger numbers and longer follow-up periods are needed.

## Conclusion

Intra-articular ozone injection has a rapid effect and better short-term results in KOA; in later periods, it has a similar effect to corticosteroids.

### Disclosures

**Ethics Committee Approval:** This study was approved by the Clinical Research Ethics Committee University of Health Sciences, Şişli Hamidiye Etfal Training and Research Hospital (Date: 03.09.2019, Decision no: 1326). Clinical trials number: NCT06328270.

**Informed Consent:** Written informed consent was obtained.

**Conflict of Interest:** None declared.

**Financial Disclosure:** The author declared that this study has received no financial support.

**Use of AI for Writing Assistance:** None declared.

**Authorship Contributions:** Concept – AA, BK; Design – BK, BD;

Supervision – BK; Materials – AA; Data collection or processing – AA; Analysis and/or interpretation – AA; Literature search – AA, SÇ; Writing – AA; Critical review – AA, BK.

**Peer-review:** Externally peer-reviewed.

## References

1. Yunus MHM, Nordin A, Kamal H. Pathophysiological perspective of osteoarthritis. *Medicina (Kaunas)* 2020;56:614. [\[Crossref\]](#)
2. Katz JN, Arant KR, Loeser RF. Diagnosis and treatment of hip and knee osteoarthritis: a review. *JAMA* 2021;325:568–78. [\[Crossref\]](#)
3. Neogi T, Zhang Y. Epidemiology of osteoarthritis. *Rheum Dis Clin North Am* 2013;39:1–19. [\[Crossref\]](#)
4. Busija L, Bridgett L, Williams SR, Osborne RH, Buchbinder R, March L, et al. Osteoarthritis. *Best Pract Res Clin Rheumatol* 2010;24:757–68. [\[Crossref\]](#)
5. Jordan JM, Helmick CG, Renner JB, Luta G, Dragomir AD, Woodard J, et al. Prevalence of knee symptoms and radiographic and symptomatic knee osteoarthritis in African Americans and Caucasians: the Johnston County Osteoarthritis Project. *J Rheumatol* 2007;34:172–80.
6. Jang S, Lee K, Ju JH. Recent updates of diagnosis, pathophysiology, and treatment on osteoarthritis of the knee. *Int J Mol Sci* 2021;22:2619. [\[Crossref\]](#)
7. Raeissadat SA, Rayegani SM, Forogh B, Hassan Abadi P, Moridnia M, Rahimi Dehgolan S. Intra-articular ozone or hyaluronic acid injection: Which one is superior in patients with knee osteoarthritis? A 6-month randomized clinical trial. *J Pain Res* 2018;11:111–7. [\[Crossref\]](#)
8. DeRogatis M, Anis HK, Sodhi N, Ehiorobo JO, Chughtai M, Bhav A, et al. Non-operative treatment options for knee osteoarthritis. *Ann Transl Med* 2019;7(Suppl 7):S245. [\[Crossref\]](#)
9. Javadi Hedayatabad J, Kachooei AR, Taher Chaharjouy N, Vaziri N, Mehrad-Majd H, Emadzadeh M, et al. The effect of ozone (o3) versus hyaluronic acid on pain and function in patients with knee osteoarthritis: a systematic review and meta-analysis. *Arch Bone Jt Surg* 2020;8:343–54.
10. Ding JB, Hu K. Injectable therapies for knee osteoarthritis. *Rheumatologia* 2021;59:330–9. [\[Crossref\]](#)
11. Anil U, Markus DH, Hurley ET, Manjunath AK, Alaia MJ, Campbell KA, et al. The efficacy of intra-articular injections in the treatment of knee osteoarthritis: A network meta-analysis of randomized controlled trials. *Knee* 2021;32:173–82. [\[Crossref\]](#)
12. Sagai M, Bocci V. Mechanisms of action involved in ozone therapy: is healing induced via a mild oxidative stress? *Med Gas Res* 2011;1:29. [\[Crossref\]](#)
13. Bocci VA. Scientific and medical aspects of ozone therapy. *State of the art. Arch Med Res* 2006;37:425–35. [\[Crossref\]](#)
14. Sconza C, Respizzi S, Virelli L, Vandenbulcke F, Iacono F, Kon E, et al. Oxygen-ozone therapy for the treatment of knee osteoarthritis: a systematic review of randomized controlled trials. *Arthroscopy* 2020;36:277–86. [\[Crossref\]](#)

15. Borrelli E, Alexandre A, Iliakis E, Alexandre A, Bocci V. Disc herniation and knee arthritis as chronic oxidative stress diseases: The therapeutic role of oxygen ozone therapy. *J Arthritis* 2015;4:1–6. [\[Crossref\]](#)
16. Matzkin EG, Curry EJ, Kong Q, Rogers MJ, Henry M, Smith EL. Efficacy and treatment response of intra-articular corticosteroid injections in patients with symptomatic knee osteoarthritis. *J Am Acad Orthop Surg* 2017;25:703–14. [\[Crossref\]](#)
17. Babaei-Ghazani A, Najarzadeh S, Mansoori K, Forogh B, Madani SP, Ebadi S, et al. The effects of ultrasound-guided corticosteroid injection compared to oxygen-ozone (O<sub>2</sub>-O<sub>3</sub>) injection in patients with knee osteoarthritis: a randomized controlled trial. *Clin Rheumatol* 2018;37:2517–27. [\[Crossref\]](#)
18. Arden NK, Perry TA, Bannuru RR, Bruyère O, Cooper C, Haugen IK, et al. Non-surgical management of knee osteoarthritis: comparison of ESCEO and OARSI 2019 guidelines. *Nat Rev Rheumatol* 2021;17:59–66. [\[Crossref\]](#)
19. Duymus TM, Mutlu S, Dernek B, Komur B, Aydogmus S, Kesiktas FN. Choice of intra-articular injection in treatment of knee osteoarthritis: platelet-rich plasma, hyaluronic acid or ozone options. *Knee Surg Sports Traumatol Arthrosc* 2017;25:485–92. [\[Crossref\]](#)
20. Cardoso CC, Carvalho JC, Ovando EC, Macedo SB, Dall'Aglio R, Ferreira LR. Action of ozonized water in preclinical inflammatory models. *Pharmacol Res* 2000;42:51–4. [\[Crossref\]](#)
21. Mishra SK, Pramanik R, Das P, Das PP, Palit AK, Roy J, et al. Role of intra-articular ozone in osteo-arthritis of knee for functional and symptomatic improvement. *Ind J Phys Med Rehabil* 2011;22:65–69.
22. Oliviero A, Giordano L, Maffulli N. The temporal effect of intra-articular ozone injections on pain in knee osteoarthritis. *Br Med Bull* 2019;132:33–44. [\[Crossref\]](#)
23. Raeissadat SA, Ghazi Hosseini P, Bahrami MH, Salman Roghani R, Fathi M, Gharooee Ahangar A, et al. The comparison effects of intra-articular injection of Platelet Rich Plasma (PRP), Plasma Rich in Growth Factor (PRGF), Hyaluronic Acid (HA), and ozone in knee osteoarthritis; a one year randomized clinical trial. *BMC Musculoskelet Disord* 2021;22:134. [\[Crossref\]](#)
24. Arias-Vázquez PI, Tovilla-Zárate CA, Hernández-Díaz Y, González-Castro TB, Juárez-Rojop IE, López-Narváez ML, et al. Short-term therapeutic effects of ozone in the management of pain in knee osteoarthritis: a meta-analysis. *PM R* 2019;11:879–87. [\[Crossref\]](#)