



# Evaluation of the effect of different minimally invasive access cavity preparations on discoloration in maxillary and mandibular first molars: An in vitro spectrophotometric study

Ayşe Gamze Özyaman,<sup>1</sup> Melis Oya Ateş<sup>2</sup>

<sup>1</sup>Private Practise, Istanbul, Türkiye.

<sup>2</sup>Department of Endodontics, Bolu Abant İzzet Baysal University Faculty of Dentistry, Bolu, Türkiye

**Purpose:** This study evaluated the effect of different minimally invasive access cavity designs on the discoloration of maxillary and mandibular first molars using spectrophotometric analysis.

**Methods:** Eighty first molars (maxillary n=40; mandibular n=40), free of caries and restorations, were randomly allocated—stratified by arch—to eight groups (n=10 per group) according to access cavity design (traditional, conservative, ultraconservative, truss; four groups per arch). Using a dental operating microscope, access cavities were prepared, working lengths determined, and canals instrumented with Reciproc R25. Irrigation activation was performed with a #20 Irrisafe ultrasonic tip, followed by single-cone obturation with R25 gutta-percha and A2 composite restorations. Color measurements were recorded using a Vita Easyshade V spectrophotometer at baseline, immediately after treatment, and at 1, 7, 30, and 60 d. L\*a\*b values were converted to Commission International de l'Eclairage (CIELAB)  $\Delta E$  values. Data were analyzed with appropriate statistical tests.

**Results:** Clinically perceptible discoloration ( $\Delta E \geq 3.3$ ) was observed in all groups at various time points. In the maxillary molars, traditional access cavities showed significantly greater discoloration at one month compared at baseline ( $p < 0.05$ ). No significant differences were found among the other groups ( $p > 0.05$ ).

**Conclusion:** Traditional access cavities in maxillary molars produced greater discoloration than minimally invasive access cavities. Minimally invasive access cavity designs may help maintain tooth color by preserving dentin and reducing restorative material volume.

**Keywords:** Conservative access cavity; minimally invasive endodontics; tooth discoloration; traditional access cavity; truss access cavity; ultraconservative access cavity.

## Introduction

Endodontic treatment includes pulpotomy, pulp capping, pulpectomy, and both surgical and nonsurgical treatments of the root canals and surrounding periapical tissues (1).

One of the most crucial steps for successful endodontic treatment is preparation of the access cavity (2). Access cavity preparation is one of the most challenging aspects of endodontic treatment; however, it is key to its success (3).

**Cite this article as:** Ozyaman AG, Ateş MO. Evaluation of the effect of different minimally invasive access cavity preparations on discoloration in maxillary and mandibular first molars: An in vitro spectrophotometric study. Turk Endod J 2026;11:102-111.

**Correspondence:** Melis Oya Ates. Department of Endodontics, Faculty of Dentistry, Bolu Abant İzzet Baysal University, Bolu, Türkiye  
Tel: +90 507 – 053 55 60 e-mail: melisoayaates@hotmail.com

**Submitted:** September 16, 2025 **Revised:** November 11, 2025 **Accepted:** November 11, 2025 **Published:** April 27, 2026

This work is licensed under a Creative Commons Attribution-NonCommercial 4.0 International Licence



To date, the general outlines of endodontic access cavities have been standardized for each tooth type, with their design following the principles of “proper form” and “extension for prevention” (2). The main aim of this endodontic approach is to ensure complete removal of the pulp chamber roof for adequate access and visibility of the root canal orifices, while minimizing the risk of procedural errors. However, little emphasis has been placed on preserving the tooth structure (4,5).

Minimally invasive endodontics focuses on disease management while preserving as much natural tooth structure as possible. With advances in magnification and imaging technologies, such conservative approaches have become more widely applied in endodontic practice, particularly through access cavity designs that preserve pericervical dentin.

Pericervical dentin functions as a stress distributor and preserving it can potentially increase fracture resistance (5). This approach was suggested by Clark and Khademi (5) based on the hypothesis that the removal of pericervical dentin, oblique ridges, and thinning of marginal ridges could potentially increase the likelihood of tooth fracture (6).

Reducing the size of the access cavity can jeopardize the subsequent stages of canal treatment by preventing and/or complicating procedures such as cleaning, shaping, and filling canal orifices. Furthermore, it can increase the potential for iatrogenic complications such as missed canals, canal transportation, and/or instrument breakage (7-10). Residual pulp chamber roof structures may support microbial growth, which could contribute to tooth discoloration, although evidence remains limited. A small access cavity may limit the effective removal of pulp remnants, dentin debris, filling materials, and other restorative materials, potentially compromising canal disinfection and contributing to discoloration (11).

The proposal for different designs of access cavity preparation is a relatively new trend in endodontics, and specific terminology has not yet been established (12). Silva et al. (9) proposed a new classification of access cavity geometries to provide common language and self-explanatory abbreviations: Traditional, conservative, ultraconservative, truss, caries-oriented, and restoration-oriented access cavities.

Although the effectiveness of different access cavity designs in terms of remaining coronal tooth tissue removal, fracture resistance, and pulp tissue removal has been extensively studied (13,14), there is limited research evaluating their effect on discoloration, particularly in the anterior teeth (15). To date, no study has been found in the comprehensive literature review that investigates the impact of

access cavity design on the discoloration of molar teeth.

Preserving intact tooth structure during endodontic access not only supports the mechanical integrity of the tooth but also plays an important role in maintaining esthetic outcomes. Minimally invasive access designs may help prevent post-treatment discoloration, which is of clinical significance particularly in visible posterior teeth. The aim of this study was to evaluate the effect of different access cavity designs on the discoloration of molar teeth during endodontic treatment. The null hypothesis of the study was that there would be no difference in the effect of different access cavity preparations on tooth discoloration.

## Materials and Methods

### Sample Selection and Preparation

The manuscript of this *in vitro* laboratory study was prepared in accordance with the Preferred Reporting Items for Laboratory Studies in Endodontology (PRILE) 2021 guidelines (16).

The study protocol was approved by the Bolu Abant İzzet Baysal University Ethics Committee. (No: 2023/109; Date: 25/04/2023). This study was conducted in accordance with the principles of the Declaration of Helsinki. Informed consent was obtained from all participants and/or their legal guardians. The sample size was calculated using the G\* Power software 3.1.9.7 (Heinrich Heine University, Düsseldorf, Germany) by taking a study with a similar methodological design as a reference (17). With 95% confidence ( $1-\alpha$ ), 95% test power ( $1-\beta$ ), and  $f=0.625$  effect size, the total number of cases included in the study was 64, with eight cases in each group. However, in this study, the total number of cases was 80, with 10 cases in each group.

Eighty intact human first molars (maxillary  $n=40$ ; mandibular  $n=40$ ), extracted within 30 days prior to testing for prosthodontic or periodontal indications, were included. The teeth were selected after rigorous visual inspection under a dental operating microscope (DOM) (Prima DNT, California, ABD) and radiographic examination. Exclusion criteria were the presence of caries, coronal staining, observable structural defects, restoration, calcification, resorption, or root canal treatment. After extraction, the teeth were stored in 1% chloramine-T solution (Merck, Darmstadt, Germany) until further use. Each tooth was stored individually in capped transparent plastic containers in phosphate-buffered saline (Lp Italiana Spa, Milan, Italy) at  $37 \pm 1^\circ\text{C}$  and 100% humidity throughout the study.

### Preparation for Color Measurement

The position of the spectrophotometer tip in contact with

the tooth was standardized using a silicone-based impression material (Zetaplus, Zhermack, Badia Polesine, Italy).

Subsequently, the impression was filled with chemically cured acrylic resin to create a model. This model was placed on the cemento-enamel junction (CEJ) of the vestibular surface of the teeth, and a fixed frame was prepared around it using a flowable composite (Filtek Z250, 3M ESPE, Germany). Thus, a standardized area for placing the spectrophotometer tip was created on the buccal surfaces of all the teeth (18).

**Randomization was stratified by arch:** The 40 maxillary and 40 mandibular molars were independently randomized into the experimental groups using a computer-generated sequence (random.org).

### Access Cavity Preparation

The teeth were divided into 8 groups for access cavity preparation. All cavities were prepared under a dental operating microscope (DOM; Prima DNT, California, USA).

**Group A (Traditional Access Cavities in Maxillary First Molars):** For maxillary first molars, traditional access cavities were initiated using a diamond round bur (Meisinger, Neuss, Germany) under water cooling at a perpendicular angle from the deepest point of the occlusal surface. The cavity boundaries included the oblique ridge and the mesiobuccal, distobuccal, and mesiopalatal cusps. As previously described (13), removal of the pulp chamber roof facilitated direct access to the coronal third of the root canals. After completely removing the pulp chamber roof, the cavity walls were made parallel using a diamond fissure bur (Meisinger, Neuss, Germany) to ensure straight-line access to all canal orifices.

**Group B (Conservative Access Cavities in Maxillary First Molars):** Conservative access cavities in the maxillary first molars were initiated with a diamond round bur under water cooling at a perpendicular angle from the deepest point of the occlusal surface. Only minimal enlargement of the canal orifices was performed to preserve the oblique ridge, pericervical dentin, and the remaining roof structures of the pulp chamber, ensuring the maintenance of coronal integrity (19). The buccal wall of the cavity was parallel to the buccal wall of the tooth using a diamond fissure bur.

**Group C (Ultraconservative Access Cavities in Maxillary First Molars):** Ultraconservative access cavities were initiated from the central fossa or the deepest point of the occlusal surface with a diamond round bur under water cooling. The cavity was minimally enlarged to allow visualization of all canal orifices and was extended apically. The pulp chamber roof and pericervical dentin were preserved to a significant extent (20). The cavity walls were beveled

at 45-degree angle using a diamond fissure bur to create divergence.

**Group D (Truss Access Cavities in Maxillary First Molars):** Truss access cavities in maxillary first molars involved the preparation of two separate cavities for canal access using a diamond round bur under water cooling. One cavity included the mesiobuccal and distobuccal canals, whereas the other included the palatal canal. The oblique ridge was preserved. The roof of the pulp chamber was maintained between the prepared cavities (21). Buccal and palatal cavity were prepared with approximate dimensions of 2.5 mm in width, 4.0 mm in depth, and 4.0 mm in length, leaving about 2 mm of intervening dentin intact between them, adapted from the methodology described by Abou-Elnaga et al. (22). The first cavity was widened mesiodistally on the buccal side of the central fossa, whereas the second cavity was round and located buccally to the palatal canal. The cavity walls were diverged using a diamond fissure bur.

**Group E (Traditional Access Cavities in Mandibular First Molars):** Following the traditional access cavity protocol for the maxillary molar, the only alteration involved extending the cavity margins to encompass half of each cusp.

**Group F (Conservative Access Cavities in Mandibular First Molars):** Following the approach used for a conservative access cavity in the maxillary molar, enlargement was restricted to that required for identifying the canal orifices while conserving the pericervical dentin and a portion of the pulp chamber roof.

**Group G (Ultraconservative Access Cavities in Mandibular First Molars):** In mandibular molars, the ultraconservative access cavity was initiated slightly mesial to the central fossa to enhance visibility of the mesiolingual canal. A diamond round bur was used under water cooling at a shallow mesial angle directed toward the mesial root. The cavity was minimally extended to expose all canal orifices, while preserving the pericervical dentin and the roof of the pulp chamber. The cavity walls were refined and beveled at approximately 45° using a fine diamond fissure bur to create divergence and facilitate access.

**Group H (Truss Access Cavities in Mandibular First Molars):** Truss access cavities in mandibular first molars involved the preparation of two separate cavities for canal access using a diamond bur under water cooling. One cavity included the mesiobuccal and mesiolingual canals, whereas the other included the distal canals. The central fossa was preserved. The first cavity was widened buccolingually on the mesial side of the central fossa, whereas the second cavity was oval and buccolingually widened on the distal side of the central fossa. Each proximal box in the mandibular truss access cavity was prepared according to the method-

ology described by Abou-Elnaga et al. (22). The cavity walls were diverged using a diamond fissure bur.

### Shaping, Filling, and Restoration of Teeth

After the preparation of the access cavities, the apical patency was confirmed using a #10 K-file (VDW, Munich, Germany), and the working length was determined to be 1 mm short of the apex. Rotary instruments were operated in reciprocation mode using an endomotor (X-Smart Plus, Dentsply Sirona, Ballaigues, Switzerland) in accordance with the manufacturer's instructions. Canals were prepared using Reciproc R25 (VDW, Munich, Germany). As an irrigation solution, 2.5 ml 5% NaOCl (Coltene, Whaledent, Switzerland) was used as the irrigation solution. For the final irrigation, 3 ml 5% NaOCl, 3 ml 17% EDTA (Cerkamed, Poland), and 3 ml 5% NaOCl were sequentially applied. The final irrigation activation procedure was performed using a #20 Irrisafe ultrasonic tip (Acteon, Marignac, France) and Satelec P5 Newtron XS ultrasonic device (Satelec Acteon, Merignac, France). A total of 3 ml of each solution was activated for 1 min in each canal, with 1 ml of the solution activated for 20 s, repeated three times. After canal shaping, all canals were dried using R25 paper points (VDW, Munich, Germany). The canals were filled using the single-cone technique with R25 gutta-percha (VDW, Munich, Germany), compatible with a rotary instrument. AH Plus (Dentsply Maillefer, Ballaigues, Switzerland), mixed according to the manufacturer's instructions, was used as a root canal sealer according to the manufacturer's instructions. Residual filling materials were eliminated with heated condensers and an endodontic explorer. Pulp chamber walls were scrubbed using cotton pellets moistened with 70% alcohol under microscopic magnification. The composite restoration (Filtek Z250) was applied in increments of up to 2 mm, with each being cured for 20 s. A2 shade composite was selected because it represents a clinically common intermediate color that offers a neutral reference for assessing discoloration. A uniform 2-mm thickness was maintained to standardize light transmission and optical properties across all samples.

### Color Measurement

A spectrophotometer (Vita Easyshade V, Zahnfabrik H. Rauter GmbH & Co. KG, Germany) was used for color measurements. The spectrophotometer was calibrated before each measurement in the same location under standardized white light conditions. Measurements were repeated thrice on the buccal surface of each tooth, and the mean value was recorded. All measurements were conducted by the same operator at all time intervals for all teeth. The  $L^*$  values represent lightness, ranging from 0 (black) to 100 (white), whereas the  $a^*$  values indicate the chromatic

axis extending from green (−80) to red (+80), and the  $b^*$  values denote the axis ranging from blue (−80) to yellow (+80), collectively characterizing color variations (23).

In this study, color measurements were taken six times for each sample to investigate the effect of different minimally invasive access cavities on the color change.

- T0: Before any procedure
- T1: Immediately after the procedure
- T2: 1 day after the procedure
- T3: 1 week after the procedure
- T4: 1 month after the procedure
- T5: 2 months after the procedure

Color changes were recorded using the CIELAB color space. The color difference for each sample was calculated using the following formula:

$$\Delta E^* = ((\Delta L^*)^2 + (\Delta a^*)^2 + (\Delta b^*)^2)^{1/2}$$

$$\Delta L^* = L1^* - L0^*; \Delta a^* = a1^* - a0^*; \Delta b^* = b1^* - b0^*$$

### Statistical Analysis

All data were analyzed using the R statistical software (version 4.4.1). The normality of the distribution was evaluated using the Shapiro-Wilk test. For pairwise comparisons of normally distributed data, an independent two-sample t-test was used, whereas the Mann-Whitney U test was applied for non-normally distributed data. For comparisons of three or more groups, one-way ANOVA was used for normally distributed data, followed by Tamhane's T2 test for multiple comparisons. The Kruskal-Wallis test was used for non-normally distributed data, followed by Dunn's test for multiple comparisons. Within-group comparisons over three or more time points were analyzed using repeated-measures ANOVA for normally distributed data, followed by the Bonferroni test for multiple comparisons. Friedman's test was used for non-normally distributed data, followed by Dunn's test for multiple comparisons. The results are presented as mean  $\pm$  standard deviation or median (minimum – maximum) for quantitative data. The statistical significance level was determined as 5%.

### Results

In the tested groups, clinically perceptible color changes ( $\Delta E \geq 3.3$ ) were observed at various time intervals compared to baseline. When  $\Delta E$  changes over time for the groups of maxillary molars were compared, a statistically significant difference was found in the median  $\Delta E$  values T0-T4 time interval between the groups ( $p < 0.05$ ) (Fig. 1). The  $\Delta E$  value was significantly higher in the traditional access cavity than in the conservative and truss access cavities, while the remaining groups exhibited comparable outcomes (Table 1).

**Table 1.** Comparison of ΔE values among groups A, B, C, and D

	Group A	Group B	Group C	Group D	Test Statistic	p
ΔE T0-T1	3.009 (1.616-8.271)	3.5 (1.896-8.919)	3.811 (2.481-7.607)	4.477 (1.671-5.997)	1.803	0.614*
ΔE T0-T2	4.877±1.94	3.368±1.355	4.91±2.239	3.243±2.066	2.267	0.097 <sup>†</sup>
ΔE T0-T3	4.722±2.453	3.652±2.846	3.64±1.791	4.515±2.062	0.598	0.621 <sup>†</sup>
ΔE T0-T4	5.86±2.506 <sup>a</sup>	2.656±1.178 <sup>b</sup>	4.717±2.991 <sup>ab</sup>	2.74±0.975 <sup>b</sup>	5.542	0.007 <sup>†</sup>
ΔE T0-T5	4.487 (0.983-6.786)	2.356 (0.77-4.878)	3.396 (1.429-11.077)	2.901 (1.126-7.11)	3.683	0.298*

\*Kruskall Wallis H Test; <sup>†</sup>One Way Anova; <sup>(a-b)</sup> Groups with the same superscript letter are not significantly different; Data are presented as mean ± standard deviation or median (minimum–maximum).

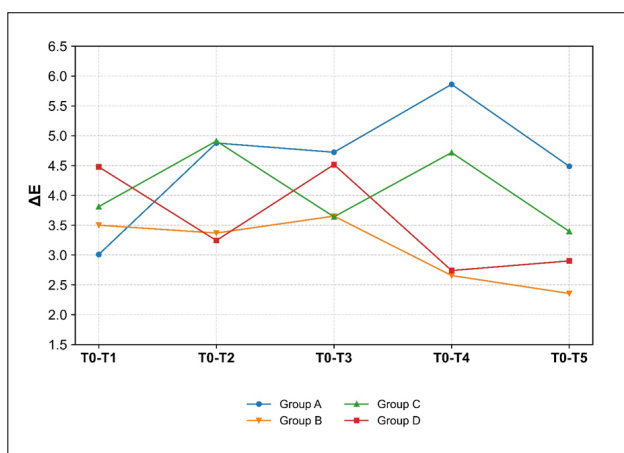
**Table 2.** Comparison of ΔE values among groups E, F, G, and H

	Group E	Group F	Group G	Group H	Test Statistic	p
ΔE T0-T1	2.634 (1.426-11.889)	3.789 (1.609-5.889)	4.593 (2.701-6.558)	2.807 (0.435-4.999)	4.930	0.177*
ΔE T0-T2	3.342 (0.953-6.751)	3.283 (1.632-4.272)	4.167 (1.339-10.105)	3.349 (0.779-8.782)	0.581	0.901*
ΔE T0-T3	3.666±1.792	4.894±3.532	4.949±2.693	4.199±1.983	0.639	0.599 <sup>‡</sup>
ΔE T0-T4	4.274 (1.54-6.788)	3.867 (1.448-10.485)	2.02 (0.291-7.979)	2.874 (1.04-4.554)	7.384	0.061*
ΔE T0-T5	3.959 (1.835-8.085)	2.52 (0.732-5.892)	3.407 (1.11-8.377)	3.004 (0.836-8.413)	7.965	0.047*

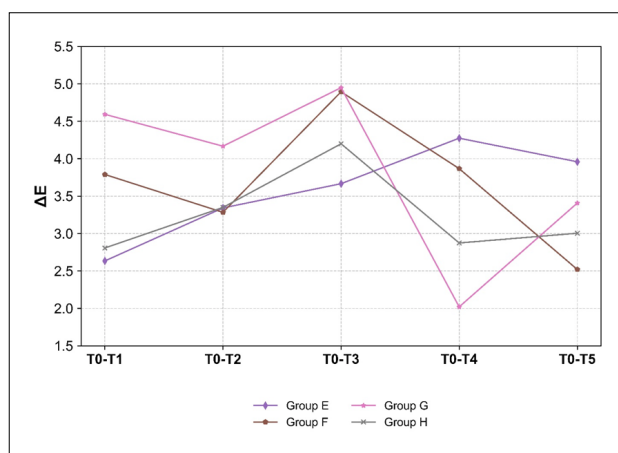
\*Kruskall Wallis H Test; <sup>‡</sup>One Way Anova; Data are presented as mean ± standard deviation or median (minimum–maximum).

For mandibular molars, a statistically significant difference in ΔE values was noted in the T0-T5 time interval (p=0.047) (Table 2); however, no significant differences were observed in multiple comparisons. (p>0.05) (Fig. 2). When the ΔE changes over time were compared between traditional access cavities in the maxillary and mandibular molars, the differences among groups were not statistically meaningful (p>0.05) (Fig. 3A). Likewise, the conservative, ultraconservative, and truss access cavity groups in maxillary and mandibular molars exhibited comparable ΔE variations over time (p>0.05) (Fig. 3B, 3C, 3D).

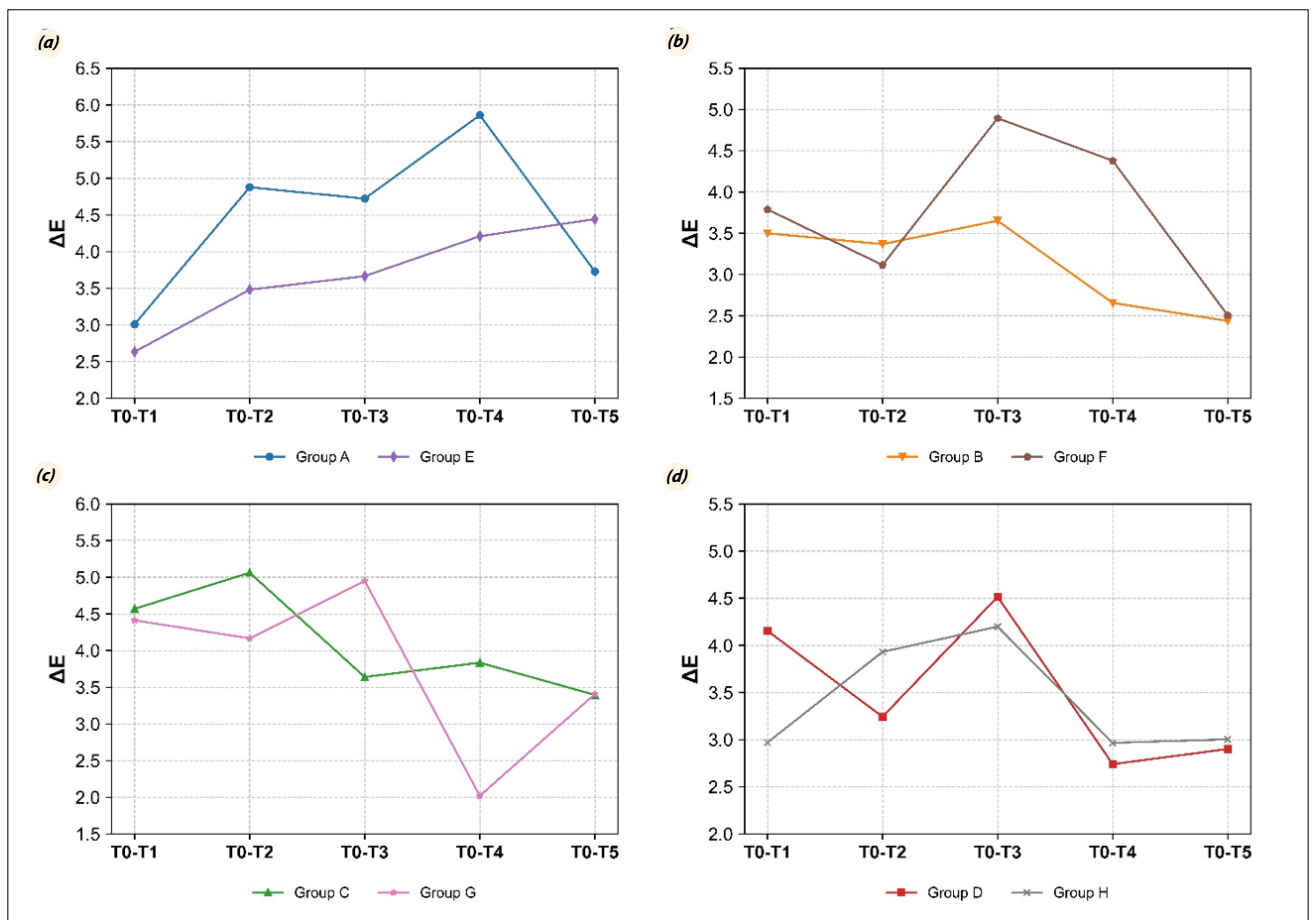
In the present study, within-group comparisons of ΔE values over time revealed statistically significant differences between traditional access cavities in maxillary molars (p=0.026) and ultraconservative access cavities in mandibular molars (p=0.049). Nevertheless, no significant variations were observed in multiple comparisons, indicating overall comparable results across all groups. No statistically significant differences were found in the within-group comparisons of the ΔE values over time (p>0.05) (Table 3).



**Fig. 1.** Comparison of ΔE values according to groups A, B, C and D.



**Fig. 2.** Comparison of ΔE values according to groups E, F, G and H.



**Fig. 3.** (a) Comparative analysis of ΔE values between group A and group E. (b) Comparative analysis of ΔE values between group B and group F. (c) Comparative analysis of ΔE values between group C and group G. (d) Comparative analysis of ΔE values between group D and group H.

**Table 3.** Comparison of ΔE values over time within each group

	Group T0-T1	T0-T2	T0-T3	T0-T4	T0-T5	Test Statistic	p
Group A	3.897±2.014	4.877±1.94	4.722±2.453	5.86±2.506	3.729±1.902	3.147	0.026*
Group B	3.5 (1.896-8.919)	3.331 (1.404-5.482)	3.439 (0.552-10.145)	3.002 (0.834-4.238)	2.356 (0.77-4.878)	7.760	0.101 <sup>†</sup>
Group C	3.811 (2.481-7.607)	5.062 (1.146-9.086)	3.56 (1.527-6.502)	3.835 (1.471-10.222)	3.396 (1.429-11.077)	2.560	0.634 <sup>†</sup>
Group D	4.154±1.382	3.243±2.066	4.515±2.062	2.74±0.975	3.423±2.125	1.757	0.159*
Group E	2.634 (1.426-11.889)	3.342 (0.953-6.751)	3.489 (1.271-6.904)	4.274 (1.54-6.788)	3.959 (1.835-8.085)	1.040	0.904 <sup>†</sup>
Group F	3.677±1.415	3.115±0.856	4.894±3.532	4.379±2.723	2.505±1.625	1.705	0.170*
Group G	4.593 (2.701-6.558)	4.167 (1.339-10.105)	4.368 (1.765-8.976)	2.02 (0.291-7.979)	3.407 (1.11-8.377)	9.520	0.049 <sup>†</sup>
Group H	2.807 (0.435-4.999)	3.349 (0.779-8.782)	3.622 (0.852-7.855)	2.874 (1.04-4.554)	3.004 (0.836-8.413)	3.280	0.512 <sup>†</sup>

\*Repeated Measures Anova; <sup>†</sup>Friedman Test; Data are presented as mean ± standard deviation or median (minimum–maximum).

## Discussion

Minimally invasive access cavities are used in dentistry to treat carious or damaged areas with minimal loss of tooth structure. The impact of such cavity preparations on tooth color is critically important for preserving esthetic outcomes and maintaining the natural appearance of teeth

(12). A comprehensive review of the literature revealed no studies evaluating the effect of access cavities on discoloration.

Known causes of discoloration in endodontically treated teeth include endodontic medicaments and various filling materials (24). Root canal materials containing bismuth

trioxide as a filler and radiopacifier may cause discoloration (25). AH Plus, which includes zirconium oxide as a radiopacifier, demonstrates good color stability (25). Therefore, AH Plus was used as the canal filling material in this study to minimize the risk of color change. Studies have shown that the cervical margin of the root filling is associated with coronal discoloration in endodontically treated teeth (26). An insufficient endodontic procedure to define the cervical margin of the endodontic material may allow direct contact with the axial dentin walls, and interactions between chemical components over time may lead to tooth darkening (27). In such cases, trimming the filling material below the CEJ is recommended (26).

Research indicates that color changes are more prominent in the cervical one-third of the crown compared to the occlusal one-third (28,29). In the present study, a composite frame was constructed on the buccal surface of the teeth, including the cervical third, to position the spectrophotometer head in the same location at each time interval. To ensure standardization of repeated measurements, all assessments were recorded under the same conditions, with the same lighting, and by the same operator. The device was calibrated according to the manufacturer's instructions prior to each measurement. Each measurement was repeated thrice, and the average of these values was calculated.

Clinically perceptible color changes ( $\Delta E \geq 3.3$ ) compared with baseline were observed at various time intervals in the tested groups in the present study. Among the different access cavities created in maxillary molars, greater discoloration was observed 1 month after the preparation of the traditional access cavity than at baseline. According to literature, the intrinsic color of a tooth is related to the light scattering and absorption properties of enamel and dentin (30). Tooth color is determined by a combination of the optical properties of the tooth. Vaarkamp et al. (31) supported the idea that hydroxyapatite crystals significantly contribute to light scattering in enamel, whereas dentinal tubules are the dominant cause in dentin. An *in vitro* study concluded that enamel removal does not significantly alter tooth color, confirming that dentin primarily determines tooth color, with enamel playing a minor role (30). Traditional access cavity designs involve wide cavity preparations that may result in excessive dentin loss to fully remove the pulp chamber roof and provide straight-line access to root canals (32). Ribeiro et al. (33) proposed minimally invasive cavity designs aiming to preserve as much pericervical dentin as possible. Research has shown that preserving pericervical dentin is crucial for maintaining the normal function, esthetics, and durability of treated teeth (34).

Traditional access cavities remove more cervical dentin than minimally invasive cavities, leading to greater loss of translucency and increased reflection of the restorative material. Isufi et al. (35) reported that the amount of coronal tooth structure removed was less than 15% in conservative access cavities, whereas it exceeded 15% in traditional access cavities. Lin et al. (36) observed the greatest loss of tooth structure in the cervical region of traditional access cavities when evaluating material loss in maxillary molars. Additionally, the thickness of the restorative material used to replace the lost dentin is greater in traditional cavities than in minimally invasive cavities. A study evaluating the translucency parameters of light-cured composite resins at different thicknesses revealed that increased thickness reduces translucency (34), making the material appear opaque (37). Consistent with our findings, Kamishima et al. (38) demonstrated that an increased composite thickness resulted in higher  $L^*$  and  $b^*$  values.

Minimally invasive cavity designs help maintain the natural color of the tooth by preserving enamel and dentin. Structural preservation supports the tooth's original translucency and enhances color harmony between the restorative material and the surrounding tissue (39). Restorations performed using minimally invasive methods affect the long-term color stability of the composite filling materials. Such restorations cause less damage to the esthetic structure of the tooth, prevent discoloration over time, and maintain the natural appearance of the restoration for an extended period (39,40). Traditional access cavities, compared with minimally invasive cavities, result in the removal of more dentin, making the cavities wider. A literature review reported that polymerization shrinkage can lead to discoloration issues due to failure at the composite-tooth interface (41). One possible reason for the greater discoloration in conventional access cavities compared to minimally invasive cavities may be the higher polymerization shrinkage.

In the present study, clinically perceptible color changes ( $\Delta E \geq 3.3$ ) were observed in mandibular molars over time compared with baseline. A significant difference was detected at the T0–T5 interval; however, multiple comparison tests revealed no statistically meaningful variation among the groups. Although statistically significant  $\Delta E$  differences were observed in mandibular molars, most values were near the clinically perceptible threshold ( $\Delta E = 3.3$ ), suggesting limited clinical relevance of these color changes. Although some groups exhibited an increase in  $\Delta E$  values over time, these differences did not reach statistical significance, possibly due to high variability among samples and the proximity of most values to the perceptibility threshold. Biologically, these findings indi-

cate that the observed color changes, while measurable, are unlikely to be clinically perceptible or meaningful. The absence of statistically significant differences in mandibular molars may be attributed to anatomical and optical factors. Compared with maxillary molars, mandibular molars have thinner enamel and higher dentin dominance, which may reduce light transmission and mask subtle internal color changes (42).

Pereira et al. (43) reported that the presence of voids at the tooth-restoration interface could compromise the marginal integrity of coronal restorations, leading to microleakage and ultimately causing discoloration over time. Silva et al. (44) investigated the effect of different access cavity designs on the formation of voids between the composite and the tooth structure in extracted teeth. Their study concluded that minimally invasive access cavity design was associated with a significantly greater number of voids within the restorations. This information may explain the observation of clinically perceptible color changes at various time intervals compared with the initial level in the minimally invasive cavity groups.

When the traditional, conservative, ultraconservative, and truss access cavities were compared between the mandibular and maxillary molar teeth regarding their discoloration potentials, no statistically significant difference was found. Previous studies have shown that residual root canal filling material left within the cavity after endodontic treatment and gutta-percha that does not extend below the CEJ can lead to discoloration. Depending on the chemical composition of the root canal sealers, coronal discoloration can be mild, moderate, or severe (45). Rover et al. (14) compared different cavity designs in mandibular teeth and examined the remnants of the root canal filling material left in the pulp chamber after cleaning. Similar to our findings, their study found no significant difference among different access cavities in the percentage of root canal filling remnants in the pulp chamber. Barbosa et al. (13) also examined the effects of different access cavity designs on the remnants of root canal fillings in the pulp chamber. Consistent with our results, their study demonstrated statistically comparable outcomes between the conservative and traditional access cavity designs.

In the present study, within-group comparisons of time-dependent  $\Delta E$  values revealed significant differences for the traditional access cavity in maxillary molars and the ultraconservative access cavity in mandibular molars. However, multiple comparison tests showed that these differences were not statistically meaningful. A review of the literature revealed that incomplete removal of pulp tissue leads to the breakdown of residual pulp tissue, allowing blood components to penetrate the dentinal tubules. This

demonstrates that residual pulp tissue in the pulp chamber after treatment is one of the primary causes of discoloration (45).

Neelakantan et al. (21) compared the effects of different minimally invasive access cavity designs on pulp chamber cleanliness with traditional access cavities in mandibular molars. Similar to our findings, their study reported no significant differences among traditional, conservative, and truss access cavity types regarding the remaining pulp tissue. Studies have indicated that long-term discoloration can occur owing to the inability to detect extra canals because of inadequate cavity preparation (46). Among the three studies evaluating the effect of access cavity design on detecting extra canals, two studies focused on detecting MB2 canals in maxillary first molars (14,47), and one examined the detection of the middle mesial canal in mandibular first molars (19). Without magnification or the use of DOM, more MB2 (second mesiobuccal) canals were detected in traditional access cavities than in conservative ones (8). The present study was conducted using DOM, and similar to the findings of our study, studies using DOM reported no significant difference between these two cavity designs in detecting MB2 or middle mesial canals (46). Furthermore, Mendes et al. (19) reported in a recent study that the type of access cavity did not affect the detection of the middle mesial canals in mandibular molars when performed by an experienced endodontist under DOM.

Despite the standardized conditions maintained in our study, the current *in vitro* study model has limitations in fully mimicking clinical scenarios. The lack of biological factors, such as natural tooth discoloration in human teeth, distance from the actual clinical environment, diet, oral hygiene, and saliva, limits its applicability. More randomized controlled clinical trials with longer durations are needed to evaluate the effects of access cavities on discoloration.

## Conclusion

Clinically perceptible color changes were detected in the tested groups at various time intervals compared with baseline. When different access cavities prepared in maxillary molar teeth were compared, more discoloration was observed in traditional access cavities. No significant differences in discoloration were observed among the other tested groups. Minimally invasive access cavity designs may help maintain tooth color by preserving dentin and reducing restorative material volume.

**Acknowledgments:** This article is derived from Ayşe Gamze Özyaman's specialty thesis in Endodontics (Bolu Abant İzzet Baysal University, 2024).

**Authorship Contributions:** Concept: A.G.O., M.O.A.; Design: A.G.O., M.O.A.; Supervision: M.O.A.; Fundings: A.G.O., M.O.A.; Materials: A.G.O., M.O.A.; Data: A.G.O.; Analysis: A.G.O., M.O.A.; Literature Search: A.G.O., M.O.A.; Writing: A.G.O., M.O.A.; Critical Revision: A.G.O., M.O.A.

**Use of AI for Writing Assistance:** Not declared

**Source of Funding:** This study was supported by Scientific and Technological Research Council of Turkey (TUBITAK) under the Grant Number 223S491.

**Conflict of Interest:** The authors did not report a conflict of interest.

**Ethical Approval:** The study protocol was approved by the Bolu Abant İzzet Baysal University Ethics Committee. (No: 2023/109; Date: 25/04/2023)

**Informed consent:** Written informed consent was obtained from patients who participated in this study.

## References

- Duncan HF, Kirkevang LL, Peters OA, et al. Treatment of pulpal and apical disease: The European Society of Endodontology (ESE) S3-level clinical practice guideline. *Int Endod J* 2023; 56(Suppl 3): 238–95. [CrossRef]
- Gutmann JL FB. Cohen's pathways of the pulp. 11th ed: Elsevier; 2016.
- Shabbir J, Zehra T, Najmi N, et al. Access cavity preparations: Classification and literature review of traditional and minimally invasive endodontic access cavity designs. *J Endod* 2021; 47(8): 1229–44. [CrossRef]
- Mandil OA, Ghoulah KT, Hazzam BM, et al. Modern versus traditional endodontic access cavity designs. *J Pharm Bioallied Sci* 2022; 14(Suppl 1): S24–S27. [CrossRef]
- Clark D, Khademi J. Modern molar endodontic access and directed dentin conservation. *Dent Clin North Am* 2010; 54(2): 249–73. [CrossRef]
- Saber SM, Hayaty DM, Nawar NN, et al. The effect of access cavity designs and sizes of root canal preparations on the biomechanical behavior of an endodontically treated mandibular first molar: A finite element analysis. *J Endod* 2020; 46(11): 1675–81. [CrossRef]
- Gluskin AH, Peters CI, Peters OA. Minimally invasive endodontics: Challenging prevailing paradigms. *Br Dent J* 2014; 216(6): 347–53. [CrossRef]
- Rover G, Belladonna FG, Bortoluzzi EA, et al. Influence of access cavity design on root canal detection, instrumentation efficacy, and fracture resistance assessed in maxillary molars. *J Endod* 2017; 43(10): 1657–62. [CrossRef]
- Silva E, Pinto KP, Ferreira CM, et al. Current status on minimal access cavity preparations: A critical analysis and a proposal for a universal nomenclature. *Int Endod J* 2020; 53(12): 1618–35. [CrossRef]
- Pedullà E, La Rosa GRM, Virgillito C, et al. Cyclic fatigue resistance of nickel-titanium rotary instruments according to the angle of file access and radius of root canal. *J Endod* 2020; 46(3): 431–6. [CrossRef]
- Silva E, De-Deus G, Souza EM, et al. Present status and future directions - Minimal endodontic access cavities. *Int Endod J* 2022; 55 Suppl 3: 531–87. [CrossRef]
- Chan MYC, Cheung V, Lee AHC, et al. A literature review of minimally invasive endodontic access cavities - past, present and future. *Eur Endod J* 2022; 7(1): 1–10. [CrossRef]
- Barbosa AFA, Silva E, Coelho BP, et al. The influence of endodontic access cavity design on the efficacy of canal instrumentation, microbial reduction, root canal filling and fracture resistance in mandibular molars. *Int Endod J* 2020; 53(12): 1666–79. [CrossRef]
- Rover G, de Lima CO, Belladonna FG, et al. Influence of minimally invasive endodontic access cavities on root canal shaping and filling ability, pulp chamber cleaning and fracture resistance of extracted human mandibular incisors. *Int Endod J* 2020; 53(11): 1530–9. [CrossRef]
- Silva-Sousa AC, Sousa-Neto MD, Camargo RV, et al. Influence of minimally invasive cavities on color stability of dental crowns with different filling sealers. *Braz Oral Res* 2024; 38: e104. [CrossRef]
- Nagendrababu V, Murray PE, Ordinola-Zapata R, et al. PRILE 2021 guidelines for reporting laboratory studies in Endodontology: A consensus-based development. *Int Endod J* 2021; 54(9): 1482–90. [CrossRef]
- Gürel MA, Kivanç BH, Ekici A, et al. Evaluation of crown discoloration induced by endodontic sealers and colour change ratio determination after bleaching. *Aust Endod J* 2016; 42(3): 119–23. [CrossRef]
- Ateş MO, Uğur Aydın Z. Evaluation of the effectiveness of different treatment approaches in preventing coronal discoloration caused by regenerative endodontic treatment. *Clin Oral Investig* 2023; 27(8): 4595–603. [CrossRef]
- Mendes EB, Soares AJ, Martins JNR, et al. Influence of access cavity design and use of operating microscope and ultrasonic troughing to detect middle mesial canals in extracted mandibular first molars. *Int Endod J* 2020; 53(10): 1430–7. [CrossRef]
- Lima CO, Barbosa AFA, Ferreira CM, et al. Influence of ultraconservative access cavities on instrumentation efficacy with XP-endo Shaper and Reciproc, filling ability and load capacity of mandibular molars subjected to thermomechanical cycling. *Int Endod J* 2021; 54(8): 1383–93. [CrossRef]
- Neelakantan P, Khan K, Hei Ng GP, et al. Does the orifice-directed dentin conservation access design debride pulp chamber and mesial root canal systems of mandibular molars similar to a traditional access design? *J Endod* 2018;

- 44(2): 274–9. [CrossRef]
22. Abou-Elnaga MY, Alkhawas MAM, Kim HC, et al. Effect of truss access and artificial truss restoration on the fracture resistance of endodontically treated mandibular first molars. *J Endod* 2019; 45(6): 813–7. [CrossRef]
23. Chen SJ, Karabucak B, Steffen JJ, et al. spectrophotometric analysis of coronal tooth discoloration induced by tricalcium silicate cements in the presence of blood. *J Endod* 2020; 46(12):1913–9. [CrossRef]
24. Kahler B. Present status and future directions - Managing discoloured teeth. *Int Endod J* 2022; 55 Suppl 4(Suppl 4): 922–50. [CrossRef]
25. Athanassiadis B, Abbott PV, Walsh LJ. A critical analysis of research methods and experimental models to study tooth discoloration from endodontic materials. *Int Endod J* 2022; 55 Suppl 2: 370–83. [CrossRef]
26. Lopes HP, Siqueira Junior JF. *Endodontia: Biologia e técnica*. Elsevier.
27. Allan NA, Walton RC, Schaeffer MA. Setting times for endodontic sealers under clinical usage and in vitro conditions. *J Endod* 2001; 27(6): 421–3. [CrossRef]
28. Parsons JR, Walton RE, Ricks-Williamson L. In vitro longitudinal assessment of coronal discoloration from endodontic sealers. *J Endod* 2001; 27(11): 699–702. [CrossRef]
29. Marciano MA, Costa RM, Camilleri J, et al. Assessment of color stability of white mineral trioxide aggregate angelus and bismuth oxide in contact with tooth structure. *J Endod* 2014; 40(8): 1235–40. [CrossRef]
30. He WH, Park CJ, Byun S, et al. Evaluating the relationship between tooth color and enamel thickness, using twin flash photography, cross-polarization photography, and spectrophotometer. *J Esthet Restor Dent* 2020; 32(1): 91–101. [CrossRef]
31. Vaarkamp J, ten Bosch JJ, Verdonchot EH. Propagation of light through human dental enamel and dentine. *Caries Res* 1995; 29(1): 8–13. [CrossRef]
32. Chandolu V, Mandava J, Borugadda R, et al. Influence of access cavity design on root canal instrumentation efficacy in molars - An in vitro study. *J Conserv Dent Endod* 2024; 27(3): 268–73. [CrossRef]
33. Ribeiro G, Martin V, Rodrigues C, et al. Comparative evaluation of the canal shaping ability, pericervical dentin preservation, and smear layer removal of trunatomy, waveone gold, and protaper ultimate-an ex vivo study in human teeth. *J Endod* 2023; 49(12): 1733–8. [CrossRef]
34. Yağcı Ö, Fidan M. Influence of thickness on the translucency parameter and whiteness index of single-shade resin composites. *Oper Dent* 2024; 49(2): 189–99. [CrossRef]
35. Isufi A, Plotino G, Grande NM, et al. Standardization of endodontic access cavities based on 3-dimensional quantitative analysis of dentin and enamel removed. *J Endod* 2020; 46(10): 1495–500. [CrossRef]
36. Lin CY, Lin D, He WH. Impacts of 3 different endodontic access cavity designs on dentin removal and point of entry in 3-dimensional digital models. *J Endod* 2020; 46(4): 524–30. [CrossRef]
37. Villarroel M, Fahl N, De Sousa AM, et al. Direct esthetic restorations based on translucency and opacity of composite resins. *J Esthet Restor Dent* 2011; 23(2): 73–87. [CrossRef]
38. Kamishima N, Ikeda T, Sano H. Color and translucency of resin composites for layering techniques. *Dent Mater J* 2005; 24(3): 428–32. [CrossRef]
39. Okuda WH. Minimally invasive dentistry and its impact on esthetic restorative dentistry. *Gen Dent* 2013; 61(5): 24–6.
40. Green D, Mackenzie L, Banerjee A. Minimally invasive long-term management of direct restorations: The ‘5 Rs’. *Dent Update* 2015; 42(5): 413–6. [CrossRef]
41. Soares CJ, Faria ESAL, Rodrigues MP, et al. Polymerization shrinkage stress of composite resins and resin cements - What do we need to know? *Braz Oral Res* 2017; 31(suppl 1): e62. [CrossRef]
42. Sarig R, Vardimon AD, Sussan C, et al. Pattern of maxillary and mandibular proximal enamel thickness at the contact area of the permanent dentition from first molar to first molar. *Am J Orthod Dentofacial Orthod* 2015; 147(4): 435–44. [CrossRef]
43. Pereira RA, Araujo PA, Castañeda-Espinosa JC, et al. Comparative analysis of the shrinkage stress of composite resins. *J Appl Oral Sci* 2008; 16(1): 30–4. [CrossRef]
44. Silva E, Oliveira VB, Silva AA, et al. Effect of access cavity design on gaps and void formation in resin composite restorations following root canal treatment on extracted teeth. *Int Endod J* 2020; 53(11): 1540–8. [CrossRef]
45. Sarshari MG, Shakeri K, Parhizkar A. Effect of vital pulp therapy biomaterials on tooth discoloration: A review of the literature. *Int J Biomater* 2025; 2025: 3080084. [CrossRef]
46. Ekici MA, Ekici A, Kaskatı T, et al. Tooth crown discoloration induced by endodontic sealers: A 3-year ex vivo evaluation. *Clin Oral Investig* 2019; 23(5): 2097–102. [CrossRef]
47. Saygili G, Uysal B, Omar B, et al. Evaluation of relationship between endodontic access cavity types and secondary mesiobuccal canal detection. *BMC Oral Health* 2018; 18(1): 121. [CrossRef]