

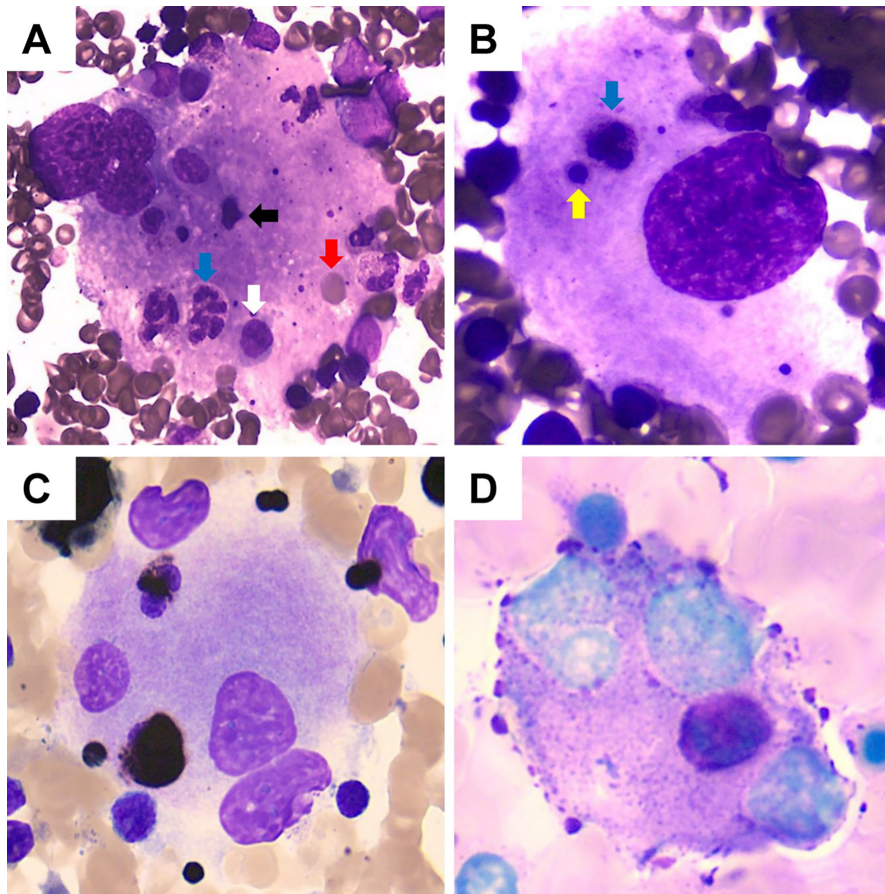
## Megakaryocytic Emperipolesis in Acute Myeloid Leukemia with Trisomy 8

### Trizomi 8 ile Seyreden Akut Miyeloid Lösemide Megakaryositik Emperipolezis

Shuling Wu<sup>1</sup>, Zhiqiang Zhong<sup>2</sup>

<sup>1</sup>The First Affiliated Hospital of Zhejiang Chinese Medical University (Zhejiang Provincial Hospital of Chinese Medicine), Department of Geriatrics, Hangzhou, P.R. China

<sup>2</sup>The First Affiliated Hospital of Zhejiang Chinese Medical University (Zhejiang Provincial Hospital of Chinese Medicine), Department of Clinical Laboratory, Hangzhou, P.R. China



**Figure 1.** A, B) Wright-Giemsa staining showing megakaryocytes with emperipolesis (blue arrow: granulocytes; white arrow: monocytes; black arrow: lymphocytes; yellow arrow: nucleated red cells; red arrow: erythrocytes). C) Peroxidase staining. D) Periodic acid-Schiff staining.



**Address for Correspondence/Yazışma Adresi:** Zhiqiang Zhong, M.D., The First Affiliated Hospital of Zhejiang Chinese Medical University (Zhejiang Provincial Hospital of Chinese Medicine), Department of Clinical Laboratory, Hangzhou, P.R. China  
E-mail: zzqjxcn@zcmu.edu.cn ORCID: orcid.org/0000-0003-3342-1234

Received/Geliş tarihi: May 22, 2025  
Accepted/Kabul tarihi: August 26, 2025  
Epub: August 27, 2025



© Copyright 2026 by Turkish Society of Hematology Turkish Journal of Hematology, Published by Galenos Publishing House. Licensed under a Creative Commons Attribution-NonCommercial (CC BY-NC-ND) 4.0 International License.

A 29-year-old man with myelodysplastic syndrome (MDS) diagnosed 3 years prior progressed to acute myeloid leukemia (AML) following only intermittent red blood cell transfusions and testosterone undecanoate as supportive therapy. Blood tests showed leukocyte count of  $3.3 \times 10^9/L$ , hemoglobin of 50 g/L, platelet count of  $3 \times 10^9/L$ , and elevated IL-12p70. Bone marrow aspirate showed hypercellularity with 37.0% of blasts positive for CD117, CD34, CD13, CD33, CD38, and HLA-DR, as well as eosinophilia and trilineage dysplasia. Megakaryocytes were normocellular but exhibited predominant granular megakaryocytes, lacking platelet-producing forms, with significant emperipolesis (non-destructive intracytoplasmic migration of diverse hematopoietic cells) in 80% of megakaryocytes as a finding absent in the initial MDS marrow smears (see Figure 1). Cytogenetics revealed 47,XY,+8[20] together with *GATA2* and *U2AF1* mutations and *CFHR3* partial deletion, consistent with the initial MDS diagnosis.

Trisomy 8 is one of the most frequent cytogenetic abnormalities in MDS/AML, often associated with dyshematopoiesis and enhanced inflammatory responses [1,2]. Increased levels of IL-12p70, a proinflammatory cytokine involved in immune regulation and hematopoietic cell interactions, may contribute to the observed emperipolesis. It is possible that trisomy 8-related genomic instability enhances inflammatory events, upregulating IL-12p70, which in turn enhances cell adhesion molecules on megakaryocytes, promoting emperipolesis by altering megakaryocyte-guest cell interactions. This hypothesis is consistent with reports linking proinflammatory cytokines to abnormal cell-in-cell phenomena in hematological malignancies [3,4,5,6].

**Keywords:** Megakaryocytes, Hematopoiesis, Physiology of hematopoiesis, Marrow, Acute leukemia, Neoplasia, Disorders of platelets, Platelets

**Anahtar Sözcükler:** Megakaryositler, Hematopoez, Hematopoezin fizyolojisi, Kemik iliği, Akut lösemi, Neoplazi, Trombosit bozuklukları, Trombositler

## Footnotes

## Ethics

**Informed Consent:** This submission does not include any patient-identifying information.

## Footnotes

## Authorship Contributions

Concept: Z.Z.; Design: Z.Z.; Data Collection or Processing: Z.Z.; Analysis or Interpretation: Z.Z., S.W.; Literature Search: S.W.; Writing: S.W.

**Conflict of Interest:** No conflict of interest was declared by the authors.

**Financial Disclosure:** The authors declared that this study received no financial support.

## References

1. Ichikawa K, Adachi S, Takase-Minegishi K, Nakayama Y, Nagasawa Y, Iizuka Y, Maeda A, Hirahara L, Soejima Y, Ohashi T, Kunitomo H, Horita N, Yoshimi R, Kirino Y, Nakajima H. Distinct features of trisomy 8-associated autoinflammatory disease from Behçet's disease: case series and systematic review. *Clin Exp Rheumatol*. 2025.
2. Wesner N, Drevon L, Guedon A, Fraison JB, Trad S, Kahn JE, Aouba A, Gillard J, Ponsoye M, Hanslik T, Gourguechon C, Liozon E, Laribi K, Rossignol J, Hermine O, Adès L, Carrat F, Fenaux P, Mekinian A, Fain O; GFM, MINHEMON (French Network of Dysimmune Disorders Associated to Hemopathies). Inflammatory disorders associated with trisomy 8-myelodysplastic syndromes: French retrospective case-control study. *Eur J Haematol*. 2019;102:63-69.
3. Rahmawati NY, Ahsan F, Santoso B, Mufid AF, Sa'adi A, Dwiningsih SR, Tunjungseto A, Widyanugraha MYA. IL-8 and IL-12p70 are associated with pelvic pain among infertile women with endometriosis. *Pain Med*. 2023;24:1262-1269.
4. Wang Q, Zhang W, Ding G, Sun L, Chen G, Cao X. Dendritic cells support hematopoiesis of bone marrow cells. *Transplantation*. 2001;72:891-899.
5. Beckman JD, DaSilva A, Aronovich E, Nguyen A, Nguyen J, Hargis G, Reynolds D, Vercellotti GM, Betts B, Wood DK. JAK-STAT inhibition reduces endothelial prothrombotic activation and leukocyte-endothelial proadhesive interactions. *J Thromb Haemost*. 2023;21:1366-1380.
6. Edelmann B, Gupta N, Schnoeder TM, Oelschlegel AM, Shahzad K, Goldschmidt J, Philippen L, Weinert S, Ghosh A, Saalfeld FC, Nimmagadda SC, Müller P, Braun-Dullaes R, Mohr J, Wolleschak D, Kliche S, Amthauer H, Heidel FH, Schraven B, Isermann B, Müller AJ, Fischer T. JAK2-V617F promotes venous thrombosis through  $\beta 1/\beta 2$  integrin activation. *J Clin Invest*. 2018;128:4359-4371.