LETTER TO THE EDITOR

Turk J Hematol 2026;43:188-189

# Myeloid Sarcoma in the Peritoneum with Leukemic Ascites Presenting with Acute Abdomen Findings: A Rare Case

## Akut Karın Bulguları ile Ortaya Çıkan Lösemik Asitle Birlikte Peritonda Miyeloid Sarkom: Nadir Bir Olgu

Rafiye Çiftçiler, Cem Selim

*Selçuk University Faculty of Medicine, Department of Hematology, Konya, Türkiye*

**To the Editor,**

The extramedullary leukemic tumors referred to as myeloid sarcomas can develop before or concurrently with myelodysplastic syndrome, other myeloproliferative neoplasms, or acute myeloid leukemia [1]. Myeloid sarcomas, or granulocytic sarcomas or chloromas, are extramedullary proliferations of blasts of one or more myeloid lineages that interfere with the tissue's normal architecture [2,3]. Although they can appear anywhere, myeloid sarcomas are most frequently seen in the skin, soft tissues, lymph nodes, and bones [3]. Even though they are extremely uncommon, peritoneal myeloid sarcoma and leukemic ascites should be looked for using immunophenotypic analysis and ascitic fluid flow cytometry when a patient with acute leukemia presents with newly diagnosed ascites [1,3]. This letter presents a rare myeloid sarcoma in the peritoneum with leukemic ascites. The patient consented to the publication of her case in a scholarly journal.

A 60-year-old woman presented to the emergency department with complaints of dyspnea, abdominal pain, and abdominal distension. Acute abdomen findings were suggested by early clinical, laboratory, and imaging tests in this uncommon case of myeloid sarcoma with ascites, abdominal pain, and dyspnea. There was a history of high-risk myelodysplastic syndrome with *TP53* mutation. The patient had undergone allogeneic hematopoietic stem cell transplantation from a full-match HLA-compatible donor 2 years ago. She was in remission and was followed intermittently in the hematology outpatient clinic for 2 years. She was admitted to the emergency department with complaints of the sudden onset of abdominal distension, abdominal pain, and shortness of breath. A complete blood count revealed hemoglobin of 11.1 g/dL, leukocyte count of $23x10^9$/L, and thrombocyte count of $108x10^9$/L. The patient was taken for emergency surgery by the general surgery department with a preliminary diagnosis of acute abdomen because the abdominal tomography performed for abdominal distension revealed widespread ascites and an appendix diameter of 9 mm. Abdominal and pelvic computed tomography showed widespread edema in the abdominal fat planes, widespread ascites in the abdomen, and non-contrast-enhancing thickening of the peritoneal surfaces, as shown in Figure 1. After surgery, the patient was transferred to the hematology service, and in a peripheral smear, approximately 90% myeloid blasts were observed. Flow cytometry revealed approximately 93.3% CD13+, CD33+, and CD34+ malignant cells. The patient's ascitic cytology sample, submitted during surgery, revealed findings consistent with myeloid sarcoma, characterized by myeloid blasts. Peritoneal myeloid sarcoma involvement with leukemic ascites was considered in line with the current findings. Because the clinical, laboratory, and radiological symptoms were first thought to have been caused by an infectious or other malignant illness, our case serves as an example of the diagnostic difficulties associated with myeloid sarcoma. Regardless of the alternative that was first assumed, the final diagnosis was made because our patient's ascites included cells with immature myeloid characteristics together with signs of disease recurrence in the bone marrow. Peritoneal myeloid sarcoma can be challenging to diagnose since it is frequently mistaken for spontaneous bacterial peritonitis and other types of peritoneal primary or secondary neoplasms, namely sarcomas, melanomas, or carcinoid tumors. It is necessary to rule out any other pertinent causes of ascites [3,4,5]. This letter aims to draw attention to a rare symptom of a common illness. A thorough work-up is crucial when myeloid sarcoma is suspected, particularly in individuals with a history of acute myeloid leukemia or myelodysplastic syndrome, because the disease can manifest in unusual places.

**Keywords:** Acute myeloid leukemia, Myeloid sarcoma, Leukemic ascites, Abdominal pain

**Anahtar Sözcükler:** Akut miyeloid lösemi, Miyeloid sarkom, Lösemik asit, Karın ağrısı

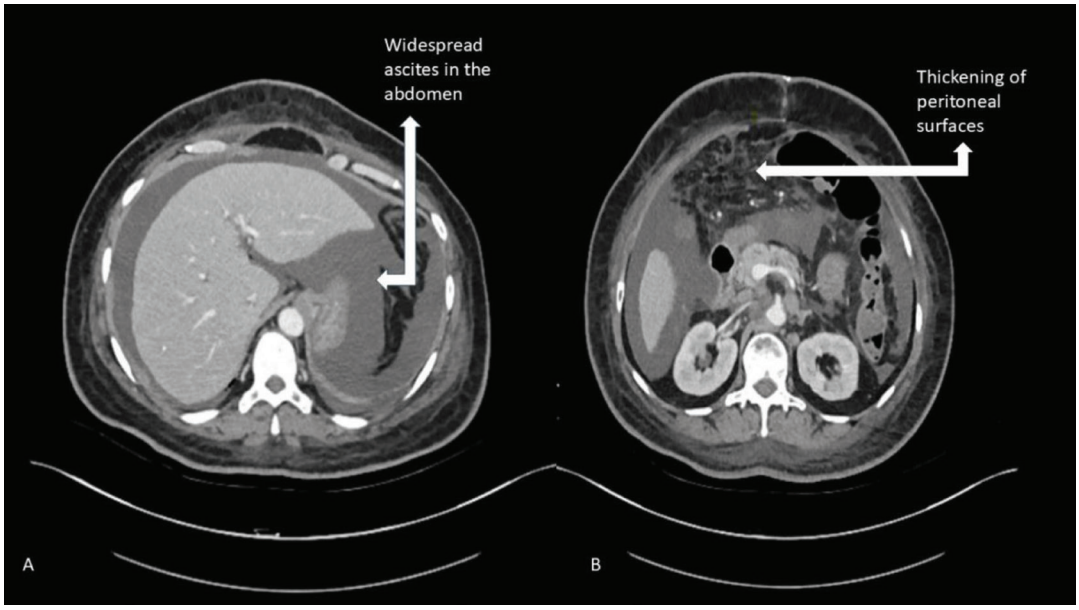


**Figure 1.** Computed tomography scan of the abdomen and pelvis: (A) widespread ascites in the abdomen, (B) thickening of peritoneal surfaces.

### Ethics

**Informed Consent:** Informed consent was obtained from the patient.

### Footnotes

### Authorship Contributions

Surgical and Medical Practices: R.Ç., C.S.; Concept: R.Ç.; Design: R.Ç., C.S.; Data Collection or Processing: R.Ç.; Analysis or Interpretation: R.Ç.; Literature Search: R.Ç.; Writing: R.Ç.

**Conflict of Interest:** No conflict of interest was declared by the authors.

**Financial Disclosure:** The authors declared that this study received no financial support.

## References

1. Landeiro L, Neto Gonçalves T, Proença M, Nunes A, Bayão Horta A. Leukaemic ascites and peritoneal myeloid sarcoma: rare but not impossible. Eur J Case Rep Intern Med. 2022;9:003184.
2. Arber DA, Orazi A, Hasserjian R, Thiele J, Borowitz MJ, Le Beau MM, Bloomfield CD, Cazzola M, Vardiman JW. The 2016 revision to the World Health Organization classification of myeloid neoplasms and acute leukemia. Blood. 2016;127:2391-2405.
3. Almond LM, Charalampakis M, Ford SJ, Gourevitch D, Desai A. Myeloid sarcoma: presentation, diagnosis, and treatment. Clin Lymphoma Myeloma Leuk. 2017;17:263-267.
4. Pantanowitz L, Steingart R, Miller KB, Kruskal JB, Pihan G. Leukemic ascites. Arch Pathol Lab Med. 2005;129:262-263.
5. Ravulapati S, Siegel C, Dara A, Lionberger JM. Myeloid sarcoma without circulating leukemia mimicking gastrointestinal malignancy and lymphoma. Hematol Rep. 2018;10:7040.

**Address for Correspondence/Yazışma Adresi:** Assoc. Prof. Rafiye Çiftçiler, M.D., Selçuk University Faculty of Medicine, Department of Hematology, Konya, Türkiye
**E-mail:** rafiyesarigul@gmail.com, rafiye.ciftciler@selcuk.edu.tr **ORCID:** orcid.org/0000-0001-5687-8531

**Received/Geliş tarihi:** May 20, 2025
**Accepted/Kabul tarihi:** June 24, 2025
**Epub:** June 24, 2025
**DOI:** 10.4274/tjh.galenos.2025.2025.0196

©Copyright 2026 by Turkish Society of Hematology Turkish Journal of Hematology, Published by Galenos Publishing House.
Licensed under a Creative Commons Attribution-NonCommercial (CC BY-NC-ND) 4.0 International License.