

Gallbladder Involvement in Aggressive Systemic Mastocytosis

Agresif Sistemik Mastositozda Safra Kesesi Tutulumu

Alper Koç¹, Hadice Akyol², Metban Mastanzade³, Sadık Keşmer⁴, Simge Erdem³

¹University of Health Sciences Türkiye, Elazığ Fethi Sekin City Hospital, Clinic of Hematology, Elazığ, Türkiye

²University of Health Sciences Türkiye, Elazığ Fethi Sekin City Hospital, Clinic of Pathology, Elazığ, Türkiye

³Istanbul University, İstanbul Faculty of Medicine, Department of Hematology, İstanbul, Türkiye

⁴University of Health Sciences Türkiye, Elazığ Fethi Sekin City Hospital, Clinic of Surgical Gastroenterology, Elazığ, Türkiye

To the Editor,

A 48-year-old male patient with a 10-month history of systemic mastocytosis, confirmed positive for the *KIT* D816V mutation, presented with right upper quadrant abdominal pain. Due to hepatic involvement and resulting portal hypertension, he was being monitored with a diagnosis of aggressive systemic mastocytosis (ASM) and had been receiving cladribine therapy for the past 3 months. His medical history included previous episodes of cholecystitis and biliary pancreatitis. Abdominal ultrasonography revealed thickening of the gallbladder wall, multiple millimetric gallstones, and biliary sludge within the lumen. The common bile duct was measured at 7.5 mm in diameter and the intrahepatic bile ducts were more prominent on the left side. Elective laparoscopic cholecystectomy was performed due to recurrent episodes of cholecystitis.

Intraoperative exploration revealed thickening of the gallbladder wall, cystic duct, and common bile duct. A relative narrowing of the cystic duct lumen was observed. The cystic duct could not be closed using endoclips or Hem-o-lok clips; therefore, it was successfully ligated with two interrupted sutures using polyglactin. The cholecystectomy specimen was opened along the lumen for examination. The lumen was

markedly narrowed and the mucosa appeared spongy, with a maximum wall thickness of 0.7 cm. Additionally, a 0.9-cm lymph node was identified near the neck region. Histopathological examination of the gallbladder revealed dense infiltration of atypical mast cells in the lamina propria and muscularis layers (Figure 1); these cells were diffusely positive for CD117. The lymph node also demonstrated mast cell infiltration (Figure 2).

In systemic mastocytosis, the primary pathological feature is the clonal infiltration of various internal organs, including the bone marrow, by mast cells. ASM is a rare but clinically severe subtype of systemic mastocytosis, defined by less than 20% mast cell infiltration in the bone marrow and the presence of at least one C finding. C findings indicate organ dysfunction caused by excessive mast cell infiltration. Mast cell accumulation can occur in the skin, liver, spleen, bone marrow, or gastrointestinal tract [1]. Despite the relative frequency of gastrointestinal involvement in systemic mastocytosis [2,3], gallbladder infiltration remains exceedingly rare, with only one reported case available in the literature to date [4]. With this report, we contribute this rare case of mast cell infiltration of the gallbladder observed in a patient diagnosed with ASM to the literature, along with its pathological images.

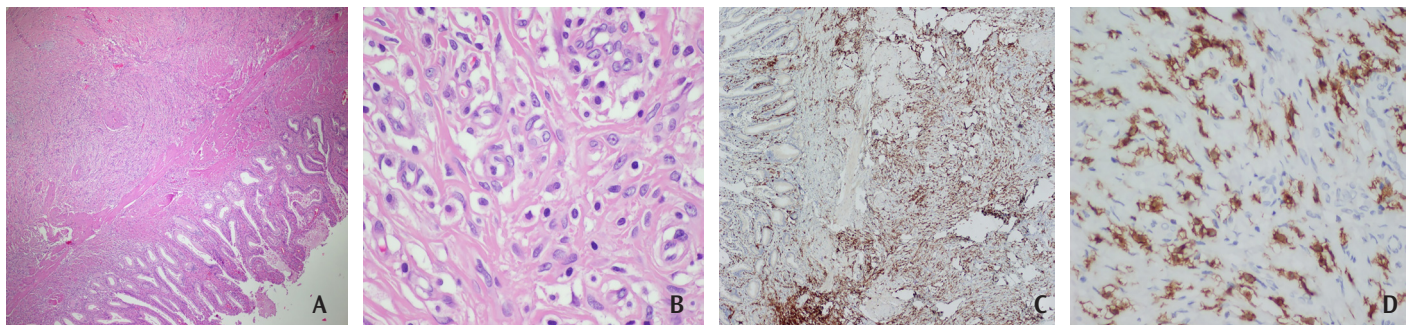


Figure 1. A, B) Hematoxylin and eosin staining, 40^x (A) and 600^x (B), revealing dense infiltration of atypical mast cells in the gallbladder wall. C, D) CD117 staining, 40^x (C) and 600^x (D), revealing diffuse membranous and cytoplasmic positivity in mast cells.

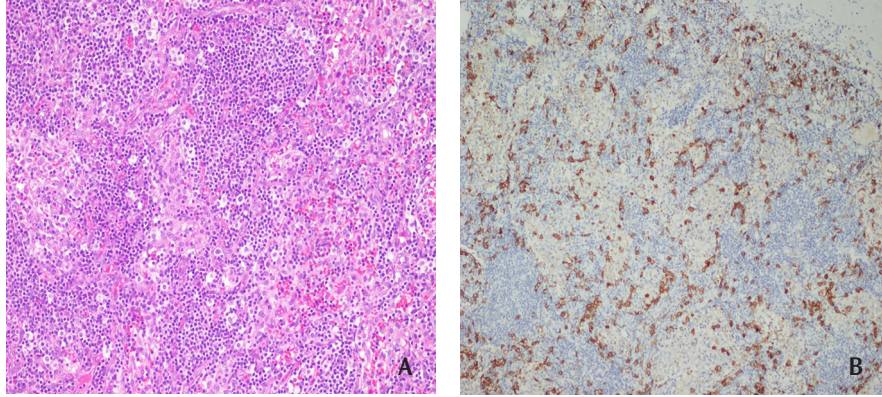


Figure 2. A) Lymph node infiltration by mast cells (hematoxylin and eosin staining, 200 \times). B) CD117 staining (200 \times) revealed positive mast cells.

Keywords: Mastocytosis, Gallbladder involvement, Cholecystitis

Anahtar Sözcükler: Mastositoz, Safra kesesi tutulumu, Kolesistit

Ethics

Informed Consent: Informed consent was obtained from the patient for this case report.

Footnotes

Authorship Contributions

Surgical and Medical Practices: A.K., H.A., M.M., S.K., S.E.;
Concept: A.K.; Design: A.K., H.A.; Data Collection and Processing:
A.K.; Literature Search: A.K., M.M.; Writing: A.K., M.M.

References

1. Valent P, Akin C, Metcalfe DD. Mastocytosis: 2016 updated WHO classification and novel emerging treatment concepts. *Blood*. 2017;129:1420-1427.
2. Zanelli M, Pizzi M, Sanguedolce F, Zizzo M, Palicelli A, Soriano A, Bisagni A, Martino G, Caprera C, Moretti M, Masia F, De Marco L, Froio E, Forni M, Bernardelli G, Alvarez de Celis MI, Giunta A, Merli F, Ascani S. Gastrointestinal manifestations in systemic mastocytosis: the need of a multidisciplinary approach. *Cancers (Basel)*. 2021;13:3316.
3. Lübke J, Naumann N, Hoffmann O, Horny HP, Sotlar K, Rudelius M, Metzgeroth G, Fabarius A, Hofmann WK, Reiter A, Schwaab J. A clinical, morphological and molecular study of 70 patients with gastrointestinal involvement in systemic mastocytosis. *Sci Rep*. 2024;14:702.
4. Yam LT, Chan CH, Li CY. Hepatic involvement in systemic mast cell disease. *Am J Med*. 1986;80:819-826.



Address for Correspondence/Yazışma Adresi: Alper Koç, M.D., University of Health Sciences Türkiye, Elazığ Fethi Sekin City Hospital, Clinic of Hematology, Elazığ, Türkiye
E-mail: alperkoc44@hotmail.com **ORCID:** orcid.org/0000-0003-0844-2658

Received/Geliş tarihi: August 6, 2025
Accepted/Kabul tarihi: September 1, 2025
Epub: September 2, 2025
DOI: 10.4274/tjh.galenos.2025.2025.0333



©Copyright 2026 by Turkish Society of Hematology Turkish Journal of Hematology, Published by Galenos Publishing House.
Licensed under a Creative Commons Attribution-NonCommercial (CC BY-NC-ND) 4.0 International License.