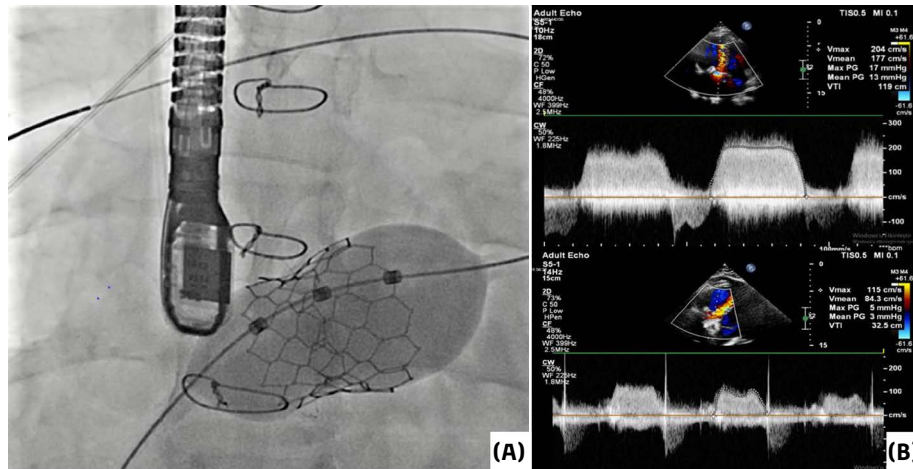


## Transcatheter Tricuspid Valve-in-Valve Replacement in a Patient with Ebstein Anomaly

### Ebstein Anomalisi Olan Bir Hastada Transkateter Triküspit Kapak-İçinde-Kapak Değişimi

A 26-year-old male patient with Ebstein anomaly was hospitalized due to New York Heart Association (NYHA) III dyspnea and syncope. He underwent tricuspid valve repair in 2006, and subsequently a bioprosthetic valve implantation was performed in 2011 due to recurrence of symptoms. Transthoracic echocardiography revealed a mean gradient of 13 mmHg and a maximum gradient of 17 mmHg across the bioprosthetic tricuspid valve, and 24-hour Holter monitoring detected transient 2:1 atrioventricular block. After Heart Team discussion, transcatheter tricuspid valve-in-valve replacement with a balloon-expandable aortic valve and surgical pacemaker implantation was decided.

After surgical epicardial lead placement, the patient was admitted to the catheterization laboratory. A stiff wire was positioned in the right pulmonary artery following right femoral transvenous access. Predilatation with a 23 × 40 mm balloon was performed at the level of the tricuspid valve, and subsequently a 30.5 mm balloon-expandable bioprosthetic aortic valve (Myval, Meril, India) was implanted (Figure 1). Right heart ventriculography showed no tricuspid regurgitation. Control echocardiography revealed significant diminution of tricuspid transvalvular velocity. The patient was event-free at the 6-month follow-up.



**Figure 1. (A) Implantation of a balloon-expandable bioprosthetic valve. (B) Mean and maximum gradients of the tricuspid valve on echocardiography before and after the procedure.**

### CASE IMAGE OLGU GÖRÜNTÜSÜ

Eser Durmaz<sup>1</sup>

Ayten Özal<sup>1</sup>

Damla Raimoglu<sup>1</sup>

Murat Çimci<sup>1</sup>

Teoman Kılıç<sup>2</sup>

Bilgehan Karadağ<sup>1</sup>

<sup>1</sup>Department of Cardiology, Cerrahpaşa Faculty of Medicine, Istanbul University-Cerrahpaşa, Istanbul, Türkiye

<sup>2</sup>Department of Cardiology, Kocaeli University Faculty of Medicine, Kocaeli, Türkiye

**Corresponding author:**

Murat Çimci

✉ murat\_cimci@hotmail.com

**Received:** December 23, 2025

**Accepted:** December 29, 2025

**Cite this article as:** Durmaz E, Özal A, Raimoglu D, Çimci M, Kılıç T, Karadağ B. Transcatheter Tricuspid Valve-in-Valve Replacement in A Patient with Ebstein Anomaly. *Türk Kardiyol Dern Ars.* 2026;54(2):197-198.

DOI: 10.5543/tkda.2025.39652



Copyright@Author(s)

Available online at [archivestsc.com](http://archivestsc.com).

Content of this journal is licensed under a Creative Commons Attribution - NonCommercial-NoDerivatives 4.0 International License.

**Ethics Committee Approval:** This is a single case image, and therefore ethics committee approval was not required in accordance with institutional policies.

**Informed Consent:** Informed consent was obtained from the patient.

**Conflict of Interest:** The authors have no conflicts of interest to declare.

**Funding:** The authors declared that this study received no financial support.

**Use of AI for Writing Assistance:** Artificial intelligence (AI)- assisted technologies (such as Large Language Models [LLMs], chatbots, or image creators) was not used in the production of this paper.

**Author Contributions:** Concept – E.D., A.Ö.; Design – M.Ç., T.K.; Supervision

– T.K., B.K.; Resource – A.Ö., D.R.; Materials – A.Ö.; Data Collection and/or Processing – E.D., D.R.; Analysis and/or Interpretation – B.K.; Literature Review – M.Ç.; Writing – E.D., M.Ç.; Critical Review – T.K., B.K.

**Peer-review:** Internally peer-reviewed.