

A Noonan Syndrome Mimicking Acute Coronary Syndrome

Akut Koroner Sendromu Taklit Eden Bir Noonan Sendromu

ABSTRACT

Noonan syndrome is a genetic disorder that can present with a wide range of clinical manifestations, making diagnosis challenging. This article presents the case of a 29-year-old male who presented with chest pain and ST-segment elevation, initially raising suspicion for acute coronary syndrome. However, coronary angiography revealed only ectasia of the coronary arteries, with no other pathological findings. A detailed physical examination and echocardiography revealed a pulmonary murmur, pectus excavatum, and café-au-lait spots. Additionally, both echocardiography and cardiac magnetic resonance imaging (MRI) showed localized left ventricular hypertrophy. Genetic testing identified a heterozygous missense variant in the *PTPN11* gene, leading to the diagnosis of Noonan syndrome. This case highlights the importance of thorough physical examination and multimodal imaging in the diagnosis of Noonan syndrome.

Keywords: Electrocardiogram, Noonan syndrome, physical examination

ÖZET

Noonan Sendromu, geniş bir klinik yelpazede farklı semptomlarla kendini gösterebilen ve bu nedenle tanısı zorlayıcı olan genetik bir bozukluktur. Bu yazıda, göğüs ağrısı ve ST-segment elevasyonu ile başvuran 29 yaşındaki bir erkek hasta sunulmuştur. İlk aşamada akut koroner sendrom tanısı düşünülmüş ancak koroner anjiyografi sonuçlarında koroner arterlerde ektazi dışında herhangi bir patolojik bulguya rastlanmamıştır. Detaylı fizik muayene ve ekokardiyografi ile hastada pulmoner odakta üfürüm, pektus ekskavatum ve cafe-au-lait lekeleri gözlemlenmiş, ayrıca ekokardiyografide ve kardiyak MRI'da sol ventrikülde lokalize hipertrofi saptanmıştır. Yapılan genetik incelemede *PTPN11* geninde heterozigot varyant tespit edilerek hastaya Noonan sendromu tanısı konulmuştur. Bu vaka, Noonan Sendromu tanısında ayrıntılı fizik muayenenin ve multimodalite görüntüleme tekniklerinin kullanımının önemini vurgulamaktadır.

Anahtar Kelimeler: Elektrokardiyogram, Noonan sendromu, fizik muayene

Noonan syndrome (NS) is an autosomal dominant inherited condition characterized by multisystem involvement. The phenotypic presentation can vary widely, and diagnosis is typically based on a combination of clinical features such as characteristic facial features, short stature, skeletal abnormalities, cardiac defects, and family history (Table 1).¹ The broad spectrum of manifestations can make diagnosis challenging. In this article, we present a case in which a patient initially presented with symptoms mimicking acute coronary syndrome, but without typical features of NS such as short stature, developmental delay, or a family history. The diagnosis was ultimately established through a detailed physical examination and patient history.

Case Report

A 29-year-old male with no known history of chronic illness presented to the emergency department with chest pain, described as pressure-like and constrictive. An initial electrocardiogram (ECG) revealed findings suggestive of ischemia, prompting measurement of high-sensitivity troponin levels, which were within normal limits. Given these findings, coronary computed tomography angiography (CTA) was performed and showed no evidence of coronary plaques or vascular anomalies. A few days later, the patient presented to another hospital with similar


CASE REPORT OLGU SUNUMU

Mustafa Yılmaz¹ 

Arda Güler² 

Elif Ayduk Gövdeli³ 

Mehmet Karacan⁴ 

Gamze Babur Güler² 

¹Department of Cardiology, Gaziosmanpaşa Research and Training Hospital, Istanbul, Türkiye

²Department of Cardiology, Mehmet Akif Ersoy Cardiothoracic and Vascular Surgery Training and Research Hospital, Istanbul, Türkiye

³Department of Cardiology, Royal Brompton & Harefield NHS Foundation Trust, London, United Kingdom

⁴Department of Pediatric Cardiology, Ümraniye Training and Research Hospital, Istanbul, Türkiye

Corresponding author:

Mustafa Yılmaz
✉ drmustafayilmaz@outlook.com

Received: March 28, 2025

Accepted: May 28, 2025

Cite this article as: Yılmaz M, Güler A, Ayduk Gövdeli E, Karacan M, Babur Güler G. A Noonan Syndrome Mimicking Acute Coronary Syndrome. *Turk Kardiyol Dern Ars.* 2025;54(3):277–281.

DOI: 10.5543/tkda.2025.48459



Available online at archivestsc.com.
Content of this journal is licensed under a Creative Commons Attribution – NonCommercial–NoDerivatives 4.0 International License.

chest pain. An ECG performed at the second hospital revealed ST-segment elevation in the inferior leads and ST-segment depression in the lateral leads (Figure 1A). Due to the severity of the chest pain, conventional coronary angiography (CAG) was promptly performed. CAG revealed ectatic coronary arteries but no evidence of plaques or thrombus (Figure 1B). Additionally, laboratory tests, including D-dimer levels, were within normal limits, effectively ruling out differential diagnoses such as pulmonary embolism and aortic dissection. Thoracic imaging also showed no pulmonary pathology. The patient was started on calcium channel blocker therapy, but his chest pain persisted. Upon a third presentation, physical examination revealed a pulmonary murmur, prompting further evaluation with transthoracic echocardiography (TTE). TTE demonstrated increased wall thickness at the basal anteroseptum, along with turbulent flow and an elevated gradient across the pulmonary valve (Figure 1C). These findings raised suspicion of a genetic cardiomyopathy, leading to a more detailed physical examination. Notably, the patient exhibited left palpebral ptosis, marked pectus excavatum, and café-au-lait spots on the skin (Figure 1D-E-F). Despite these findings, his height was 180 cm, and there was no family history of genetic or chronic diseases. Given the constellation of clinical signs, cardiac magnetic resonance imaging (MRI) was performed, revealing localized thickening of the basal anteroseptum up to 21 mm, with patchy enhancement in the hypertrophic region (Figure 1G-H).

Due to the combination of structural cardiac abnormalities and syndromic features, molecular genetic testing was conducted using a clinical exome approach based on next-generation sequencing (NGS) technology. A heterozygous missense variant was identified in the *PTPN11* (protein tyrosine phosphatase, non-receptor type 11) gene (NM_002834.5): c.1403C>T, resulting in a threonine-to-methionine substitution at codon 468 (p.Thr468Met). This pathogenic variant affects a highly conserved residue within the protein tyrosine phosphatase domain of SHP2 (Src Homology 2-containing Protein Tyrosine Phosphatase 2), a critical component of the RAS/MAPK signaling pathway. Based on these findings, along with clinical and imaging features, a diagnosis of Noonan syndrome was established.

ABBREVIATIONS

CAG	Conventional coronary angiography
CFCS	Cardio-facio-cutaneous syndrome
CTA	Computed tomography angiography
MRI	Magnetic resonance imaging
NS	Noonan syndrome
PVS	Pulmonary valve stenosis
TTE	Transthoracic echocardiography

Discussion

Noonan syndrome is classified among a group of hereditary disorders known as RASopathies, which result from genetic variants affecting the RAS/MAPK signaling pathway. This group includes NS, Costello syndrome, cardio-facio-cutaneous syndrome (CFCS), LEOPARD syndrome (also known as Noonan syndrome with multiple lentigines or NSML), Legius syndrome, and several other related conditions.² Although these syndromes share overlapping phenotypic features, they differ in terms of their underlying genetic variants. Among the RASopathies, NS is the most common subtype and is clinically characterized by cardiac anomalies, distinctive facial features, short stature, and developmental delays. The estimated incidence at birth ranges from 1 in 1,000 to 1 in 2,500 live births.³ NS is typically inherited in an autosomal dominant manner and is often associated with de novo variants; however, a recessive form has also been described more recently.⁴ The broad phenotypic variability and the age-related attenuation of some features can complicate clinical diagnosis. Cardiac involvement is one of the hallmark features of Noonan syndrome. Pulmonary valve stenosis (PVS) and hypertrophic cardiomyopathy (HCM) are the most frequently observed cardiac abnormalities, although a range of other structural cardiac defects has also been reported, further expanding the phenotypic spectrum (Table 2).²

To date, more than 20 genes have been associated with NS. Among them, *PTPN11*, *SOS1*, *RAF1*, *RIT1*, *KRAS*, *NRAS*, *BRAF*, *LZTR1*, and *SOS2* are the most prominent. Nevertheless, in approximately 10%-20% of cases, the causative variant remains unidentified. *PTPN11* was the first gene identified in

Table 1. Diagnostic criteria for Noonan syndrome (van der Burgt, 2007)¹⁵

Feature	Major criteria	Minor criteria
1. Facial dysmorphism	Typical facial features (age-dependent), including hypertelorism, ptosis, low-set ears, etc.	Suggestive but not typical facial features
2. Cardiac defects	Pulmonary valve stenosis, hypertrophic cardiomyopathy, or typical electrocardiogram (ECG) abnormalities	Other congenital heart defects
3. Height	Height < 3 rd percentile	Height < 10 th percentile
4. Chest wall	Pectus carinatum or pectus excavatum	Broad chest
5. Family history	First-degree relative with a confirmed diagnosis of Noonan syndrome	First-degree relative with suggestive features of Noonan syndrome
6. Other findings	All three of the following: intellectual disability, cryptorchidism, and lymphatic dysplasia	Any one of: intellectual disability, cryptorchidism, or lymphatic dysplasia

A diagnosis of Noonan syndrome can be made if either of the following combinations is present: Typical facial features (1 major facial criterion) plus one additional major criterion or two minor criteria OR Suggestive facial features plus two major criteria or three minor criteria.

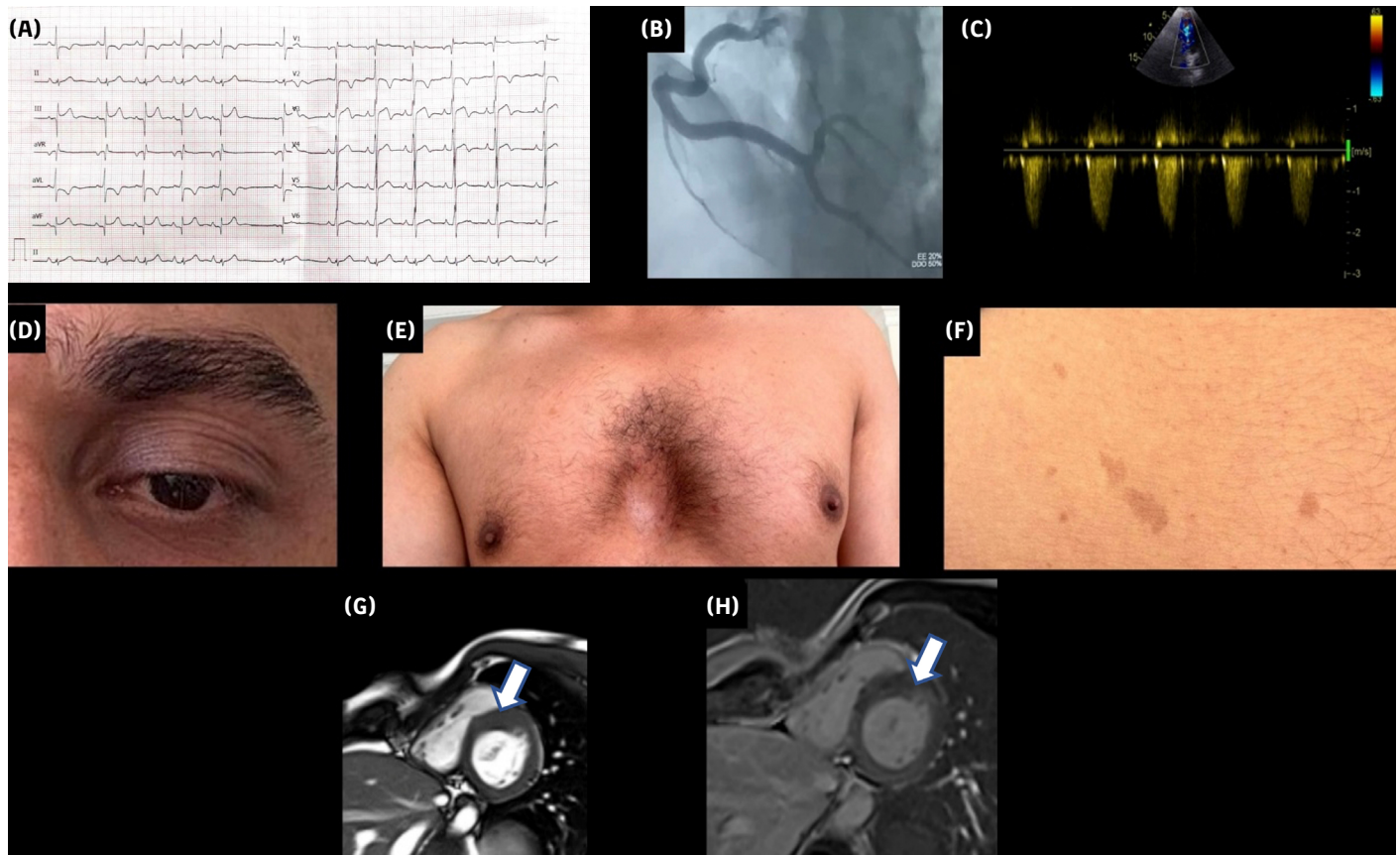


Figure 1. (A) Electrocardiogram (ECG) showing inferior ST-segment elevation. (B) Coronary angiography image demonstrating an ectatic right coronary artery. (C) Doppler echocardiography showing an increased gradient across the pulmonary valve. (D) Ptosis. (E) Pectus excavatum. (F) Café-au-lait spots. (G) Cardiac magnetic resonance imaging short-axis view showing increased wall thickness at the basal anteroseptum (white arrow). (H) Cardiovascular magnetic resonance imaging short-axis view with patchy late gadolinium enhancement in the hypertrophied segment (white arrow).

Table 2. Cardiac involvement in Noonan syndrome^{2,12,16}

Cardiac finding	Prevalence (%)	Clinical significance
PVS	~50-60%	Most common defect; often associated with a dysplastic pulmonary valve
HCM	~20-30%	May result in arrhythmias or sudden cardiac death
ASD	~6-10%	Frequently of the ostium secundum type
VSD	~5-10%	Typically small and hemodynamically insignificant
PDA	<5%	May persist beyond infancy
Branch pulmonary artery stenosis	~10%	May coexist with pulmonary valve stenosis (PVS)
Coarctation of the aorta	Rare (~1-2%)	More commonly seen in other RASopathies
Mitral valve abnormalities	Uncommon	Includes mitral valve prolapse and insufficiency
ECG abnormalities	Common (~40-60%)	Includes left axis deviation, RSR ^l in V1, and prolonged QTc
Arrhythmias	Rare but serious	Typically associated with hypertrophic cardiomyopathy (HCM) or accessory pathways

ASD, Atrial septal defect; ECG, electrocardiogram; HCM, hypertrophic cardiomyopathy; PDA, patent ductus arteriosus; PVS, pulmonary valve stenosis; VSD, ventricular septal defect.

association with NS and remains the most commonly mutated, accounting for approximately 50% of all NS cases and 85% of cases of LEOPARD syndrome (NSML). *PTPN11* encodes SHP2, a cytoplasmic enzyme widely expressed across tissues, which

regulates multiple intracellular signaling pathways involved in cell proliferation, differentiation, and survival. SHP2 plays a critical role in normal cardiac development and function, and variants in *PTPN11* are most commonly associated with PVS and HCM.^{5,6}

Noonan syndrome is a complex genetic disorder characterized by cardiac anomalies, growth retardation, developmental delays, and neuropsychosocial issues. Long-term follow-up studies have shown that the mortality rate in individuals with NS is approximately three times higher than in the general population. While most deaths are related to severe cardiac conditions, factors such as cognitive impairments, poor educational outcomes, and social isolation also negatively impact quality of life. Therefore, early diagnosis and preventive interventions are crucial in managing NS. However, the phenotypic heterogeneity of the syndrome often complicates the diagnostic process.⁷

In our case, the diagnosis was complicated by several factors. One of the most significant challenges was the patient's chief complaint of chest pain, accompanied by ST-segment elevation in the inferior leads on ECG. While ST elevation on ECG is a critical finding for the diagnosis of myocardial infarction, studies have shown that a significant number of patients with hypertrophic cardiomyopathy also exhibit ST-segment elevation.^{8,9} In a study by Yang et al.,¹⁰ ST-segment elevations in patients with HCM were compared to those in patients with myocardial infarction. It was found that ST elevations in HCM patients persisted longer and were more frequently associated with T-wave inversions in multiple leads, distinguishing them from myocardial infarction cases. In our patient, follow-up ECGs showed a persistent ST elevation pattern and T-wave changes in leads V2-V3, findings consistent with those reported by Yang et al.¹⁰ Additionally, electrocardiographic findings such as left axis deviation, small R-waves in the left precordial leads, large S-waves in the right precordial leads, abnormal Q-waves, and/or a wide QRS complex have also been reported in patients with NS.¹¹

Another challenge in diagnosis was the patient's normal height. Short stature is a common feature in individuals with NS, particularly in those with *PTPN11* variants. However, some patients may present with normal height, indicating that this feature alone is not sufficient to rule out the diagnosis.¹² The absence of prominent facial features, such as palpebral ptosis, further complicated the diagnostic process. Moreover, the negative family history in this case added another layer of complexity. Nevertheless, as mentioned earlier, de novo variants occur in a considerable number of cases, indicating that a negative family history does not necessarily exclude the condition.

As previously discussed, the diagnostic challenges of NS can often be addressed through detailed anamnesis and a comprehensive physical examination. Despite several complicating factors in our patient's case, key clinical findings played a significant role in reaching the correct diagnosis. The patient exhibited a prominent pectus excavatum, one of the characteristic features of NS.¹³ Additionally, the presence of a murmur in the pulmonary area, skin lesions, and mild left palpebral ptosis were crucial diagnostic clues. Although the chest deformity made echocardiographic evaluation more challenging, the use of multimodal imaging, including cardiac MRI, provided valuable insights by revealing localized hypertrophy that might have otherwise been overlooked. The application of advanced imaging techniques, particularly cardiac MRI, was pivotal in identifying subtle hypertrophic changes, underscoring the importance of a multimodal approach in complex diagnostic cases. Furthermore, the presence of coronary artery ectasia, a finding previously reported in NS, offered additional support for the diagnosis.¹⁴

Conclusion

This case highlights the diagnostic challenges associated with NS, emphasizing the importance of a detailed medical history and comprehensive physical examination in reaching an accurate diagnosis. Given the heterogeneous clinical presentation, it is essential to utilize available diagnostic tools, such as cardiac MRI and other imaging techniques, to support clinical findings. The combination of careful physical assessment and advanced imaging can significantly aid in distinguishing NS from other conditions, ultimately facilitating timely and appropriate management.

Ethics Committee Approval: This is a single case report, and therefore ethics committee approval was not required in accordance with institutional policies.

Informed Consent: Written informed consent was obtained from the patient for the publication of this case report.

Conflict of Interest: The authors have no conflicts of interest to declare.

Funding: The authors declared that this study received no financial support.

Use of AI for Writing Assistance: No AI-usage was declared by the authors.

Author Contributions: Concept – M.Y., A.G., E.A.G.; Design – M.Y.; Supervision – M.Y., M.K., G.B.G.; Resource – E.A.G.; Materials – M.Y.; Data Collection and/or Processing – M.Y.; Analysis and/or Interpretation – M.Y., A.G., M.K., G.B.G.; Literature Review – M.Y., E.A.G.; Writing – M.Y.; Critical Review – G.B.G.

Peer-review: Externally peer-reviewed.

References

- Zenker M, Edouard T, Blair JC, Cappa M. Noonan syndrome: improving recognition and diagnosis. *Arch Dis Child.* 2022;107(12):1073-1078. [CrossRef]
- Faienza MF, Meliotta G, Mentino D, et al. Cardiac Phenotype and Gene Mutations in RASopathies. *Genes (Basel).* 2024;15(8):1015. [CrossRef]
- Zenker M. Clinical overview on RASopathies. *Am J Med Genet C Semin Med Genet.* 2022;190(4):414-424. [CrossRef]
- Johnston JJ, van der Smagt JJ, Rosenfeld JA, et al.; Members of the Undiagnosed Diseases Network; Zenker M, Lee B, Biesecker LG. Autosomal recessive Noonan syndrome associated with biallelic LZTR1 variants. *Genet Med.* 2018;20(10):1175-1185. [CrossRef]
- Leoni C, Blandino R, Delogu AB, et al. Genotype-cardiac phenotype correlations in a large single-center cohort of patients affected by RASopathies: Clinical implications and literature review. *Am J Med Genet A.* 2022;188(2):431-445. [CrossRef]
- Asmamaw MD, Shi XJ, Zhang LR, Liu HM. A comprehensive review of SHP2 and its role in cancer. *Cell Oncol (Dordr).* 2022;45(5):729-753. [CrossRef]
- Binder G, Grathwol S, von Loeper K, et al. Health and quality of life in adults with Noonan syndrome. *J Pediatr.* 2012;161(3):501-505. e1. [CrossRef]
- Thygesen K, Alpert JS, Jaffe AS, et al.; Executive Group on behalf of the Joint European Society of Cardiology (ESC)/American College of Cardiology (ACC)/American Heart Association (AHA)/World Heart Federation (WHF) Task Force for the Universal Definition of Myocardial Infarction. Fourth Universal Definition of Myocardial Infarction (2018). *J Am Coll Cardiol.* 2018;72(18):2231-2264. [CrossRef]
- Sheikh N, Papadakis M, Panoulas VF, et al. Comparison of hypertrophic cardiomyopathy in Afro-Caribbean versus white patients in the UK. *Heart.* 2016;102(22):1797-1804. [CrossRef]

10. Yang YQ, Pei YH, Situ QS, Du XZ, Chen XH, He AX. ECG criteria to distinguish hypertrophic cardiomyopathy featured with "Pseudo-STEMI" from acute ST-elevation myocardial infarction. *J Electrocardiol.* 2023;77:10-16. [\[CrossRef\]](#)
11. Vos E, Leenders E, Werkman SR, Udink Ten Cate FEA, Draaisma JMT. The added value of the electrocardiogram in Noonan syndrome. *Cardiol Young.* 2022;32(6):936-943. [\[CrossRef\]](#)
12. Roberts AE, Allanson JE, Tartaglia M, Gelb BD. Noonan syndrome. *Lancet.* 2013;381(9863):333-342. [\[CrossRef\]](#)
13. Athota JP, Bhat M, Nampoothiri S, et al. Molecular and clinical studies in 107 Noonan syndrome affected individuals with *PTPN11* mutations. *BMC Med Genet.* 2020;21(1):50. [\[CrossRef\]](#)
14. Ly R, Soulat G, Iserin L, Ladouceur M. Coronary artery disease in adults with Noonan syndrome: Case series and literature review. *Arch Cardiovasc Dis.* 2021;114(8-9):598-605. [\[CrossRef\]](#)
15. van der Burgt I. Noonan syndrome. *Orphanet J Rare Dis.* 2007;2:4. [\[CrossRef\]](#)
16. Prendiville TW, Gauvreau K, Tworog-Dube E, et al. Cardiovascular disease in Noonan syndrome. *Arch Dis Child.* 2014;99(7):629-634. [\[CrossRef\]](#)