

# Does double fluoroscopy reduce operative and radiation time in femoral neck fracture fixation?

Meliksah Uzakgider, Onur Süer, Recep Selçuk Eyceyurt, Mesut Tahta, Cemil Kayalı

Department of Orthopaedics and Traumatology, Izmir City Hospital, Izmir-Türkiye

## ABSTRACT

**BACKGROUND:** This study aimed to evaluate the advantages of using double fluoroscopy during closed reduction and internal fixation of femoral neck fractures.

**METHODS:** In this prospective randomized study, 42 patients with femoral neck fractures treated between January 2021 and September 2022 were included. Patients were randomly assigned to one of two groups: double fluoroscopy (Group A, n=20) or single fluoroscopy (Group B, n=22). The groups were compared in terms of preparation time, operative time, preparatory radiation time, and intraoperative radiation time.

**RESULTS:** Baseline characteristics were comparable between the groups. There were no significant differences in age, sex, fracture side, fracture classification (Garden and Pauwels), mechanism of injury, anesthesia method, time to surgery, or duration of follow-up. The mean operative times were 73.1±7.25 minutes and 85.59±9.94 minutes for the double and single fluoroscopy groups, respectively (p<0.001). Total radiation times were 92.2±8.4 seconds and 113.27±18.1 seconds, respectively (p<0.001). Both operative and radiation times were significantly shorter in the double C-arm fluoroscopy group compared to the single C-arm fluoroscopy group.

**CONCLUSION:** The use of a double fluoroscopy technique was associated with a significant reduction in operative time and radiation exposure.

**Keywords:** Closed reduction; double C-arm; femoral neck fractures; fluoroscopy; internal fixation.

## INTRODUCTION

The global incidence of hip fractures is increasing, largely driven by an aging population and the rising prevalence of osteoporosis. Current projections estimate that the number of hip fractures will reach 2.6 million by 2025 and may increase to 4.5 million by 2050.<sup>[1]</sup> The etiology of hip fractures demonstrates a bimodal distribution: the classic pattern of low-energy falls in osteoporotic elderly individuals and an emerging pattern of high-energy trauma leading to femoral neck fractures (FNF) in adults, typically aged 40–50 years.

Closed reduction and internal fixation (CRIF) is the preferred treatment modality for younger patients, as it preserves the joints and is relatively straightforward when performed un-

der fluoroscopic (C-arm) guidance.<sup>[2,3]</sup> Internal fixation with cannulated screws exposes surgical teams to higher levels of radiation than most other orthopedic procedures. Consequently, prolonged exposure to elevated radiation levels may increase the risk of malignancy among orthopedic staff.<sup>[4]</sup>

Minimizing unnecessary radiation exposure during fluoroscopy is therefore essential. Single fluoroscopy is commonly used due to its availability and ease of operation. However, repeated repositioning to obtain anteroposterior (AP) and lateral (L) views may lead to workflow inefficiencies. The use of two fluoroscopy units in fixed positions could eliminate the need for intraoperative repositioning, potentially reducing both operative time and radiation exposure.

Cite this article as: Uzakgider M, Süer O, Eyceyurt S, Tahta M, Kayalı C. Does double fluoroscopy reduce operative and radiation time in femoral neck fracture fixation? *Ulus Travma Acil Cerrahi Derg* 2026;32:715-721.

Address for correspondence: Meliksah Uzakgider

Department of Orthopaedics and Traumatology, Izmir City Hospital, Izmir, Türkiye

E-mail: meliksahu@gmail.com

*Ulus Travma Acil Cerrahi Derg* 2026;32(6):715-721 DOI: 10.14744/tjtes.2026.72823

Submitted: 11.08.2025 Revised: 08.01.2026 Accepted: 16.01.2026 Published: 03.06.2026

OPEN ACCESS This is an open access article under the CC BY-NC license (<http://creativecommons.org/licenses/by-nc/4.0/>).



This study presents the results of a trial comparing single versus double fluoroscopy for the placement of cannulated screws in the treatment of FNF. We hypothesize that double fluoroscopy results in shorter operative times and lower radiation exposure.

## MATERIALS AND METHODS

### Study Design and Patient Characteristics

This study was conducted between January 2021 and September 2022 and included patients who underwent closed reduction and internal fixation for femoral neck fractures at the Department of Orthopedic Surgery in our hospital. Ethical approval was obtained from the the Izmir Bozyaka Training and Research Hospital Medical Research Ethics Committee (Decision no : 2022/22, Date: 26.01.2022). Written informed consent was obtained from all participants, including consent

for the use of their personal data. The study was conducted in accordance with the principles of the Declaration of Helsinki.

A total of 42 patients were enrolled and randomized into two treatment groups: Group A (n=20, mean age=51.1 years), treated using a double fluoroscopy technique, and Group B (n=22, mean age=47.64 years), treated using a single fluoroscopy technique. Randomization was performed using a sealed-envelope method with sequentially numbered, opaque envelopes prepared prior to enrollment to ensure allocation concealment. Patients with inflammatory rheumatic diseases, a history of prior hip surgery, multiple trauma, or age under 18 years were excluded from the study. Demographic and clinical characteristics were recorded, including age, sex, fracture side, fracture type (according to Garden and Pauwels classifications), mechanism of injury, anesthesia method, and time from injury to surgery (Table 1).

**Table 1.** Demographic and clinical characteristics of the study groups

	<b>Group A (Double fluoroscopy)</b>	<b>Group B (Single fluoroscopy)</b>	<b>p</b>
n	20	22	
Age (years)	51.1±11.7	47.64±13.9	0.3916
Sex, n (%)			
Female	8 (40)	8 (36.4)	0.8141
Male	12 (60)	14 (63.6)	
Side, n (%)			
Left	10 (50)	10 (45.4)	0.7750
Right	10 (50)	12 (54.6)	
Mechanism of injury, n (%)			
Motor vehicle accident	5 (25)	4 (18.2)	0.6013
Fall	15 (75)	18 (81.8)	
Garden classification, n (%)			
Type I	2 (10)	2 (9.1)	0.7301
Type II	3 (17.5)	3 (13.6)	
Type III	3 (17.5)	2 (9.1)	
Type IV	12 (60)	15 (68.2)	
Pauwels classification, n (%)			
Type I	4 (20)	6 (27.3)	0.5128
Type II	4 (20)	5 (22.7)	
Type III	12 (60)	11 (50)	
Anesthesia, n (%)			
General	2 (10)	4 (18.2)	0.5128
Spinal	18 (90)	18 (81.8)	0.8077
Time from injury to surgery, mean±SD (hours)	5.47±5.99	6.1±4.78	0.7542
Follow-up time (months) (min-max)	20.8±5.54	20.09±5.14	0.6694

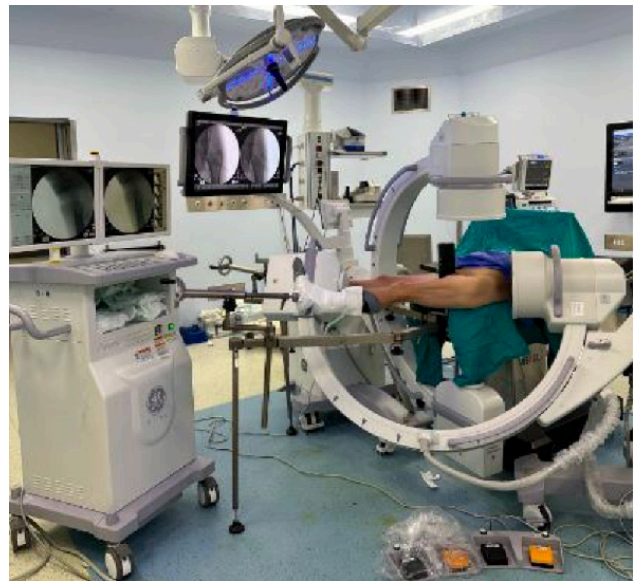SD: Standard deviation.

### Surgical Technique

All procedures were performed using a standardized surgical protocol, with patients positioned on a fracture table and fractures managed by closed reduction. In the double fluoroscopy group, one image intensifier was positioned near the hip joint with approximately a 15° tilt along the sagittal plane. A second fluoroscope was positioned from the contralateral side, with the image intensifier oriented superiorly. During FNF surgery, both anteroposterior and lateral views were simultaneously available (Fig. 1), eliminating the need for fluoroscope repositioning.

In the single fluoroscopy group, the fluoroscope was positioned between the patient's legs to allow accurate AP and lateral visualization of the fracture (Fig. 2). The quality of fracture reduction was assessed in both planes prior to skin preparation. During the procedure, fluoroscope positioning was adjusted dynamically by a technician according to intraoperative requirements.

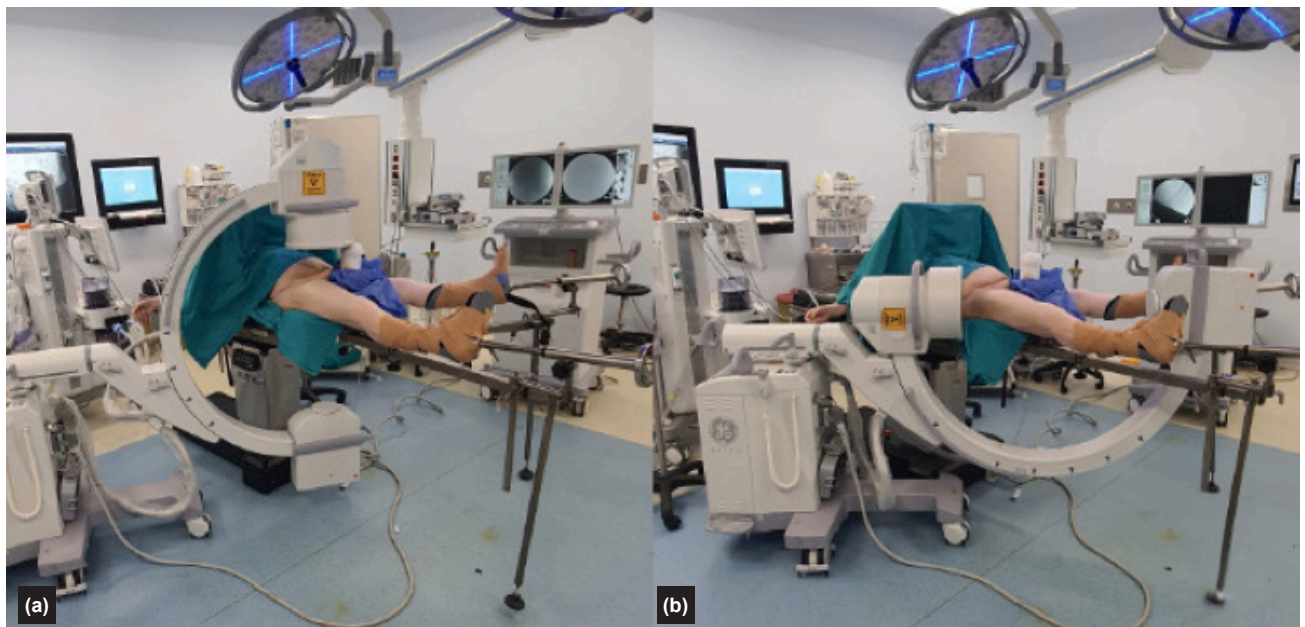
In FNF procedures, reduction was verified intraoperatively by adjusting the fracture table through internal and external rotation under fluoroscopic guidance. The surgical approach involved a 3-cm incision distal to the trochanter to expose the entry point. Three Kirschner wires were inserted in an inverted triangular configuration along the longitudinal axis of the femoral neck into the femoral head. The position and alignment of the K-wires were confirmed fluoroscopically, after which fracture fixation was achieved by insertion and tightening of three 6.5-mm cannulated screws (Fig. 3). The procedure was completed with wound closure using sutures.



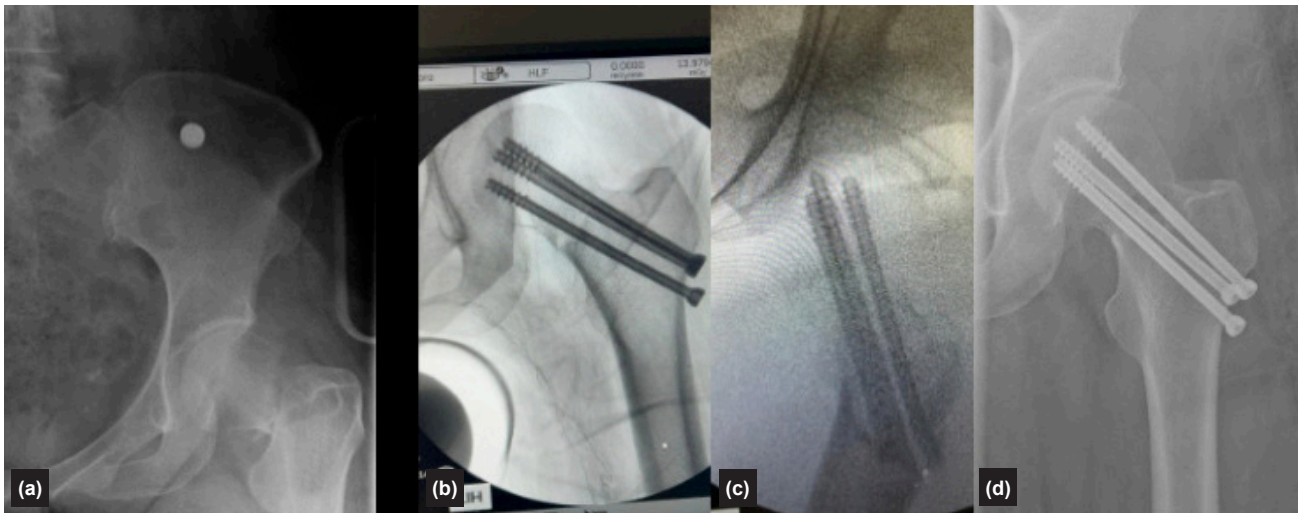
**Figure 1.** Patient positioning and double fluoroscopy setup prior to surgery.

### Assessment of Parameters Between Groups

All procedures were performed by a single senior orthopedic surgeon. Data assessment was conducted independently by another senior surgeon and medical personnel who were not involved in the surgical procedures. Depending on fracture type and degree of displacement, some cases required additional reduction maneuvers, which could increase fluoroscopy usage.



**Figure 2.** Patient positioning and single-fluoroscopy setup prior to surgery: (a) anteroposterior (AP) and (b) lateral fluoroscopic views of the fracture.



**Figure 3.** Surgical management of a femoral neck fracture: (a) preoperative X-ray, (b) intraoperative fluoroscopic images, and (c) postoperative X-ray.

### Outcome Measures

The primary outcome measures were operative time and fluoroscopy time. Operative time was subdivided into preparation time (defined as the interval from induction of anesthesia to skin incision), surgical time (defined as the interval from skin incision to wound closure), and total operative time. Fluoroscopy time was recorded separately for the preparatory and intraoperative phases, and total fluoroscopy time was calculated as the sum of these two periods. Operative times were recorded in minutes, and fluoroscopy times in seconds.

### Statistical Analysis

Categorical variables were expressed as frequencies and percentages and compared using Pearson's chi-square test or Fisher's exact test. Continuous variables were reported as mean±standard deviation (SD) for normally distributed data. Normality was assessed using the Shapiro–Wilk test, and homogeneity of variances using Levene's test. Between-group comparisons were performed using the independent samples t-test for parametric data and the Mann–Whitney U test for nonparametric data. A p-value <0.05 was considered statistically significant. Statistical analyses were performed using IBM SPSS Statistics, version 26.0 (IBM Corp., Armonk, NY, USA).

## RESULTS

The study included 42 patients with femoral neck fractures who underwent surgery between January 2021 and September 2022. Double fluoroscopy was used in 20 patients, and single fluoroscopy in 22. The median follow-up duration was 20.4±5.28 months, and the mean age was 49.3±12.9 years. Baseline characteristics were comparable between the groups, with no significant differences in age, sex, fracture side, fracture type (according to Garden and Pauwels classifications), mechanism of injury, anesthesia method, time from injury to surgery, or follow-up duration (Table 1).

For both groups, the preparatory phase (minutes) was defined as the interval from completion of anesthesia to skin incision, while surgical time was defined as the interval from incision to wound closure. The mean preparatory times were 24.9±2 minutes in the double fluoroscopy group and 29.05±3.08 minutes in the single fluoroscopy group ( $p<0.001$ ). The mean surgical times were 48.2±7.42 minutes and 56.14±7.45 minutes, respectively ( $p<0.001$ ). Total operative times were 73.1±7.25 minutes in the double fluoroscopy group and 85.59±9.94 minutes in the single fluoroscopy group ( $p<0.001$ ). Statistical analysis revealed significant differences between the groups for these parameters (Table 2), with shorter operative times observed in the double fluoroscopy group.

Preparatory radiation time (seconds) was defined as the interval from completion of anesthesia to skin incision. Radiation exposure during the operative phase (from incision to wound closure) was significantly lower in the double fluoroscopy group (14.99±2.11 seconds) compared to the single fluoroscopy group (20.77±3.64 seconds;  $p=0.0001$ ). The mean intraoperative radiation times were 77.25±8 seconds for the double fluoroscopy group and 92.41±15.18 seconds for the single fluoroscopy group ( $p<0.001$ ). Total radiation times were 92.2±8.4 seconds and 113.27±18.1 seconds for the double and single fluoroscopy groups, respectively ( $p<0.001$ ). Comparative analysis demonstrated significantly shorter radiation times in the double fluoroscopy group (Table 2).

After a minimum follow-up of one year, nonunion was observed in two patients (10%) in the double fluoroscopy group, both of whom required total hip arthroplasty. In the single fluoroscopy group, three patients (13.6%) developed nonunion and subsequently underwent total hip arthroplasty. No wound infections were observed in either group.

**Table 2.** Operative and radiation exposure times of the study groups

	<b>Group A (Double fluoroscopy)</b>	<b>Group B (Single fluoroscopy)</b>	<b>p</b>
n	20	22	
Preparation time, mean±SD (min)	24.9±2	29.05±3.08	<0.001
Surgical time, mean±SD (min)	48.2±7.42	56.14±7.45	<0.001
Total operative time, mean±SD (min)	73.1±7.25	85.59±9.94	<0.001
Preparatory radiation time, mean±SD (s)	14.99±2.11	20.77±3.64	<0.001
Intraoperative radiation time, mean±SD (s)	77.25±8	92.41±15.18	<0.001
Total radiation time, mean±SD (s)	92.2±8.4	113.27±18.1	<0.001

SD: Standard deviation.

## DISCUSSION

In this study, we evaluated the efficacy of double fluoroscopy in the closed reduction and internal fixation of femoral neck fractures. Our findings demonstrate that the use of a double fluoroscopy system significantly reduces both operative time and radiation exposure compared to a single fluoroscopy approach. This improvement is likely attributable to the simultaneous visualization of anteroposterior and lateral views, which minimizes the need for repositioning the imaging device and enhances surgical workflow efficiency.

In contemporary orthopedic practice, percutaneous screw fixation is a standard treatment for femoral neck fractures in appropriately selected patients.<sup>[5]</sup> Although various factors, such as fixation technique, number and diameter of screws, and screw configuration, have been widely discussed in the literature, they were not the focus of this study and did not influence our methodology.<sup>[6-9]</sup> Fluoroscopy is essential during percutaneous screw fixation; however, it may present challenges, particularly for less experienced surgeons. The use of double fluoroscopy may offer advantages by reducing both radiation exposure and operative time. Notably, our literature review identified only one study comparing single and double fluoroscopy in the treatment of femoral neck fractures.<sup>[10]</sup>

Radiation exposure is a critical concern for both the surgical team and the patient. Mahajan et al.<sup>[4]</sup> reported a significant positive correlation between operative time and radiation exposure, emphasizing the importance of radiation safety precautions for orthopedic surgeons. Similarly, Herscovici et al.<sup>[11]</sup> recommended regular calibration of radiographic equipment, the use of protective gear, maintaining a safe distance from the X-ray source, and minimizing exposure time. Additionally, Hardman et al.<sup>[12]</sup> demonstrated a linear relationship between radiation exposure and cancer risk, which accumulates over an individual's lifetime and across populations. They suggested that, due to this cumulative effect, even small reductions in fluoroscopy use may lead to significant decreases in risk for both patients and surgeons, both in the long term

and at the population level. In the present study, total radiation exposure was significantly lower in the double fluoroscopy group compared to the single fluoroscopy group. This reduction not only benefits patients but also mitigates occupational risks for surgical staff who are routinely exposed to intraoperative radiation. Given the increasing awareness of the long-term health risks associated with radiation exposure, our findings support the use of double fluoroscopy as a safer alternative in orthopedic practice.

In addition to reducing radiation exposure, shortening operative time is another important advantage. Saad et al.<sup>[13]</sup> noted a general consensus that longer operative durations are associated with a higher risk of complications, highlighting the importance of minimizing surgical time. Likewise, Cheng et al.<sup>[14]</sup> emphasized that reducing operative time should be a shared goal among surgeons, hospitals, and policymakers due to its impact on complication rates. In our study, a significant reduction in operative time was observed in the double fluoroscopy group.

Despite differences in imaging techniques, no significant differences in nonunion rates were observed between the two groups. These findings are consistent with the existing literature on femoral neck fractures, indicating that surgical outcomes remain comparable regardless of the fluoroscopy technique used.<sup>[15-17]</sup> Liporace et al.<sup>[18]</sup> reported nonunion rates associated with implant failure ranging from 9% to 18%. In our study, no wound infections were observed, and a total of five patients (11.9%) required total hip arthroplasty due to nonunion.

The relatively small sample size represents a key limitation of this study and may affect the generalizability of the findings. With only 42 patients, the study may not fully capture the variability present in a broader population, potentially limiting statistical power and the ability to detect subtle differences between groups. Additionally, the limited cohort size may reduce the diversity of patient characteristics and fracture patterns, potentially affecting the applicability of the results

across different patient populations. Body mass index (BMI) was not evaluated in the study population and may represent a confounding factor, as it can influence image quality, operative complexity, and fluoroscopy requirements, potentially affecting both operative time and radiation exposure. Similarly, the lack of direct radiation dose measurements using dosimeters is a limitation of this study. Although fluoroscopy time serves as an indirect measure, it provides only a practical surrogate for radiation exposure; therefore, future studies incorporating direct dosimetry are needed for more precise evaluation. The absence of an a priori power analysis is another limitation. Although significant differences were observed in the primary outcomes, studies with predefined sample size calculations are needed to validate these findings. Larger-scale studies are required to confirm these results and to more comprehensively evaluate the benefits and limitations of double fluoroscopy in FNF management. The implications of our findings extend beyond operative efficiency. As the incidence of hip fractures continues to rise with an aging population, approaches that improve surgical outcomes while prioritizing safety will become increasingly important. In this context, the double fluoroscopy technique represents a promising advancement, balancing procedural effectiveness with reduced radiation exposure.

## CONCLUSION

Double fluoroscopy appears to reduce both operative time and fluoroscopy time during femoral neck fracture fixation. However, larger, multicenter studies incorporating direct radiation dose measurements are required before widespread adoption can be recommended.

**Ethics Committee Approval:** This study was approved by the Izmir Bozyaka Training and Research Hospital Medical Research Ethics Committee (Date: 26.01.2022, Decision No: 2022/22).

**Peer-review:** Externally peer-reviewed.

**Authorship Contributions:** Concept: M.U.; Design: M.U., O.S.; Supervision: C.K.; Resource: M.T.; Materials: M.U., O.S., R.S.E., M.T., C.K.; Data collection and/or processing: O.S., R.S.E.; Analysis and/or interpretation: M.U., M.T.; Literature review: R.S.E.; Writing: M.U., O.S., R.S.E., M.T.; Critical review: M.T., C.K.

**Conflict of Interest:** There is no financial conflict of interest with any commercial organization of the results of which products are described, examined, evaluated or compared in the article. None of the authors hold any financial interest in the products, devices or drugs mentioned in this article. We declare that this article, in whole or in part, has not been presented or published elsewhere and is original work.

**Financial Disclosure:** The author declared that this study has received no financial support.

## REFERENCES

1. Sterling R. S. Gender and race/ethnicity differences in hip fracture incidence, morbidity, mortality, and function. *Clinical Orthopaedics and Related Research*. 2011;469:1913-8. [\[CrossRef\]](#)
2. Zuckerman J. D. Hip fracture. *The New England Journal of Medicine* 1996;334:1519-25. [\[CrossRef\]](#)
3. Menzies IB, Mendelson DA, Kates SL, Friedman SM. The impact of comorbidity on perioperative outcomes of hip fractures in a geriatric fracture model. *Geriatr Orthop Surg Rehabil* 2012;3:129-34. [\[CrossRef\]](#)
4. Mahajan A, Samuel S, Saran AK, Mahajan MK, Mam MK. Occupational radiation exposure from C arm fluoroscopy during common orthopaedic surgical procedures and its prevention. *J Clin Diagn Res* 2015;9:RC01-4. [\[CrossRef\]](#)
5. Michelitsch C, Jochum B, Baer A, Haupt S, Stillohard PF, Copp J, et al. Closed reduction followed by percutaneous fixation of acute femoral neck fractures in young adults: a retrospective cohort study. *J Orthop Trauma* 2024;38:648-54. [\[CrossRef\]](#)
6. Gomez-Vallejo J, Blanco-Rubio N, Lorenzo-Lopez R, Embarba-Gascon M, Ezquerra-Herrando L, Zamora-Lozano M, et al. Outcomes of basicervical femoral neck fracture treated with percutaneous compression plate (PCCP). *Injury* 2021;52 Suppl 4:S42-S46. [\[CrossRef\]](#)
7. Jin ZY, Gu C, Yang HL, Xu M. Outcome of percutaneous compression plate for treatment of femoral neck fractures: mean follow-up of 4.4 years. *Int Orthop* 2022;46:1891-8. [\[CrossRef\]](#)
8. Bout CA, Cannegieter DM, Juttman JW. Percutaneous cannulated screw fixation of femoral neck fractures: the three point principle. *Injury* 1997;28:135-9. [\[CrossRef\]](#)
9. Cheng QH, Li PB, Lu TT, Guo SF, Di WF, Yang KH, et al. Computer-assisted cannulated screw internal fixation versus conventional cannulated screw internal fixation for femoral neck fractures: a systematic review and meta-analysis. *J Orthop Surg Res* 2021;16:687. [\[CrossRef\]](#)
10. Lee HH, Kang KY, Sung SY, Lee SB, Kim SH, Jung SI, et al. Femoral neck fractures treated by closed reduction and internal fixation with the double fluoroscope technique: a preliminary study. *J Clin Med* 2024;13:1418. [\[CrossRef\]](#)
11. Herscovici D Jr, Sanders RW. The effects, risks, and guidelines for radiation use in orthopaedic surgery. *Clin Orthop Relat Res* 2000;126-32. [\[CrossRef\]](#)
12. Hardman J, Elvey M, Shah N, Simson N, Patel S, et al. Defining reference levels for intra-operative radiation exposure in orthopaedic trauma: A retrospective multicentre study. *Injury* 2015;46:2457-60. [\[CrossRef\]](#)
13. Saad A, Patralekh MK, Jain VK, Shrestha S, Botchu R, Iyengar KP. Femoral neck system reduces surgical time and complications in adults with femoral neck fractures: A systematic review and meta-analysis. *J Clin Orthop Trauma* 2022;30:101917. [\[CrossRef\]](#)
14. Cheng H, Clymer JW, Po-Han Chen B, Sadeghirad B, Ferko NC, Cameron CG, et al. Prolonged operative duration is associated with complications: a systematic review and meta-analysis. *J Surg Res* 2018;229:134-44. [\[CrossRef\]](#)
15. Zhai Q, Wang F, He X, Zhou K, Chen N. Revision rate of displaced femoral neck fractures in non-elderly adults: a retrospective comparative study of the femoral neck system and cannulated screws. *J Orthop Surg Res* 2024;19:571. [\[CrossRef\]](#)
16. Kim SJ, Park HS, Lee DW. Complications after internal screw fixation of nondisplaced femoral neck fractures in elderly patients: A systematic review. *Acta Orthop Traumatol Turc* 2020;54:337-43. [\[CrossRef\]](#)
17. De Franco S, Ipponi E, Ruinato AD, Parchi PD, Andreani L, Scaglione M, et al. Femoral neck fractures treated with cannulated screws: can surgeons predict functional outcomes and minimize the risk of necrosis? *Acta Biomed* 2023;94:e2023013.
18. Liporace F, Gaines R, Collinge C, Haidukewych GJ. Results of internal fixation of Pauwels type-3 vertical femoral neck fractures. *J Bone Joint Surg Am* 2008;90:1654-9. [\[CrossRef\]](#)

ORİJİNAL ÇALIŞMA - ÖZ

## Femur boyun kırıklarının kapalı redüksiyon ve internal fiksasyonunda çift floroskopi belirgin avantajlar sağlar

**AMAÇ:** Bu çalışmanın amacı, femur boyun kırıklarının kapalı redüksiyon ve internal fiksasyonunda çift floroskopi kullanımının avantajlarını değerlendirmektir.

**GEREÇ VE YÖNTEM:** Bu prospektif randomize çalışmada, Ocak 2021 ile Eylül 2022 arasında opere edilen 42 femur boyun kırıklı hasta çalışmaya dahil edildi. Hastalar rastgele iki gruba ayrıldı: biri çift floroskopi cihazı kullanılan (Grup A, n=20), diğeri ise tek floroskopi cihazı kullanılan grup (Grup B, n=22). Gruplar hazırlık süresi, operasyon süresi, hazırlık radyasyon süresi ve operasyon radyasyon süresi açısından karşılaştırıldı.

**BULGULAR:** İki grup arasında yaş, cinsiyet, kırık tarafı, kırık tipi (Garden ve Pauwels sınıflamasına göre), yaralanma mekanizması, anestezi yöntemi, yaralanma ile cerrahi arasındaki süre ve takip süreleri açısından istatistiksel olarak anlamlı bir fark yoktu. Toplam operasyon süreleri çift ve tek C-kollu gruplar için sırasıyla  $73.1 \pm 7.25$  dakika ve  $85.59 \pm 9.94$  dakika idi ( $p=0.0001$ ). Toplam radyasyon süreleri ise çift ve tek C-kollu gruplar için sırasıyla  $92.2 \pm 8.4$  saniye ve  $113.27 \pm 18.1$  saniye olarak ölçüldü ( $p=0.0001$ ). Çift C-kollu grubun, tek C-kollu gruba kıyasla daha kısa operasyon ve radyasyon süresine sahip olduğu tespit edildi.

**SONUÇ:** Çift floroskopi tekniği, işlem sırasında hem cerrahi süreyi hem de radyasyon maruziyet süresini belirgin şekilde azaltabilmektedir.

**Anahtar sözcükler:** Femur boyun kırıkları; çift C-kollu floroskopi; kapalı redüksiyon; internal fiksasyon

Ulus Travma Acil Cerrahi Derg 2026;32(6):715-721 DOI: 10.14744/tjtes.2026.72823