ORIGINAL ARTICLE

Single-center experiences with a novel method for preoperative localization of thoracic spine lesions using computed tomography-guided pedicular spinal needle placement

Ali Rıza Güvercin, Mehmet Orbay Bıyık, Mehmet Aktoklu, Uğur Yazar, Ertuğrul Çakır

Department of Neurosurgery, Karadeniz Technical University, Trabzon-*Türkiye*

ABSTRACT

BACKGROUND: Localization of thoracic levels in the treatment of thoracic spine problems is more challenging than in other spinal regions. This study aimed to demonstrate the reliability of pedicular spinal needle placement under computed tomography guidance before thoracic spine surgery and to reduce the margin of error, surgery time, and operating room radiation exposure during thoracic spine and spinal cord surgery.

METHODS: Fourteen patients undergoing a posterior approach to the thoracic spine and/or spinal cord-related lesions were investigated. Spinocaths were placed under computed tomography (CT) guidance into the pedicle of the relevant vertebra on the same day or the night before surgery. The surgical field was prepared as usual, and a spinocath was placed in the relevant thoracic pedicle under CT guidance.

RESULTS: Intraoperative level localization was more reliable and easier in patients who underwent preoperative CT-guided marking for thoracic spine surgeries performed for various reasons. Shorter preoperative preparation and intraoperative anesthesia times, a reduction in the number of fluoroscopic images taken intraoperatively, and no instances of spinal mislocalization were observed.

CONCLUSION: The results suggest that localizing the surgical level with preoperative CT before all types of thoracic spine surgery is a safe, reliable, and effective method.

Keywords: Thoracic vertebrae; preoperative procedures; interventional radiography.

INTRODUCTION

Tumors causing significant erosion or trauma leading to pronounced deformation of the spine do not present a major challenge, as these defects can be easily visualized using fluoroscopic methods during surgery. However, determining the correct surgical level in conditions such as intradural tumors, thoracic disk herniations,[1] and soft tissue metastases is more difficult. In spinal pathologies, particularly at thoracic levels, operating at the wrong level is a common risk due to anatomical variations or difficulties in intraoperative fluoroscopy caused by osteopenia in the spine.[2-4] Surveys involving multiple spinal surgeons have shown that 50% have operated at the wrong level at least once.[5,6] Wrong-level surgeries not only necessitate additional operations, increase radiation exposure for the surgical team, and escalate costs, but they may also result in legal consequences. Most centers currently use intraoperative X-ray imaging to identify target spinal levels. This involves counting upward or downward from the lumbar or cervical spine. However, this method often makes it difficult,

Cite this article as: Güvercin AR, Bıyık MO, Aktoklu M, Yazar U, Çakır E. Single-center experiences with a novel method for preoperative localization of thoracic spine lesions using computed tomography-guided pedicular spinal needle placement. Ulus Travma Acil Cerrahi Derg 2025;31:371-374.

Address for correspondence: Mehmet Orbay Bıyık

Department of Neurosurgery, Karadeniz Technical University, Trabzon, Türkiye

E-mail: mehmetorbaybyk@yahoo.com

Ulus Travma Acil Cerrahi Derg 2025;31(4):371-374 DOI: 10.14744/tjtes.2025.82844

Submitted: 15.10.2024 Revised: 22.10.2024 Accepted: 16.01.2025 Published: 28.03.2025

OPEN ACCESS This is an open access article under the CC BY-NC license (http://creativecommons.org/licenses/by-nc/4.0/).

if not impossible, to accurately count levels below C7 due to obstruction by the bilateral scapulae and shoulders. This approach is prone to errors and increases radiation exposure, as multiple imaging attempts are required.

Wrong-level spinal surgery is a preventable but serious error. However, level mislocalization in spinal surgery remains an ongoing problem. Difficulties in level localization most frequently arise in thoracic spine surgeries. Therefore, accurate level determination before or during thoracic spine surgery is of utmost importance. While methods aimed at increasing patient and personnel safety during spinal surgery are also critical, minimizing radiation exposure for surgeons and surgical health personnel must be prioritized.

This study describes a simple, reliable, and effective method for localizing thoracic spinal levels to prevent wrong-level spinal surgery. In this method, a spinal needle is used as a fiducial marker and placed at the thoracic level where the pathology is present. Non-contrast computed tomography is then performed, and the correct level is marked for intraoperative localization.

MATERIALS AND METHODS

The study was conducted at Karadeniz Technical University following approval from Karadeniz Technical University Scientific Research Ethics Committee (Approval Number: 24237859-304, Date: 11.06.2020). All 14 patients who underwent marking for various thoracic spinal pathologies, including thoracic fractures, intradural/intramedullary tumors, and spondylodiscitis, between January 1, 2019 and July 30, 2020, were included (Table 1).

Patients scheduled for thoracic spinal surgery were taken to the computed tomography unit. The level of the pathology was determined using a computed tomography scanogram performed with the patient in the prone position, and the skin was marked with a surgical marker pen. The marked cutaneous region was then sterilized with an antiseptic solution. Under local anesthesia, an interventional radiologist inserted a spinal needle at the level of the vertebral pedicle where the pathology was identified. Non-contrast computed tomography was performed to confirm whether the spinal needle was correctly positioned. Once the appropriate placement was verified, the procedure was concluded. Some case examples are provided (Figs. 1-3).

Statistical Methods

Descriptive statistics were used to summarize the demographic characteristics and clinical data of the patients. Continuous variables, such as age, were presented as mean ± standard deviation (SD). Categorical variables, including gender and types of pathologies, were reported as frequencies and percentages.

The success rate of fiducial marker placement was calculated as the proportion of patients in whom the marker was accurately placed and confirmed through radiological reports and 3D imaging. The frequency distribution of fiducial marker placements across different thoracic spine levels was analyzed.

No statistical hypothesis tests were performed, as the study primarily focused on descriptive data analysis.

Table 1. Patients' sociodemographic characteristics and clinical findings

Case	Age (years)	Sex	Symptoms	Clinical Findings
1	82	F	Numbness in the legs	Positive Babinski sign +/+
2	56	F	Back pain	None
3	58	F	Paraparesis	DTR +++/+++ Urinary incontinence
4	55	M	Back pain	None
5	67	F	Difficulty walking	Paraparesis with grade 3 muscle strength
6	35	M	Paraparesis	Paraparesis with grade 3 muscle strength
7	71	M	Difficulty walking	Paraparesis with grade 4 muscle strength
8	57	F	Numbness in the legs	Hypoesthesia in the legs
9	80	F	Difficulty walking	Paraparesis with grade 3 muscle strength
10	58	F	Back pain	None
11	76	M	Difficulty walking	Paraparesis with grade 3 muscle strength
12	70	F	Difficulty walking	Paraparesis with grade 2 muscle strength
13	33	F	Difficulty walking	Paraparesis with grade 4 muscle strength
14	39	F	Back pain	None

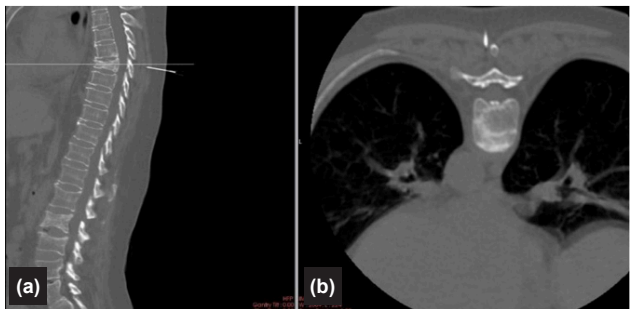

Figure 1. Case 11: A 76-year-old male with T7 vertebral metastasis. Sagittal **(a)** and axial **(b)** computed tomography images showing metal material placed in the T6-T7 interspinous space.

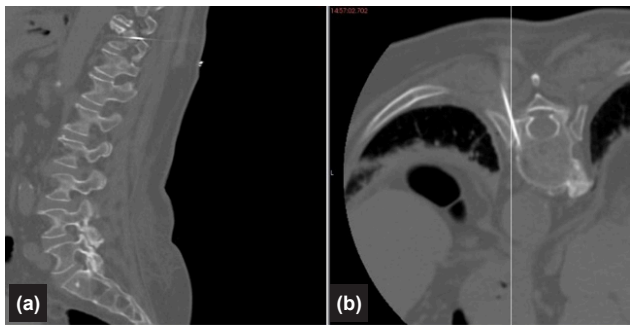

Figure 2. Case 9: Intradural meningioma at the T10 level. Metal material placed lateral to the pedicle of the T10 vertebra. Sagittal **(a)** and axial **(b)** computed tomography (CT) images.

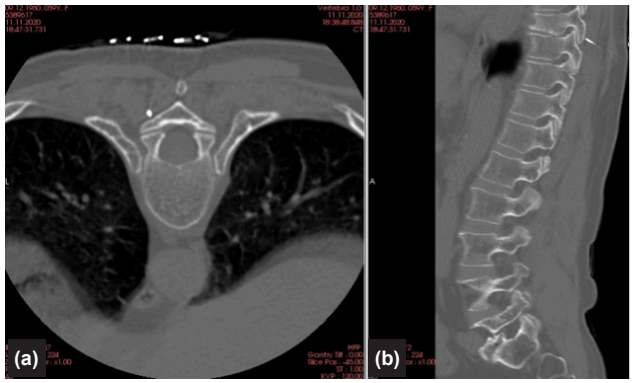

Figure 3. Case 14: A 59-year-old woman was referred to our clinic with a diagnosis of a T8 vertebral corpus tumor from another center. However, a biopsy confirmed an osteoporotic compression fracture. Sagittal **(a)** and axial **(b)** computed tomography (CT) images show metallic needle marking of the T8 vertebral corpus.

RESULTS

Computed tomography-guided spinal fiducial marker placement was performed on 14 patients between January 1, 2019 and July 30, 2020. The patients' sociodemographic characteristics and pathologies are listed in Table 1. The mean age of the patients was 61 years, with females outnumbering males (male-to-female ratio 1:2.5). Spinal metastatic tumors and meningiomas accounted for the majority of cases (71%).

Fourteen patients (five males and nine females) undergoing posterior interventions to the thoracic spine and instrumentation procedures were investigated. Metallic markers were inserted into the interspinous space with computed tomography assistance for level localization before thoracic surgery. Hyperintense metallic materials, such as injector tip needles and lumbar puncture (LP) needles, were used for better visibility on computed tomography. Marker placement was confirmed using radiology reports and 3D imaging.

Marker placement was successful in 13 cases (92.3%). In one case, although the marker was placed at the correct level, the wire inserted during surgery could not be visualized intraoperatively, necessitating fluoroscopy-guided repeat level confirmation. However, in all cases, the marker needle was successfully placed at the intended distance.

The mid-thoracic spine (T5-T8) was the most commonly marked region (seven cases), followed by the upper thoracic spine (T1-T4) in five cases and the lower thoracic spine (T9-T12) in two cases.

No complications related to needle marking were observed in any of the analyzed cases.

DISCUSSION

Avoiding wrong-level surgery in spinal procedures is crucial, as operating at the incorrect level often results in legal proceedings.[3] Determining the first thoracic vertebra from the lateral aspect during thoracic spine surgeries is challenging due to scapular shadows. Additionally, palpation of the thoracic vertebrae and spinous processes from the outside is difficult, particularly in overweight patients. Various strategies have been developed to reduce the risk of wrong-level surgery. Preoperative skin marking under magnetic resonance imaging (MRI) or spinal computed tomography guidance has been considered and attempted as a potential intraoperative level localization technique. However, MRI with a cutaneous marker can produce poor images due to artifacts. Several materials have been used for this purpose, including fatty substances, halibut oil-filled capsules, and single-use skin markers. However, most of these techniques are unreliable, as marker shifts may occur due to factors such as skin folds and obesity.[7,8] Research continues to focus on reducing the risk of level mislocalization and identifying more definitive markers. An incorrect intraoperative level typically becomes evident only after laminectomy, and in many cases, only when the dura is opened. Additional bone removal therefore necessitates a larger laminectomy. This unnecessary laminectomy can lead to postoperative pain, infection, instability, and kyphotic deformities.[9] In this study, the success rate of fiducial marker placement was 92.3%. In only one case, the guide needle's course could not be visualized, despite correct marker placement, requiring serial imaging.

Intraoperative level determination was easier and more reliable in patients who underwent preoperative computed tomography-assisted marking for thoracic spine surgeries,

including procedures for thoracic vertebral fractures, spinal infections, and spinal tumors. A reduction in the preoperative preparation time, intraoperative anesthesia duration, and intraoperative fluoroscopic imaging was observed, with no cases of mislocalization. Additionally, no symptoms or complications related to preoperative thoracic marking were reported. Radiologically, computed tomography (CT) marking not only provided a clear preoperative view of vertebral anatomy but also facilitated accurate level localization in the thoracic region. The findings suggest that preoperative thoracic CT-guided marking is a safe, reliable, and effective method for level localization in thoracic spine surgery.

CONCLUSION

The technique employed at our clinic was found to be both efficient and dependable. We propose that the placement of intraosseous metallic markers in the lamina and/or spinous processes, rather than cutaneous marking, represents a more accurate and reliable method for intraoperative localization of the target thoracic spine level. The implementation of this method has significantly reduced the likelihood of erroneous localization in our clinic. Furthermore, the use of fiducial markers for surgical incision identification has led to a notable decrease in intraoperative complications related to anesthesia. A comprehensive retrospective analysis of the procedure indicated that all patients tolerated the fiducial marking technique well, with no procedure-related complications observed.

Ethics Committee Approval: This study was approved by the The study was approved by Karadeniz Technical University Scientific Research Ethics Committee Ethics Committee (Date: 11.06.2020, Decision No: 24237859-304).

Peer-review: Externally peer-reviewed.

Authorship Contributions: Concept: A.R.G., U.Y., E.Ç.; Design: A.R.G., U.Y., E.Ç.; Supervision: A.R.G., U.Y., E.Ç.; Resource: M.O.B., M.A.; Materials: M.O.B., M.A.; Data Collection and/or Processing: M.O.B., M.A.; Analysis and/or Interpretation: M.A.; Literature Review: M.A.; Writing: M.O.B.; Critical Review: M.O.B.

Conflict of Interest: None declared.

Financial Disclosure: The author declared that this study has received no financial support.

REFERENCES

1. Mlaka J, Rapcan R, Burianek M, Rapcanova S, Gajdos M, Kocanova M, et al. Endoscopic discectomy as an effective treatment of a herniated intervertebral disc. Bratisl Lek Listy 2020;121:199–205. [CrossRef]
2. Nowitzke A, Wood M, Cooney K. Improving accuracy and reducing errors in spinal surgery--A new technique for thoracolumbar-level localization using computer-assisted image guidance. Spine J 2008:8:597–604. [CrossRef]
3. Abdullah KG, Bishop FS, Lubelski D, Steinmetz MP, Benzel EC, Mroz TE. Radiation exposure to the spine surgeon in lumbar and thoracolumbar fusions with the use of an intraoperative computed tomographic 3-dimensional imaging system. Spine (Phila Pa 1976) 2012;37:E1074–8. [CrossRef]
4. Ringel F, Stüer C, Reinke A, Preuss A, Behr M, Auer F, et al. Accuracy of robot-assisted placement of lumbar and sacral pedicle screws: A prospective randomized comparison to conventional freehand screw implantation. Spine (Phila Pa 1976) 2012;37:E496–501. [CrossRef]
5. Madaelil TP, Long JR, Wallace AN, Baker JC, Ray WZ, Santiago P, et al. Preoperative fiducial marker placement in the thoracic spine: A technical report. Spine (Phila Pa 1976) 2017;42:E624–8. [CrossRef]
6. Anaizi AN, Kalhorn C, McCullough M, Voyadzis JM, Sandhu FA. Thoracic spine localization using preoperative placement of fiducial markers and subsequent CT. A technical report. J Neurol Surg A Cent Eur Neurosurg 2015;76:66–71. [CrossRef]
7. Mody MG, Nourbakhsh A, Stahl DL, Gibbs M, Alfawareh M, Garges KJ. The prevalence of wrong level surgery among spine surgeons. Spine (Phila Pa 1976) 2008;33:194–8. [CrossRef]
8. Ul Haque M, Shufflebarger HL, O'Brien M, Macagno A. Radiation exposure during pedicle screw placement in adolescent idiopathic scoliosis: Is fluoroscopy safe? Spine (Phila Pa 1976) 2006;31:2516–20. [CrossRef]
9. Aktoklu M, Bıyık MO, Güvercin AR, Yazar U. Management of spontaneous or post-surgical spinal infections: Literature review and case series. Türk Nöroşir Derg 2024;34:53–66. [CrossRef]

ORİJİNAL ÇALIŞMA - *ÖZ*

BT kılavuzluğunda pediküler spinal iğne yerleştirme ile torasik omurga lezyonlarının preoperatif lokalizasyonunda yeni bir yöntem için tek merkez deneyimleri

AMAÇ: Torasik omurga sorunlarının tedavisinde torasik seviye lokalizasyonu diğer omurga bölgelerine göre daha zordur. Bu çalışmanın amacı torakal omurga cerrahisi öncesinde bilgisayarlı tomografi eşliğinde pediküler spinal iğne yerleşiminin güvenilirliğini kanıtlamak ve torakal omurga ve omurilik cerrahisi sırasında hata payını, ameliyat süresini ve ameliyathane radyasyon maruziyetini azaltmaktır.

GEREÇ VE YÖNTEM: Torasik omurga ve/veya omurilikle ilişkili lezyonlara posterior yaklaşım yapılan 14 hasta incelendi. Spinokatlar BT kılavuzluğunda, ilgili vertebranın pedikülüne aynı gün veya ameliyattan bir gece önce yerleştirildi. Cerrahi alan her zamanki gibi hazırlandı ve BT kılavuzluğunda ilgili torasik pediküle bir spinokat yerleştirildi.

BULGULAR: Çeşitli nedenlerle yapılan torasik bölge ameliyatlarında ameliyat öncesi BT eşliğinde işaretleme yapılan hastalarda intraoperatif seviye lokalizasyonu daha güvenilir ve kolaydı. Preoperatif hazırlık ve intraoperatif anestezi süreleri kısaldı, intraoperatif çekilen floroskopik görüntü sayısı azaldı ve spinal yanlış lokalizasyonlar gözlenmedi.

SONUÇ: Elde edilen sonuçlar, her türlü torasik cerrahi öncesinde preoperatif BT ile seviye lokalizasyonunun yapılmasının torasik omurga cerrahisi için güvenli, güvenilir ve faydalı bir yöntem olduğunu göstermektedir.

Anahtar sözcükler: Torasik vertebra; preoperatif prosedürler; girişimsel radyografi.

Ulus Travma Acil Cerrahi Derg 2025;31(4):371-374 DOI: 10.14744/tjtes.2025.82844