EXPERIMENTAL STUDY

Effects of oral administration of red ginseng on liver ischemia-reperfusion injury in rats

Mert Çöl,[1] Salih Tuncal,[2] Mevlüt Recep Pekcici,[2] Koray Koşmaz,[2] Saygın Altıner,[3] Mehmet Şeneş,[4] Gül Kırtıl,[4] Neslihan Durmaz,[5] Mehmet Alpaslan Gönültaş,[6] Sema Hücümenoğlu[6]

[1]Department of Surgical Oncology, Ankara Training and Research Hospital, Ankara-*Türkiye*
[2]Department of General Surgery, Ankara Training and Research Hospital, Ankara-*Türkiye*
[3]Department of General Surgery, Gazi University Faculty of Medicine, Ankara-*Türkiye*
[4]Department of Biochemistry, Ankara Training and Research Hospital, Ankara-*Türkiye*
[5]Department of Pathology, Kırşehir Training and Research Hospital, Kırşehir-*Türkiye*
[6]Department of Pathology Ankara Training and Research Hospital, Ankara-*Türkiye*

ABSTRACT

BACKGROUND: This study investigated the protective effect of red ginseng (RG) on oxidative stress and pathological changes in an experimental liver ischemia-reperfusion injury (IRI) model, using both biochemical and histopathological evaluations.

METHODS: Fifty female Wistar-Albino rats were used, with body weights ranging from 174 g to 232 g. The animals were randomly divided into five groups, each consisting of 10 rats. After laparotomy in Group I, the hepatic pedicle was mobilized, no further procedures were performed, and tissue and blood samples were collected. In Group II, ischemia was induced by clamping the hepatic artery and portal vein for 60 minutes following laparotomy. Tissue and blood samples were collected via reoperation at 90 minutes after reperfusion, without any drug administration. In Group III, ischemia was similarly induced by clamping the hepatic artery and portal vein for 60 minutes after laparotomy. Tissue and blood samples were collected via reoperation at the 48th hour after reperfusion, again without any drug administration. In Group IV, RG was administered to the rats at a dose of 5 mg/kg/day via orogastric tube for three days preoperatively. This was followed by laparotomy and induction of ischemia through clamping of the hepatic artery and portal vein for 60 minutes. Tissue and blood samples were collected via reoperation at 90 minutes after reperfusion, with no drug administered postoperatively. In Group V, RG was administered at a dose of 5 mg/kg/day via orogastric tube for three days preoperatively, followed by laparotomy and induction of ischemia by clamping the hepatic artery and portal vein for 60 minutes. After reperfusion, the rats received RG at the same dose for two days postoperatively via orogastric tube, and tissue and blood samples were collected via reoperation at the 48th hour.

RESULTS: Red ginseng did not show a significant histopathological effect; however, differences were observed in biochemical parameters.

CONCLUSION: Red ginseng may have protective effects against ischemia-reperfusion injury.

Keywords: Ischemia-reperfusion injury; liver; red ginseng.

Cite this article as: Çöl M, Tuncal S, Pekcici MR, Koşmaz K, Altıner S, Şeneş M, et al. Effects of oral administration of red ginseng on liver ischemia-reperfusion injury in rats. Ulus Travma Acil Cerrahi Derg 2025;31:411-417.

Address for correspondence: Mert Çöl
Department of Surgical Oncology, Ankara Training and Research Hospital, Ankara, Türkiye
E-mail: mdmertcol@gmail.com

Ulus Travma Acil Cerrahi Derg 2025;31(5):411-417 DOI: 10.14744/tjtes.2025.66228
Submitted: 27.12.2024 Revised: 18.02.2025 Accepted: 01.03.2025 Published: 05.05.2025
OPEN ACCESS This is an open access article under the CC BY-NC license (http://creativecommons.org/licenses/by-nc/4.0/).

INTRODUCTION

Ischemia-reperfusion injury (IRI) refers to cellular damage in organs caused by reduced tissue oxygenation due to hypoxia, followed by further injury upon tissue reoxygenation.[1] Ischemia arises when impaired tissue perfusion prevents adequate oxygen delivery to meet cellular demands, leading to the accumulation of toxic metabolites and, ultimately, cell death.[2,3] Liver ischemia-reperfusion injury is a major concern in procedures such as liver resection, liver transplantation, trauma surgery, and in cases of shock. Additionally, conditions such as chemotherapy, burns, trauma, pancreatitis, and compartment syndrome can also cause liver IRI.[4-6] This pathology can occur in both surgical and non-surgical settings and is associated with increased morbidity and mortality.

Ginseng has long held cultural and medicinal importance, particularly in Asian countries. Numerous studies have highlighted the therapeutic benefits of red ginseng (RG), including its antioxidant, anti-inflammatory, and antihyperlipidemic properties.[7-9] The bioactive compounds of ginseng, known as ginsenosides, are triterpene saponins, with key examples including Rb1, Rb2, Rc, Rd, Re, and Rg1. These ginsenosides interact with membrane ion channels and both extracellular and intracellular receptors, resulting in transcriptional-level changes. They exhibit diverse bioactivities, including anti-inflammatory, antioxidant, antibacterial, antiviral, and antifungal effects. Ginseng has been shown to effectively scavenge free radicals and enhance the activity of antioxidant enzymes such as glutathione peroxidase and superoxide dismutase. Furthermore, its active components stimulate nitric oxide production while inhibiting the generation of reactive oxygen species.[10-12]

Our aim in this study is to investigate the biochemical and histopathological effects of RG, a substance known for its significant antioxidant properties and studied extensively over the years, on oxidative stress and pathological changes in an experimental model of liver IRI. We also aim to contribute to the existing body of knowledge on this subject.

MATERIALS AND METHODS

Ethics

The study, titled "Effects of Oral Administration of Red Ginseng on Liver Ischemia-Reperfusion Injury in Rats", was conducted at the General Surgery Clinic of Ankara Training and Research Hospital. It was approved by the hospital's ethics committee (approval number: 0066/26.07.2021) and carried out in accordance with the principles of the Declaration of Helsinki.

Materials

The Korean RG extract used in the study was obtained from Dae Han Red Ginseng Promotion Co. Ltd. The extract contains 4 mg of combined ginsenosides (Rg1, Rb1, and Rg3) per gram.

Animals

The experimental animals were female Wistar-Albino rats, sourced from the Ankara Training and Research Hospital Experimental Animals Research Laboratory. A total of 50 rats were used, with body weights ranging from 174 g to 232 g.

All rats were fed standard laboratory chow until the day of the experiment. They were housed under standard laboratory conditions, including a 12-hour light/dark cycle and ambient temperatures maintained between 18-20°C. To allow for adaptation, the rats were placed in cages seven days before the experiment. The rats were grouped into cages of 10, and each was individually identified by numbering their tails.

Study Groups

Anesthesia was induced using 40 mg/kg ketamine (Ketalar, Parke-Davis) and 5 mg/kg xylazine hydrochloride (Rompun, Bayer). Following anesthesia, the surgical area was shaved and disinfected with povidone-iodine. Sterility was maintained throughout the procedure. All surgical procedures were performed by a single surgeon (Fig. 1).

After anesthesia, a midline laparotomy, approximately 3-4 cm in length, was performed between the xiphoid process and the pubis. When the liver was examined after laparotomy, tissue samples were collected from the most ischemic areas.

Group I (Sham Group): No procedure other than laparotomy was performed. Tissue and blood samples were collected.

Group II (Control Group 1): Following laparotomy, the hepatic artery and portal vein were clamped (Fig. 2), and the clamps were kept in place for 60 minutes. After this period, reperfusion was achieved by releasing the clamps. Ninety minutes after reperfusion, a second operation was performed without administering any medication, and tissue and blood samples were collected.



Figure 1. Preparation of rats for surgery.

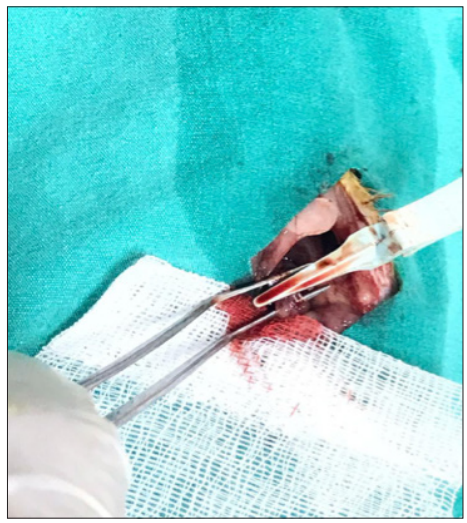

Figure 2. Clamping of the hepatic artery and portal vein.

Group III (Control Group 2): After laparotomy, the hepatic artery and portal vein were clamped, and the clamps were kept in place for 60 minutes. After this period, reperfusion was achieved by releasing the clamps. Forty-eight hours after reperfusion, a second operation was performed without administering any medication, and tissue and blood samples were collected.

Group IV (Preoperative RG Group): Rats received RG at a dose of 5 mg/kg/day via orogastric tube for three days prior to surgery. After laparotomy, the hepatic artery and portal vein were clamped, and the clamps were kept in place for 60 minutes. After this period, reperfusion was achieved by releasing the clamps. Ninety minutes after reperfusion, a second operation was performed without administering any medication, and tissue and blood samples were collected.

Group V: Rats were given RG at a dose of 5 mg/kg/day via orogastric tube for three days in the preoperative period, followed by laparotomy. After laparotomy, the hepatic artery and portal vein were clamped, and the clamps were kept in place for 60 minutes. After this period, reperfusion was achieved by releasing the clamps. In the postoperative period, rats in this group received RG at the same dose (5 mg/kg via orogastric tube) for two additional days. Reoperation was performed 48 hours after reperfusion, and tissue and blood samples were collected.

Analgesia for experimental animals requiring postoperative monitoring was provided using 0.02 mg/kg fentanyl (Fentanyl, Belgium). Animals that did not require monitoring were sacrificed by cervical dislocation after the necessary samples were collected.

To investigate the effects of preoperatively administered RG, the Sham group, Group 2, and Group 4 were first analyzed individually, and then Group 2 and Group 4 were compared with each other.

To evaluate the effects of RG administered both preoperatively and postoperatively, the Sham group, Group 3, and Group 5 were analyzed individually, followed by a comparison between Group 3 and Group 5.

To compare the effects of preoperative RG administration versus combined preoperative and postoperative RG administration, Group 4 and Group 5 were compared.

In our study, malondialdehyde (MDA)/protein, total sulfhydryl (SH)/protein, total antioxidant status (TAS)/protein, and total oxidant status (TOS)/protein levels were used to assess oxidative load. Biochemical parameters were evaluated in the blood, and histopathological assessment of sinusoidal congestion, vacuolization, and necrosis severity was performed using light microscopy.

Statistical Analysis

All analyses were performed using SPSS version 21.0. Categorical variables were summarized as numbers and percentages, while continuous numerical variables were presented as mean ± standard deviation and median (min - max) values. The Pearson Chi-square test was used to compare categorical variables between groups. The Shapiro-Wilk test was applied to assess the normality of continuous numerical variables. Since the numerical variables did not follow a normal distribution, the Mann-Whitney U test was used for comparisons between two independent groups. A p value of less than 0.05 was considered statistically significant.

RESULTS

Vacuolization and necrosis were not observed in any of the groups. There was no statistically significant difference in the level of sinusoidal congestion between the Sham group, Group 2, and Group 4 ($p>0.05$), as determined by the Pearson Chi-square test. Compared to the Sham group, alkaline phosphatase (ALP) and alanine aminotransferase (ALT) levels were found to be significantly higher in both Group 2 and Group 4 ($p<0.05$). Additionally, lactate dehydrogenase (LDH) and SH values were significantly higher in Group 4 compared to the Sham group ($p<0.05$). Compared to Group 2, LDH levels were found to be significantly higher in Group 4 ($p=0.009$) (Table 1). There was no statistically significant difference in the level of sinusoidal congestion between the Sham group, Group 3, and Group 5 (Pearson Chi-square test).

When compared to the Sham group, ALT, AST, and MDA levels were significantly higher in Group 3 ($p<0.05$). In Group 5, ALP levels were significantly lower ($p<0.001$), while AST and SH levels were significantly higher compared to the Sham group ($p<0.05$). Compared to Group 3, ALT, AST, and MDA levels were significantly lower in Group 5 ($p<0.05$) (Table 2). There was no statistically significant difference in sinusoidal

Table 1. Comparison of laboratory parameters between the Sham group, Group 2, and Group 4

Parameters	Sham Group (n=10)		Group 2 (n=10)		Group 4 (n=10)		p[1]	p[2]	p[3]
	Mean±SD	Median (Min-Max)	Mean±SD	Median (Min-Max)	Mean±SD	Median (Min-Max)			
ALP (U/L)	163.83±35.65	155 (135-230)	177.13±49.52	189.5 (111-238)	151.7±58.04	150 (92-300)	0.950	0.368	0.237
ALT (U/L)	50.83±18.93	43 (39-88)	114.5±32.62	111 (62-157)	99.6±29.1	103.5 (52-140)	0.001	0.003	0.460
AST (U/L)	105.83±7.44	105.5 (96-114)	262.75±120.23	228.5 (139-506)	231.5±80.74	226.5 (142-373)	0.001	<0.001	0.696
LDH (U/L)	812.67±300.6	688.5 (466-1246)	675.25±434.09	584 (69-1348)	1285.4±443.75	1211.5 (782-2253)	0.345	0.022	0.009
T. BiL (mg/dL)	0.04±0.01	0.04 (0.02-0.06)	0.04±0.02	0.03 (0.01-0.07)	0.04±0.02	0.03 (0.02-0.07)	0.573	0.792	0.762
TAS (µmol/g protein)	0.32±0.11	0.29 (0.23-0.53)	0.3±0.11	0.26 (0.14-0.5)	0.35±0.09	0.32 (0.23-0.51)	0.607	0.635	0.156
TOS (µmol/g protein)	9.02±4.49	8.24 (3.22-15.51)	11.06±5.85	8.21 (5.16-23.32)	7.67±1.65	7.68 (5.55-10.35)	0.689	0.713	0.278
SH (µmol/g protein)	168.74±27.01	177.82) (114.96-189.6	214.03±59.77	206.78 (121.74-325.23)	196.46±10.31	197.43 (183.5-212.93)	0.113	0.002	0.661
MDA (nmol/g protein)	311.22±146.21	257.27 (186.72-580.54)	285.69±72.19	296.07 (182.46-381.76)	286.68±92.04	259.24 1.0 (216.68-530.3)	0.875	0.720	

p[1]: Sham group vs. Group 2, p[2]: Sham group vs. Group 4, p[3]: Group 2 vs. Group 4. Mann-Whitney U test was used for all comparisons.

Table 2. Comparison of laboratory parameters between the Sham group, Group 3, and Group 5

Parameters	Sham Group (n=10)		Group 3 (n=10)		Group 5 (n=10)		p[1]	p[2]	p[3]
	Mean±SD	Median (Min-Max)	Mean±SD	Median (Min-Max)	Mean±SD	Median (Min-Max)			
ALP (U/L)	163.83±35.65	155 (135-230)	111.6±82.34	68 (56-249)	79.1±20.56	82 (44-115)	0.126	<0.001	1.0
ALT (U/L)	50.83±18.93	43 (39-88)	151.4±145.28	92 (76-411)	80.9±75.42	48.5 (32-227)	0.017	0.428	0.040
AST (U/L)	105.83±7.44	105.5 (96-114)	732.6±642.66	469 (368-1871)	219.7±149.06	158.5 (117-549)	0.004	<0.001	0.013
LDH (U/L)	812.67±300.6	688.5 (466-1246)	972±429.53	877 (388-1470)	1442.1±1153.56	1061 (388-3706)	0.429	0.313	0.768
T. BiL (mg/dL)	0.04±0.01	0.04 (0.02-0.06)	0.03±0.04	0.01 (0-0.09)	0.06±0.01	0.07 (0.04-0.08)	0.329	0.016	0.099
TAS (µmol/g protein)	0.32±0.11	0.29 (0.23-0.53)	0.31±0.17	0.23 (0.18-0.58)	0.32±0.12	0.32 (0.13-0.47)	0.662	1.0	0.768
TOS (µmol/g protein)	9.02±4.49	8.24 (3.22-15.51)	11.1±6.65	7.94 (6.55-22.46)	9.76±3.59	8.59 (6.29-18.5)	0.792	0.635	0.953
SH (µmol/g protein)	168.74±27.01	177.82 (114.96-189.6)	190.76±38.78	181.65 (139.61-238.63)	205.1±24.23	196.6 (178.5-257.81)	0.429	0.003	0.440
MDA (nmol/g protein)	311.22±146.21	257.27 (186.72-580.54)	613.65±183.74	547.19 (444.02-819.79)	295.81±150.65	235.81 (198.76-699.42)	0.030	0.792	0.005

p[1]: Sham group vs. Group 2, p[2]: Sham group vs. Group 4, p[3]: Group 2 vs. Group 4. Mann-Whitney U test was used for all comparisons.

congestion between Group 4 and Group 5 (Pearson Chi-square test). However, when compared to Group 4, Group 5 showed significantly lower ALP and AST levels ($p<0.05$), and significantly higher total bilirubin levels ($p=0.015$) (Table 3).

DISCUSSION

In the literature review conducted for this study, we were unable to identify a standardized dosage or duration of RG administration or liver ischemia.[13-19]

In our study, we chose to apply hepatic ischemia for 60 minutes, based on protocols used in studies by Serafin et al.,[20] Ünal et al.,[21] and by Şahin et al.[22]

Additionally, we administered RG at a dose of 5 mg/kg, following the study by Song et al.,[23] which investigated the neuroprotective effects of ginsenosides in rats after spinal cord injury.

When comparing our results with those in the literature, our findings are as follows:

In studies by Lin et al.[24] and Tao et al.,[25] which examined the effects of ginsenoside Rg1 on liver IRI, Rg1 pretreatment sig-

Table 3. Comparison of laboratory parameters between Group 4 and Group 5

Parameters	Mean±SD	Median (Min-Max)	Mean±SD	Median (Min-Max)	p
ALP (U/L)	151.7±58.04	150 (92-300)	79.1±20.56	82 (44-115)	<0.001
ALT (U/L)	99.6±29.1	103.5 (52-140)	80.9±75.42	48.5 (32-227)	0.029
AST (U/L)	231.5±80.74	226.5 (142-373)	219.7±149.06	158.5 (117-549)	0.218
LDH (U/L)	1285.4±443.75	1211.5 (782-2253)	1442.1±1153.56	1061 (388-3706)	0.481
T. BiL (mg/dL)	0.04±0.02	0.03 (0.02-0.07)	0.06±0.01	0.07 (0.04-0.08)	0.015
TAS (µmol/g protein)	0.35±0.09	0.32 (0.23-0.51)	0.32±0.12	0.32 (0.13-0.47)	0.481
TOS (µmol/g protein)	7.67±1.65	7.68 (5.55-10.35)	9.76±3.59	8.59 (6.29-18.5)	0.123
SH (µmol/g protein)	196.46±10.31	197.43 (183.5-212.93)	205.1±24.23	196.6 (178.5-257.81)	0.631
MDA (nmol/g protein)	286.68±92.04	259.24 (216.68-530.3)	295.81±150.65	235.81 (198.76-699.42)	0.481

Mann-Whitney U test was used for all comparisons.

nificantly reduced liver injury, improved AST and ALT levels, and did not cause significant drug-induced liver damage. In contrast, we did not observe similar outcomes in our study. However, we found that combined preoperative and postoperative RG administration resulted in a statistically significant improvement in ALP and AST levels compared to preoperative administration alone.

Kwon et al.,[26] in their study investigating the effects of Korean red ginseng on morphological changes and liver function following 70% hepatectomy in rats, reported a significant improvement in AST and ALT levels in the RG-treated groups compared to the control groups. Although a decrease in LDH levels was also observed in the RG-treated groups, it was not statistically significant. These findings are consistent with the reduction in serum AST and ALT levels we observed when comparing Group 5 with Group 3 in our study, as well as the reduction in serum AST levels when comparing Group 5 with Group 4. However, no significant difference in LDH levels was found between the groups in our study.

Lee et al.,[27] in a study examining the protective effects of RG against alcoholic fatty liver in rats, demonstrated significant histopathological protection provided by RG, In contrast, our study did not reveal any significant histopathological differences between groups.

The limitations of our study include its single-center design, a limited number of subjects, and the absence of standardized guidelines in the literature regarding the optimal RG dose and hepatic ischemia duration.

In our study, unlike some findings reported in the literature, we did not observe any significant histopathological differences between the groups. However, the biochemical results, particularly the comparison between Group 5 and Group 3, were consistent with previous studies. Based on the evaluation of RG in liver IRI using both biochemical and histopathological parameters, our findings that RG may help reduce IRI by lowering oxidative stress through its antioxidant properties, in line with the literature. Considering the study's limitations, we believe that further research is necessary to establish standardized experimental models and to expand the knowledge base on this topic.

CONCLUSION

In this study investigating the effects of RG on liver IRI, we found that RG did not produce significant histopathological changes, but it did result in notable biochemical differences. It is believed that further research is needed on this subject, as it represents an important finding that requires investigation in future studies.

We also believe that the protective effect of RG against liver damage will be better understood as more comprehensive studies are added to the literature in the future.

Ethics Committee Approval: This study was approved by the Ankara Training and Research Hospital Ethics Committee (Date: 26.07.2021, Decision No: 0066).

Peer-review: Externally peer-reviewed.

Authorship Contributions: Concept: M.Ç., S.T., M.R.P., K.K., S.A., M.Ş., G.K., N.D., M.A.G., S.H.; Design: M.Ç., S.T., M.R.P., K.K., S.A., M.Ş., G.K., N.D., M.A.G., S.H.; Supervision: M.Ç., S.T., M.R.P., K.K., S.A., M.Ş., G.K., N.D., M.A.G., S.H.; Resource: M.Ç., S.T., M.R.P., K.K., S.A., M.Ş., G.K., N.D., M.A.G., S.H.; Materials: M.Ç., S.T., M.R.P., K.K., S.A., M.Ş., G.K., N.D., M.A.G., S.H.; Data collection and/or processing: M.Ç., S.T.; Analysis and/or interpretation: M.Ç.; Literature review: M.Ç.; Writing: M.Ç.; Critical review: M.Ç., S.T.

Conflict of Interest: None declared.

Financial Disclosure: The author declared that this study has received no financial support.

REFERENCES

1. Papadopoulos D, Siempis T, Theodorakou E, Tsoulfas G. Hepatic ischemia and reperfusion injury and trauma: Current concepts. Arch Trauma Res. 2013;2:63–70. [CrossRef]
2. Granger DN, Kvietys PR. Reperfusion injury and reactive oxygen species: The evolution of a concept. Redox Biol 2015;6:524–51. [CrossRef]
3. Kalogeris T, Baines CP, Krenz M, Korthuis RJ. Ischemia/reperfusion. Compr Physiol 2016;7:113–70. [CrossRef]
4. Nastos C, Kalimeris K, Papoutsidakis N, Tasoulis MK, Lykoudis PM, Theodoraki K, et al. Global consequences of liver ischemia/reperfusion injury. Oxid Med Cell Longev 2014;2014:906965. [CrossRef]
5. Horváth B, Magid L, Mukhopadhyay P, Bátkai S, Rajesh M, Park O, et al. A new cannabinoid CB2 receptor agonist HU-910 attenuates oxidative stress, inflammation and cell death associated with hepatic ischaemia/reperfusion injury. Br J Pharmacol 2012;165:2462–78. [CrossRef]
6. Eltzschig HK, Eckle T. Ischemia and reperfusion--from mechanism to translation. Nat Med 2011;17:1391–401. [CrossRef]
7. So SH, Lee JW, Kim YS, Hyun SH, Han CK. Red ginseng monograph. J Ginseng Res 2018;42:549–61. [CrossRef]
8. Hong JT, Lee MJ, Yoon SJ, Shin SP, Bang CS, Baik GH, et al. Effect of Korea red ginseng on nonalcoholic fatty liver disease: An association of gut microbiota with liver function. J Ginseng Res 2021;45:316–24. [CrossRef]
9. Bang CS, Hong SH, Suk KT, Kim JB, Han SH, Sung H, et al. Effects of Korean Red Ginseng (Panax ginseng), urushiol (Rhus vernicifera Stokes), and probiotics (Lactobacillus rhamnosus R0011 and Lactobacillus acidophilus R0052) on the gut–liver axis of alcoholic liver disease. J Ginseng Res 2014;38:167–72. [CrossRef]
10. Ratan ZA, Haidere MF, Hong YH, Park SH, Lee JO, Lee J, et al. Pharmacological potential of ginseng and its major component ginsenosides. J Ginseng Res 2021;45:199–210. [CrossRef]
11. Chen F, Huang G. Antioxidant activity of polysaccharides from different sources of ginseng. Int J Biol Macromol 2019;125:906–8. [CrossRef]
12. Park H, Lee M, Kim KT, Park E, Paik HD. Antioxidant and antigenotoxic effect of dairy products supplemented with red ginseng extract. J Dairy Sci 2018;101:8702–10. [CrossRef]
13. Koşmaz K, Durhan A, Süleyman M, Ünal Y, Bostancı MT, Yiğit Haskaraca T, et al. The effect of Ankaferd blood stopper on liver damage in experimental obstructive jaundice. Turk J Med Sci 2021;51:1472–80. [CrossRef]
14. Park HK, Kang SW, Park MS. Hesperidin ameliorates hepatic ischemia-reperfusion injury in sprague-dawley rats. Transplant Proc 2019;51:2828–32. [CrossRef]
15. Karatzas T, Neri AA, Baibaki ME, Dontas IA. Rodent models of hepatic ischemia-reperfusion injury: Time and percentage-related pathophysiological mechanisms. J Surg Res 2014;191:399–412. [CrossRef]
16. Bhattacharya SK, Mitra SK. Anxiolytic activity of Panax ginseng roots: An experimental study. J Ethnopharmacol 1991;34:87–92. [CrossRef]
17. Serracino-Inglott F, Habib NA, Mathie RT. Hepatic ischemia-reperfusion injury. Am J Surg 2001;181:160–6. [CrossRef]
18. Kim TH, Lee SM. The effects of ginseng total saponin, panaxadiol and panaxatriol on ischemia/reperfusion injury in isolated rat heart. Food Chem Toxicol 2010;48:1516–20. [CrossRef]
19. Wang GL, He ZM, Zhu HY, Gao YG, Zhao Y, Yang H, et al. Involvement of serotonergic, noradrenergic and dopaminergic systems in the antidepressant-like effect of ginsenoside Rb1, a major active ingredient of Panax ginseng C.A. Meyer. J Ethnopharmacol 2017;204:118–24. [CrossRef]
20. Serafín A, Roselló-Catafau J, Prats N, Xaus C, Gelpí E, Peralta C. Ischemic preconditioning increases the tolerance of fatty liver to hepatic ischemia-reperfusion injury in the rat. Am J Pathol 2002;161:587–601. [CrossRef]
21. Ünal Y, Küçük B, Tuncal S, Koşmaz K, Çavuşoğlu NT, Kısmet K, et al. Assessment of the effect of calcium dobesilate in experimental liver ischemia-reperfusion injury. Ulus Travma Acil Cerrahi Derg 2018;24:391–7. [CrossRef]
22. Sahin T, Begeç Z, Toprak Hİ, Polat A, Vardi N, Yücel A, et al. The effects of dexmedetomidine on liver ischemia-reperfusion injury in rats. J Surg Res 2013;183:385–90. [CrossRef]
23. Song YX, Jin CY, Zeng ZY, Wang B, Zhang JQ. Study on the mechanism underlying neuroprotective effect of ginsenosides in rats after spinal cord injury. Hainan Med J 2009;20:6-9.
24. Lin J, Huang HF, Yang SK, Duan J, Qu SM, Yuan B, et al. The effect of Ginsenoside Rg1 in hepatic ischemia reperfusion (I/R) injury ameliorates ischemia-reperfusion-induced liver injury by inhibiting apoptosis. Biomed Pharmacother 2020;129:110398. [CrossRef]
25. Tao T, Chen F, Bo L, Xie Q, Yi W, Zou Y, et al. Ginsenoside Rg1 protects mouse liver against ischemia-reperfusion injury through anti-inflammatory and anti-apoptosis properties. J Surg Res 2014;191:231–8. Erratum in: J Surg Res 2014;191:250. [CrossRef]
26. Kwon YS, Jang KH. The effect of Korean red ginseng on liver regeneration after 70% hepatectomy in rats. J Vet Med Sci 2004;66:193–5. [CrossRef]
27. Lee HJ, Ok HM, Kwon O. Protective effects of Korean Red Ginseng against alcohol-induced fatty liver in rats. Molecules 2015;20:11604–16. [CrossRef]

DENEYSEL ÇALIŞMA - *ÖZ*

Oral yolla verilen red ginsengin sıçanlarda karaciğer iskemi reperfüzyon hasarı üzerine olan etkileri

AMAÇ: Bu çalışmada, deneysel karaciğer İRH'sinde RG'nin oksidatif stres ve patolojik değişiklikler üzerindeki koruyucu etkisi biyokimyasal ve histopatolojik olarak araştırıldı.

GEREÇ VE YÖNTEM: Çalışmada, ağırlıkları 174 g ile 232 g arasında değişen 50 adet dişi Wistar-Albino sıçan kullanıldı. Deney hayvanları randomize şekilde, her biri 10 sıçandan oluşan 5 gruba ayrıldı. Grup I'te, laparotomi yapıldıktan sonra hepatik pedikül mobilize edildi, başka ek işlem uygulanmadı ve doku ile kan örnekleri alındı. Grup II'de, laparotomi sonrası hepatik arter ve portal ven 60 dakika süreyle klemplenerek iskemi oluşturuldu. Reperfüzyon sonrası herhangi bir ilaç verilmeden 90. dakikada reopere edilerek doku ve kan örnekleri alındı. Grup III'te, laparotomi sonrası hepatik arter ve portal ven 60 dakika süreyle klemplenerek iskemi oluşturuldu. Reperfüzyon sonrası herhangi bir ilaç verilmeden 48. saatte reopere edilerek doku ve kan örnekleri alındı. Grup IV'te, sıçanlara preoperatif dönemde 3 gün süreyle orogastrik sonda yoluyla 5 mg/kg/gün dozunda RG verildi. Ardından laparotomi yapıldı ve hepatik arter ile portal ven 60 dakika süreyle klemplenerek iskemi oluşturuldu. Reperfüzyon sonrası herhangi bir ilaç verilmeden 90. dakikada reopere edilerek doku ve kan örnekleri alındı. Grup V'te ise sıçanlara preoperatif dönemde 3 gün süreyle orogastrik sonda yoluyla 5 mg/kg/gün dozunda RG verildi. Ardından laparotomi yapıldı, hepatik arter ve portal ven 60 dakika süreyle klemplenerek iskemi oluşturuldu. Reperfüzyon sonrası, bu gruptaki sıçanlara postoperatif dönemde 2 gün boyunca orogastrik sonda yoluyla 5 mg/kg/gün dozunda RG verilmeye devam edildi ve 48. saatte reopere edilerek doku ve kan örnekleri alındı.

BULGULAR: RG'nin histopatolojik olarak anlamlı bir etkisi bulunmadı; ancak biyokimyasal parametrelerde farklılıklar gözlendi.

SONUÇ: RG'nin, iskemi-reperfüzyon hasarı üzerinde koruyucu etkilerinin olabileceği saptandı.

Anahtar sözcükler: İskemi-reperfüzyon hasarı; karaciğer; kırmızı ginseng.

Ulus Travma Acil Cerrahi Derg 2025;31(5):411-417 DOI: 10.14744/tjtes.2025.66228