EXPERIMENTAL STUDY

Protective effects of KML29 in intestinal ischemia-reperfusion injury: An experimental study

İbrahim Çaltekin,[1] Ali Aygün,[1] Adem Köksal,[1] Emin Kaymak,[2] Adem Tokpınar,[3] Mahmud Mustafa Ozkut[4]

[1]Department of Emergency Medicine, Ordu University Faculty of Medicine, Ordu-*Türkiye*
[2]Department of Histology and Embryology, Yozgat Bozok University Faculty of Medicine, Yozgat-*Türkiye*
[3]Department of Anatomy, Ordu University Faculty of Medicine, Ordu-*Türkiye*
[4]Department of Histology and Embryology, Afyonkarahisar Health Sciences University Faculty of Medicine, Afyonkarahisar-*Türkiye*

ABSTRACT

BACKGROUND: Acute mesenteric ischemia (AMI) is a potentially fatal vascular emergency that results in tissue damage due to ischemia-reperfusion injury (IRI) and is difficult to diagnose and treat in its early stages. Monoacylglycerol lipase inhibitors have demonstrated protective effects against ischemia-reperfusion injury due to their antioxidant and anti-inflammatory properties. This study aimed to evaluate the effects of KML29, a potent and selective monoacylglycerol lipase inhibitor, on intestinal IRI.

METHODS: Thirty-two female Wistar albino rats were divided into four groups: Group 1 – Sham; Group 2 – Ischemia/Reperfusion (IR); Group 3 – IR + KML29 (2 mg/kg); and Group 4 – IR + KML29 (10 mg/kg). Intestinal ischemia-reperfusion was induced by occluding the superior mesenteric artery for 45 minutes, followed by 60 minutes of reperfusion. KML29 was administered intraperitoneally to Groups 3 and 4 at doses of 2 mg/kg and 10 mg/kg, respectively, 30 minutes prior to surgery. Intestinal IRI was evaluated using histopathological and biochemical parameters.

RESULTS: Treatment with 10 mg/kg KML29 was associated with improved histopathological findings in the IR group (p=0.0001). Elevated levels of nuclear factor kappa B (NF-kB), tumor necrosis factor-alpha (TNF-α), interleukin-1 beta (IL-1β), and transforming growth factor-beta 1 (TGF-β1) observed in the IR group were significantly reduced following administration of 10 mg/kg KML29 (p=0.0001). Additionally, treatment with both 2 mg/kg and 10 mg/kg doses of KML29 significantly reduced the number of apoptotic cells in the IR group (p=0.0001).

CONCLUSION: In conclusion, this study demonstrated that treatment with both doses of KML29 (2.5 mg/kg and 10 mg/kg) significantly reduced the number of apoptotic cells and inflammatory markers, and improved histopathological findings in the intestinal tissues of rats subjected to IR. With its anti-inflammatory and anti-apoptotic properties, KML29 may represent a novel therapeutic option for the treatment of mesenteric ischemia.

Keywords: Intestinal ischemia-reperfusion injury; KML29; monoacylglycerol lipase inhibitor.

INTRODUCTION

Acute mesenteric ischemia (AMI) is a rare but serious condition that is difficult to diagnose and treat in its early stages. [1] It is a vascular abdominal emergency with a high mortality rate (60-80%), primarily due to delayed diagnosis, which often occurs after intestinal necrosis has already developed.[2] While AMI is most commonly caused by embolism of the superior mesenteric artery (SMA), it can also result from mesenteric arterial thrombosis, mesenteric venous thrombosis, or non-

Cite this article as: Çaltekin İ, Aygün A, Köksal A, Kaymak E, Tokpınar A, Ozkut MM. Protective effects of KML29 in intestinal ischemia-reperfusion injury: An experimental study. Ulus Travma Acil Cerrahi Derg 2025;31:418-424.

Address for correspondence: Ali Aygun
Department of Emergency Medicine, Ordu University Faculty of Medicine, Ordu-Türkiye
E-mail: dr_aliaygun@hotmail.com

Ulus Travma Acil Cerrahi Derg 2025;31(5):418-424 DOI: 10.14744/tjtes.2025.72686
Submitted: 09.12.2024 Revised: 07.03.2025 Accepted: 10.03.2025 Published: 05.05.2025
OPEN ACCESS This is an open access article under the CC BY-NC license (http://creativecommons.org/licenses/by-nc/4.0/).

occlusive mesenteric ischemia.[1] The reduction in blood flow to the bowel leads to ischemic injury in the affected bowel segment. Following reperfusion, certain cellular mediators are released, causing additional damage to previously ischemic tissue. In a study involving reperfusion after two hours of intestinal ischemia, it was demonstrated that mucosal lesions developed primarily after the reperfusion phase.[3] Mesenteric ischemia/reperfusion (I/R) is a condition that can also occur secondary to abdominal aortic aneurysm, small intestine transplantation, septic shock, hemorrhagic shock, and burns.[4] After reperfusion, the intestine often fails to fully regain its fluid absorption capacity, leading to fluid loss from the intestinal lumen. Another significant concern in intestinal ischemia/reperfusion is bacterial translocation.[5] As a result, there has been a growing number of studies in recent years aimed at mitigating mesenteric ischemia-reperfusion injury, with many therapeutic agents being investigated for their potential to reduce associated morbidity and mortality.[6-8] Following reperfusion, cytokines, primarily tumor necrosis factor-alpha (TNF-α) and interleukin-1 (IL-1), are produced by macrophages to promote polymorphonuclear leukocyte (PMNL) production and chemotaxis. These cytokine levels are commonly used as indicators to assess the extent of damage.

Cannabinoids are biologically active compounds found in the Cannabis sativa plant and are also endogenously synthesized. The endocannabinoid system (ECS) was first identified in the central nervous system and was later found to be expressed throughout the body.[9] Endocannabinoids have been shown to possess anti-inflammatory and antioxidant properties.[10,11] One such endocannabinoid, 2-arachidonoylglycerol (2-AG), is primarily degraded by the enzyme monoacylglycerol lipase (MAGL).[12] KML29 is a potent MAGL inhibitor, and its use is expected to enhance the effects of endocannabinoids. Although KML29 has been more commonly studied for its anxiolytic and analgesic effects, some studies have suggested that it may also have protective effects against ischemia-reperfusion injury.[13,14] While various agents have been explored to reduce intestinal I/R damage, no studies to date have specifically investigated the effect of KML29 on mesenteric I/R injury. Therefore, the aim of this study was to evaluate the effects of KML29 on mesenteric I/R injury using histopathological and biochemical parameters.

MATERIALS AND METHODS

Animals

The study included 32 Wistar Albino rats, each weighing between 200 and 220 grams. The animals were housed under controlled conditions: temperature 20-22°C, humidity 55-65%, and a 12-hour light/dark cycle, maintained until the day of the experiment. The study was conducted in accordance with the Declaration of Helsinki and complied with international ethical guidelines and standards. Ethical approval was obtained from the Saki Yenilli Experimental Animal Production and Research Laboratory (Date: 02/10/2020, Decision No: 23). All research procedures and surgical interventions were carried out at the Saki Yenilli Experimental Animal Production and Research Laboratory. Histopathological examinations and immunohistochemistry analyses were performed at the Histology and Embryology Laboratory of the Faculty of Medicine, Yozgat Bozok University.

Experimental Design

Rats were randomly divided into four groups with eight rats in each group, for a total of 32 rats:

Group I – Sham group (n=8): Rats underwent laparotomy without occlusion of the superior mesenteric artery.

Group II – Ischemia-Reperfusion (IR) group (n=8): Intestinal ischemia-reperfusion was induced by occluding the superior mesenteric artery for 45 minutes, followed by 60 minutes of reperfusion.

Group III – IR + KML29 (2 mg/kg) group (n=8): Rats subjected to ischemia/reperfusion were administered 2 mg/kg of KML29 intraperitoneally 30 minutes before the ischemic period.

Group IV – IR + KML29 (10 mg/kg) group (n=8): Rats subjected to ischemia/reperfusion were administered 10 mg/kg of KML29 intraperitoneally 30 minutes before the ischemic period.

Except for the sham group, all rats underwent 45 minutes of ischemia followed by 60 minutes of reperfusion after laparotomy.[15]

Surgical Process

Twelve hours prior to the intestinal ischemia-reperfusion procedure, food was withdrawn from the rats' diet, and only water was provided. Anesthesia was induced using a mixture of 7 mg/kg xylazine hydrochloride (Rompun; Bayer, Türkiye) and 50 mg/kg ketamine hydrochloride (Ketalar; Eczacıbaşı, Türkiye), administered via intraperitoneal injection. Following shaving of the abdominal region, the area was disinfected with povidone-iodine. A midline incision was made, and laparotomy was performed. In the sham group (Group S), rats underwent mesenteric pedicle dissection and were administered 0.9% sodium chloride intraperitoneally. In the mesenteric ischemia-reperfusion group (Group MIR), the superior mesenteric artery was identified at its origin from the aorta, and closed using an atraumatic microvascular clamp for 45 minutes. Pallor and absence of pulse in the intestines were observed. Warm (38°C) saline solution-soaked wet gauze was used to wrap the abdominal organs during ischemia-reperfusion. After 45 minutes of ischemia, the clamp was removed, and 60 minutes of reperfusion was initiated (Fig. 1a). Following reperfusion, the pulse of the SMA was checked, and restoration of ileal nourishment was observed (Fig. 1b). At the end

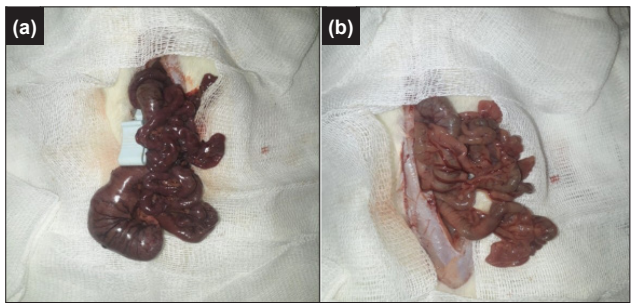

Figure 1. (a) Intestinal appearance 45 minutes after mesenteric ischemia. **(b)** Intestinal appearance 60 minutes after reperfusion.

of the reperfusion period, all rats were sacrificed, and a 10-cm segment of the ileal loop was excised. The collected intestinal segment was divided into two parts. Histopathological and immunohistochemical analyses were performed on the first portion. Malondialdehyde (MDA) levels and antioxidant enzyme activity were assessed in the second portion. The tissues were washed in 0.9% sodium chloride solution and fixed in 10% formaldehyde. Terminal deoxynucleotidyl transferase dUTP nick end labeling (TUNEL) staining, nuclear factor kappa B, TNF-α, IL-1β, transforming growth factor-beta 1 (TGF-β1), and histopathological changes were evaluated in the extracted ileal tissues.

Chemicals

KML29 (Sigma-Aldrich Corp., St. Louis, Missouri, USA) was solubilized in dimethyl sulfoxide (DMSO) and diluted to the final concentration in a vehicle solution (1:1:18; DMSO:cremophor:saline) on the day of use.[16]

Histopathological Examination

Intestinal tissue specimens were preserved in 10% formaldehyde for histological analysis. Standard tissue processing and paraffin embedding were performed, and 5 µm-thick sections were prepared from the paraffin blocks. The sections were stained with hematoxylin and eosin (H&E).[17] Histopathological scoring was performed in ten different areas per specimen. The scoring criteria were as follows: 0: no damage, 1: mild damage, 2: moderate damage, 3: severe damage. The scoring criteria took into account indicators of tissue damage, including cellular shedding and hemorrhage.

Immunohistochemistry

The avidin-biotin-peroxidase method was used for the immunohistochemical detection of intestinal nuclear factor kappa B (NF-κB) (sc-514451, Santa Cruz Biotechnology, USA), interleukin-1 beta (IL-1β) (sc-52012, Santa Cruz Biotechnology, USA), TNF-α (sc-52746, Santa Cruz Biotechnology, USA), and TGF-β1 (sc-130348, Santa Cruz Biotechnology, USA) immunoreactivity. Paraffin-embedded tissue sections (5 µm thick) were incubated in an oven at 60°C overnight, then passed through xylene and a descending alcohol gradient. After rinsing with distilled water, antigen retrieval was performed using a citrate buffer. The sections were then washed with phosphate-buffered saline (PBS), followed by treatment with hydrogen peroxide. The Large Volume Detection System kit was used for the subsequent procedures. A 5-minute serum block was then applied. Following this, NF-κB, IL-1β, TNF-α, and TGF-β1 were used as primary antibodies, incubated overnight at +4°C. After primary antibody incubation, diaminobenzidine (DAB) chromogen and biotinylated secondary streptavidin-HRP were applied, and Gill's hematoxylin was used for counterstaining.[18,19] Finally, the sections were passed through an increasing alcohol gradient and xylene, then mounted with Entellan. Immunoreactivity was scored based on images taken from 10 different areas of each slide. Scoring was defined as follows: 0 = no staining, 1 = mild staining, 2 = moderate staining, 3 = severe staining.

Tunel

Apoptosis was detected using an in situ apoptosis detection kit (ApopTag® Plus Peroxidase In Situ Apoptosis Detection Kit, Millipore, S7101, USA, Burlington MA). Sections (5 µm thick) were cut from paraffin blocks of intestinal tissue samples of all four groups. The sections were rinsed in distilled water after being deparaffinized in xylene, rehydrated, and treated for 10 minutes with 20 µg/mL proteinase K (Cat. No: 20S-001). Endogenous peroxidase activity was reduced using 3% hydrogen peroxide. The sections were then incubated with the terminal deoxynucleotidyl transferase (TdT) enzyme for 60 minutes at 37°C in a humidified chamber, followed by an equilibration buffer for 10 to 15 seconds. After 10 minutes at room temperature in a prewarmed working-strength stop/wash buffer, the sections were incubated for 45 minutes with anti-streptavidin-peroxidase. DAB was used for staining, and Gill's hematoxylin was applied for nuclear counterstaining.[18]

Statistical Analysis

All statistical analyses were performed using GraphPad Prism version 7.00 for Mac (GraphPad Software, La Jolla, CA). The normal distribution of the data was assessed using the D'Agostino-Pearson omnibus test. For normally distributed data, Tukey's post hoc test and one-way analysis of variance were used to compare quantitative variables. Data are presented as the mean ± standard deviation of normalized values. A p value of <0.05 was considered statistically significant.

RESULTS

Histopathological Findings

Table 1 summarizes the results of hematoxylin and eosin staining. The histological structure in the sham group was normal. The IR group showed signs of hemorrhage and epithelial degeneration. Compared to the sham group, a statistically significant increase in histopathological damage was observed in the IR group. In the KML29 10 mg/kg group, this damage was significantly reduced compared to the IR group (Fig. 2).

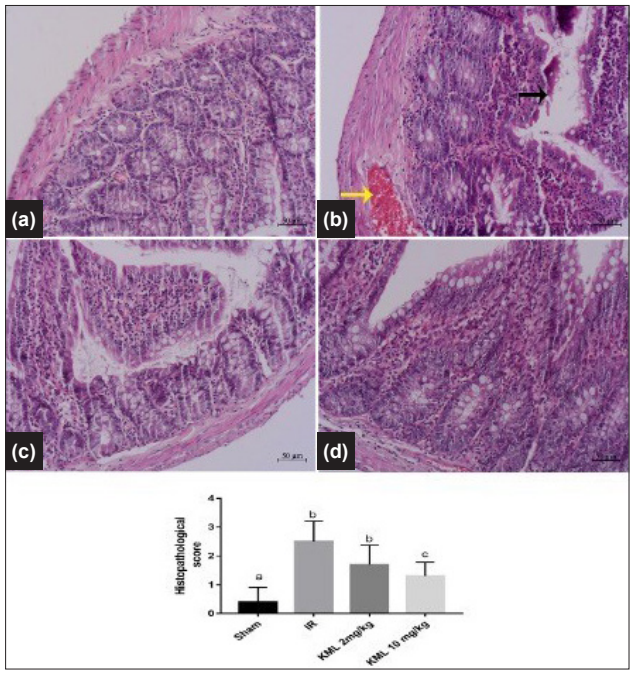

Figure 2. Hematoxylin and eosin stained images of intestinal tissue and histopathological scoring graph. **(a)** Sham group, **(b)** Ischemia-reperfusion (IR) group, **(c)** KML29 2 mg/kg group, **(d)** KML29 10 mg/kg group. Hemorrhagic areas are indicated by yellow arrows. Degenerating epithelial cells are indicated by black arrows. Magnification: X200. Groups with the same letter (a, b, c) in the graphs do not show a statistically significant difference. p<0.05 is considered significant.

Immunohistochemical Findings

Figure 3 shows the immunohistochemistry images, and Table 2 presents the corresponding immunoreactivity results. Compared to the sham group, the IR group exhibited significantly increased immunoreactivities of NF-κB, TNF-α, IL-1β, and TGF-β1 (p=0.0001). In the group treated with 10 mg/kg KML29, the immunoreactivities of these proteins were significantly reduced (p=0.0001).

TUNEL Results

TUNEL results are presented in Table 3. The number of apoptotic cells in the IR group was significantly higher compared to the sham group (p=0.0001). In the groups treated with KML29 at 2 mg/kg and 10 mg/kg, the number of apoptotic cells significantly decreased compared to the IR group (p=0.0001) (Fig. 4).

DISCUSSION

In this study, we evaluated the effect of KML29 on intestinal IR injury in rats. KML29 is a potent and selective inhibitor of MAGL. Both histopathological and immunohistochemical findings indicated a protective effect of KML29 against mesenteric ischemia-reperfusion (MIR) injury.

Acute mesenteric ischemia is a vascular emergency of the small intestine that presents as an acute abdomen. Embolization of the small bowel is the most common cause of AMI. [1] Ischemic tissue damage begins with a reduction in blood flow and oxygen supply to the tissue. If ischemia persists, it progresses to cellular necrosis. Reperfusion, on the other hand, triggers the release of chemotactic mediators such as complement component 3a (C3a), interleukin-1 (IL-1), leukotriene B4 (LT-B4), and tumor necrosis factor-alpha from polymorphonuclear leukocytes recruited during the ischemic phase. These metabolites have a more destructive effect on cells already damaged by ischemia. This phenomenon is

Table 1. Histopathological scores

Group	Sham	IR	KML29 2 mg/kg	KML29 10 mg/kg	p
Histopathological Score	0.40±0.51[a]	2.50±0.70[b]	1.70±0.67[b]	1.30±0.48[c]	0.0001

All data are expressed as mean ± standard deviation (SD) (n=8). Groups with the same letter (a, b, c) do not differ significantly.

Table 2. Immunohistochemical findings

Group	Sham	IR	KML29 2 mg/kg	KML29 10 mg/kg	p
NF-kB Immunoreactivity	0.50±0.52[a]	2.60±0.51[b]	1.90±0.73[b]	1.10±0.56[a]	0.0001
TNF-α Immunoreactivity	0.40±0.51[a]	2.70±0.48[b]	2.10±0.56[bc]	1.60±0.51[c]	0.0001
IL-1ß Immunoreactivity	0.60±0.51[a]	2.50±0.52[b]	2.00±0.66[bc]	1.50±0.52[c]	0.0001
TGF-ß1 Immunoreactivity	0.40±0.51[a]	2.60±0.51[b]	2.00±0.47[bc]	1.60±0.51[c]	0.0001

All data are expressed as mean ± standard deviation (SD) (n=8). Groups sharing the same letter (a, b, c) do not show a statistically significant difference.

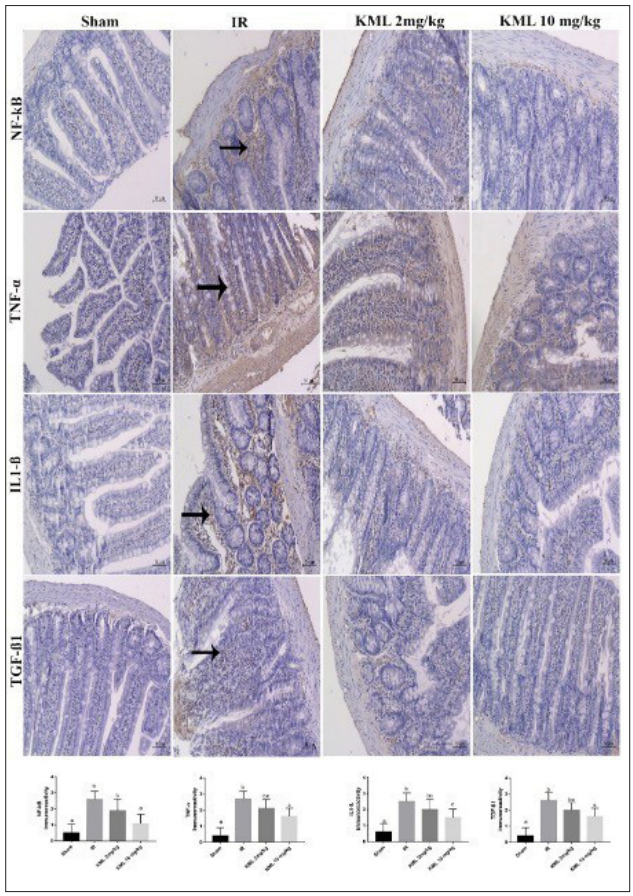

Figure 3. Immunohistochemistry images and corresponding graphs showing the expression of nuclear factor kappa B (NF-κB), tumor necrosis factor-alpha (TNF-α), interleukin-1 beta (IL-1β), and transforming growth factor-beta (TGF-β) in intestinal tissue. Magnification: X200. All data are expressed as mean ± standard deviation (SD). Groups sharing the same letter (a, b, c) do not show a statistically significant difference.

known as reperfusion injury. Among all internal organs, the intestine is the most sensitive to I/R injury. If left untreated, I/R injury in the gut can progress to shock, multiple organ failure, and sepsis.[20] Therefore, anti-inflammatory agents play a crucial role in treatment strategies, given the significant role of inflammation in I/R injury.

There is growing evidence supporting the beneficial effects of cannabinoids in a variety of clinical conditions, including pain, inflammation, multiple sclerosis, Parkinson's disease, chemotherapy, epilepsy, nausea and vomiting associated with sleep

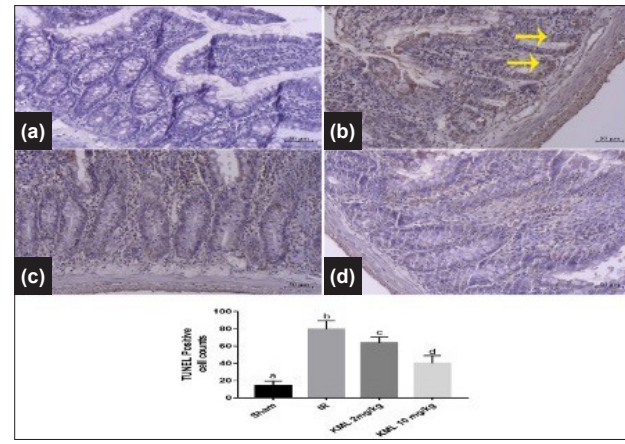

Figure 4. Terminal deoxynucleotidyl transferase dUTP nick end labeling (TUNEL) staining images of intestinal tissue and corresponding scoring graph. **(a)** Sham group, **(b)** Ischemia-reperfusion (IR) group, **(c)** KML29 2 mg/kg group, **(d)** KML29 10 mg/kg group. TUNEL-positive cells are indicated by yellow arrows. Magnification: X200. Groups with the same letter (a, b, c, d) in the graph do not show a statistically significant difference. p<0.05 is considered significant.

disorders.[21] In the gastrointestinal system, cannabinoids are involved in various metabolic processes, including gastric motility, secretion, sensitivity, vomiting, satiety, and inflammation.[22] Cannabinoid receptor type-1 (CB1) and cannabinoid receptor type-2 (CB2) are the two main subtypes of cannabis receptors. While CB1 receptors are predominantly found in the brain, spinal cord, and peripheral nervous system, CB2 receptors are located primarily in peripheral tissues involved in immune function, where they exert immunomodulatory effects.[23] Anandamide (AEA) and 2-arachidonoylglycerol (2-AG) are two of the most important known endocannabinoids. In the endocannabinoid system, MAGL hydrolyzes 2-AG, a ligand of both CB1 and CB2 receptors, facilitating the release of arachidonic acid, which is then used in the synthesis of proinflammatory eicosanoids, thereby contributing to immune modulation.[24] Inhibiting these enzymes to promote anti-inflammatory activity is currently being investigated as a novel therapeutic target in various disease models.[25] In our study, we evaluated whether KML29, a selective and highly potent MAGL inhibitor, had a protective effect against mesenteric ischemia.

The intestinal tissues of rats exposed to IR showed worsened histopathological abnormalities, an increased number

Table 3. Terminal deoxynucleotidyl transferase dUTP nick end labeling (TUNEL) results

Group	Sham	IR	KML29 2 mg/kg	KML29 10 mg/kg	p
TUNEL-Positive Cell Count	14.20±5.22[a]	79.60±9.75[b]	63.60±6.89[c]	40.00±8.86[d]	0.0001

All data are expressed as mean ± standard deviation SD (n=8). Groups with the same letter (a, b, c, d) do not differ significantly.

of TUNEL-positive (apoptotic) cells, and elevated immunoreactivities of NF-κB, TNF-α, IL-1β, and TGF-β1. According to recent studies using inflammatory disease models such as rheumatoid arthritis, asthma, inflammatory bowel disease, and neurological diseases, activation of CB2 receptors has been shown to inhibit the overproduction of proinflammatory cytokines such as TNF-α and IL-1β.[26,27] Bayram et al.[28] demonstrated in their study using an MIR rat model that the application of a CB2 receptor agonist improved impaired contractility in the ileal smooth muscle and inhibited the expression of TNF-α and IL-1β. Similarly, Çakır et al.[14] investigated the effect of KML29 on kidney I/R injury and, consistent with our findings, showed that elevated levels of NF-κB, TNF-α, and IL-1β in kidney I/R injury were reduced in groups treated with KML29. In our study, the presence of apoptosis was confirmed through TUNEL staining. These results suggest that the anti-inflammatory properties of KML29 contribute to its protective effects against I/R injury.

In addition to their anti-inflammatory and antioxidant effects, cannabinoids are also known for their analgesic properties.[29] Therefore, KML29 administration may have therapeutic potential for managing symptoms in AMI, a condition often characterized by severe pain. Another notable finding of our study is that both doses of KML29 improved histopathological findings, reduced inflammation, and decreased apoptosis in MIR injury. However, this effect was not statistically significant in the group treated with 2.5 mg/kg KML29, whereas statistically significant anti-inflammatory and anti-apoptotic activity was observed in the group treated with 10 mg/kg KML29.

A strength of our study is that it demonstrates the protective effect of KML29 on MIR injury through its anti-inflammatory and anti-apoptotic properties, an area that has not been previously explored, despite KML29 being evaluated in various experimental models. Another strength is the assessment of KML29's effectiveness at two different doses. A limitation of the study is that antioxidant activity was not measured, and the reperfusion period was relatively short.

CONCLUSION

In conclusion, this study showed that treatment with both doses of KML29 (2.5 mg/kg and 10 mg/kg) significantly reduced the number of apoptotic cells and inflammatory markers, and improved histopathological findings in the intestinal tissues of rats subjected to IR injury. With its anti-inflammatory and anti-apoptotic properties, KML29 can be considered a promising new therapeutic approach for the treatment of mesenteric ischemia.

Ethics Committee Approval: This study was approved by the Saki Yenilli Experimental Animal Production and Research Laboratory Ethics Committee (Date: 02.10.2020, Decision No: 23).

Peer-review: Externally peer-reviewed.

Authorship Contributions: Concept: A.A., İ.Ç., E.K., AT.; Design: İ.Ç., E.K., M.M.O.; Supervision: A.K., M.M.O.; Resource: İ.Ç., A.T., M.M.O.; Materials: İ.Ç., A.T., M.M.O.; Data collection and/or processing: A.A., İ.Ç., A.K., E.K.; Analysis and/or interpretation: E.K., A.T.; Literature review: İ.Ç., A.K., M.M.O.; Writing: İ.Ç., A.A.; Critical review: İ.Ç., A.A., A.K., A.T.

Conflict of Interest: None declared.

Financial Disclosure: The author declared that this study has received no financial support.

REFERENCES

1. Yasuhara H. Acute mesenteric ischemia: The challenge of gastroenterology. Surg Today 2005;35:185–95. [CrossRef]
2. Menon NJ, Amin AM, Mohammed A, Hamilton G. Acute mesenteric ischaemia. Acta Chir Belg 2005;105:344–54. [CrossRef]
3. Schoenberg MH, Muhl E, Sellin D, Younes M, Schildberg FW, Haglund U. Posthypotensive generation of superoxide free radicals—Possible role in the pathogenesis of the intestinal mucosal damage. Acta Chir Scand 1984;150:301–9.
4. Cappell MS. Intestinal (mesenteric) vasculopathy. I. Acute superior mesenteric arteriopathy and venopathy. Gastroenterol Clin North Am 1998;27:783–825. [CrossRef]
5. Sizlan A, Guven A, Uysal B, Yanarates O, Atim A, Oztas E, et al. Proanthocyanidin protects intestine and remote organs against mesenteric ischemia/reperfusion injury. World J Surg 2009;33:1384–91. [CrossRef]
6. Badripour A, Behzadi M, Hassanipour A, Azar PRS, Rahbar A, Abbaslou Z, et al. Albendazole ameliorates inflammatory response in a rat model of acute mesenteric ischemia reperfusion injury. Biomed Pharmacother 2022;153:113320. [CrossRef]
7. Sayhan M, Oguz S, Salt Ö, Can N, Ozgurtas T, Yalta T. Sesamin ameliorates mucosal tissue injury of mesenteric ischemia and reperfusion in an experimental rat model. Arch Med Sci 2019;15:1582–8. [CrossRef]
8. Zou Z, Wang Z. Liraglutide attenuates intestinal ischemia/reperfusion injury via NF-κB and PI3K/Akt pathways in mice. Life Sci 2022;309:121045. [CrossRef]
9. Goutopoulos A, Makriyannis A. From cannabis to cannabinergics: New therapeutic opportunities. Pharmacol Ther 2002;95:103–17. [CrossRef]
10. Croxford JL, Yamamura T. Cannabinoids and the immune system: Potential for the treatment of inflammatory diseases? J Neuroimmunol 2005;166:3–18. [CrossRef]
11. Tóth VE, Fehér Á, Németh J, Gyertyán I, Zádori ZS, Gyires K. Modulation of central endocannabinoid system results in gastric mucosal protection in the rat. Brain Res Bull 2018;139:224–34. [CrossRef]
12. Ueda N, Tsuboi K, Lambert DM. A second N-acylethanolamine hydrolase in mammalian tissues. Neuropharmacology 2005;48:1079–85. [CrossRef]
13. Crowe MS, Wilson CD, Leishman E, Prather PL, Bradshaw HB, Banks ML, et al. The monoacylglycerol lipase inhibitor KML29 with gabapentin synergistically produces analgesia in mice. Br J Pharmacol 2017;174:4523–39. [CrossRef]
14. Çakır M, Aydın A, Tekin S. Protective effect of fatty acid amide hydrolase inhibitor URB597 and monoacylglycerol lipase inhibitor KML29 on renal ischemia-reperfusion injury via toll-like receptor 4/nuclear factor-kappa B pathway. Int Immunopharmacol 2023;114:109586. [CrossRef]
15. Ozturk H, Ozturk H, Duran H, Uzunlar AK. Mibefradil, a T-type Ca2+ channel blocker, protects against mesenteric ischemia-reperfusion-induced oxidative injury and histologic alterations in intestinal mucosa in rats. Dig Dis Sci 2006;51:1454–60. [CrossRef]
16. Philpott HT, McDougall JJ. Combatting joint pain and inflammation by dual inhibition of monoacylglycerol lipase and cyclooxygenase-2 in a rat

model of osteoarthritis. Arthritis Res Ther 2020;22:9. [CrossRef]
17. Karabulut D, Ulusoy HB, Kaymak E, Sönmez MF. Therapeutic effects of pentoxifylline on diabetic heart tissue via NOS. Anatol J Cardiol 2016;16:310–5. [CrossRef]
18. Demir Çaltekin M, Özkut MM, Çaltekin İ, Kaymak E, Çakır M, Kara M, et al. The protective effect of JZL184 on ovarian ischemia reperfusion injury and ovarian reserve in rats. J Obstet Gynaecol Res 2021;47:2692–704. [CrossRef]
19. Ozcaliskan Ilkay H, Karabulut D, Kamaci Ozocak G, Mehmetbeyoglu E, Kaymak E, Kisioglu B, Cicek B, et al. Quinoa (Chenopodium quinoa Willd.) supplemented cafeteria diet ameliorates glucose intolerance in rats. Food Sci Nutr 2023;11:6920–30. [CrossRef]
20. Hierholzer C, Kalff JC, Audolfsson G, Billiar TR, Tweardy DJ, Bauer AJ. Molecular and functional contractile sequelae of rat intestinal ischemia/reperfusion injury. Transplantation 1999;68:1244–54. [CrossRef]
21. Gamble LJ, Boesch JM, Frye CW, Schwark WS, Mann S, Wolfe L, et al. Pharmacokinetics, safety, and clinical efficacy of cannabidiol treatment in osteoarthritic dogs. Front Vet Sci 2018;5:165. [CrossRef]
22. Storr MA, Sharkey KA. The endocannabinoid system and gut-brain signalling. Curr Opin Pharmacol 2007;7:575–82. [CrossRef]
23. Turcotte C, Blanchet MR, Laviolette M, Flamand N. The CB2 receptor and its role as a regulator of inflammation. Cell Mol Life Sci 2016;73:4449–70. [CrossRef]
24. Jiang SK, Zhang M, Tian ZL, Wang M, Zhao R, Wang LL, et al. The monoacylglycerol lipase inhibitor JZL184 decreases inflammatory response in skeletal muscle contusion in rats. Eur J Pharmacol 2015;761:1–10. [CrossRef]
25. Kaur R, Ambwani SR, Singh S. Endocannabinoid system: A multi-facet therapeutic target. Curr Clin Pharmacol 2016;11:110–7. [CrossRef]
26. Robinson ES, Alves P, Bashir MM, Zeidi M, Feng R, Werth VP. Cannabinoid reduces inflammatory cytokines, tumor necrosis factor-α, and type I interferons in dermatomyositis ın vitro. J Invest Dermatol 2017;137:2445–7. [CrossRef]
27. Zhu M, Yu B, Bai J, Wang X, Guo X, Liu Y, et al. Cannabinoid receptor 2 agonist prevents local and systemic inflammatory bone destruction in rheumatoid arthritis. J Bone Miner Res 2019;34:739–51. [CrossRef]
28. Bayram S, Parlar A, Arslan SO. The curative effect of cannabinoid 2 receptor agonist on functional failure and disruptive inflammation caused by intestinal ischemia and reperfusion. Fundam Clin Pharmacol 2020;34:80–90. [CrossRef]
29. Ghosh S, Wise LE, Chen Y, Gujjar R, Mahadevan A, Cravatt BF, et al. The monoacylglycerol lipase inhibitor JZL184 suppresses inflammatory pain in the mouse carrageenan model. Life Sci 2013;92:498–505. [CrossRef]

DENEYSEL ÇALIŞMA - *ÖZ*

KML29'un bağırsak iskemi-reperfüzyon hasarı üzerindeki koruyucu etkileri: Deneysel bir çalışma

AMAÇ: Akut mezenterik iskemi (AMİ), iskemi-reperfüzyon hasarına bağlı doku hasarı ile sonuçlanan, erken tanı ve tedavisi zor olan, yaşamı tehdit eden vasküler bir acil durumdur. Monoasilgliserol lipaz inhibitörleri, antioksidan ve antienflamatuvar özellikleri ile iskemi-reperfüzyon hasarında (İRH) koruyucu etkiler göstermiştir. Bu çalışmanın amacı, güçlü ve seçici bir monoasilgliserol lipaz inhibitörü olan KML29'un bağırsak İRH üzerindeki etkilerini değerlendirmektir.

GEREÇ VE YÖNTEM: Otuz iki dişi Wistar-Albino sıçan dört gruba ayrıldı: Grup 1 – Sham; Grup 2 – iskemi/reperfüzyon (IR); Grup 3 – IR + KML29 2 mg/kg; Grup 4 – IR + KML29 10 mg/kg. Bağırsak iskemisi ve reperfüzyonu, süperior mezenterik arterin 45 dakika süreyle oklüzyonu ve ardından 60 dakika reperfüzyon uygulanması ile sağlandı. Grup 3 ve grup 4'e, cerrahiden 30 dakika önce iki farklı dozda KML29 (2 ve 10 mg/kg) intraperitoneal olarak uygulandı. Bağırsak İRH'si, dokuda histopatolojik ve biyokimyasal parametreler kullanılarak değerlendirildi.

BULGULAR: 10 mg/kg KML29 ile tedavi, IR grubunda histopatolojik bulgularda anlamlı bir iyileşme ile ilişkilendirildi (p=0.0001). IR grubunda artmış olan NF-kB, TNF-α, IL1-β ve TGF-β1 düzeyleri, 10 mg/kg KML29 uygulaması ile anlamlı olarak azaldı (p=0.0001). KML29'un hem 2 mg/kg hem de 10 mg/kg dozlarıyla yapılan tedavi, IR grubunda artan apoptotik hücre sayısını anlamlı ölçüde azalttı (p=0.0001).

SONUÇ: Bu çalışmada, IR'ye maruz bırakılan sıçanların bağırsak dokuları incelendiğinde, KML29'un 2 mg/kg ve 10 mg/kg dozlarıyla yapılan tedavinin apoptotik hücre sayısını ve inflamasyon belirteçlerini anlamlı düzeyde azalttığı ve histopatolojik bulguları iyileştirdiği gösterildi. KML29 ile tedavi, antienflamatuvar ve antiapoptotik özellikleri sayesinde mezenterik iskeminin tedavisinde yeni bir yaklaşım seçeneği olarak değerlendirilebilir.

Anahtar sözcükler: Bağırsak iskemi-reperfüzyon hasarı; KML29; monoasilgliserol lipaz inhibitörü.

Ulus Travma Acil Cerrahi Derg 2025;31(5):418-424 DOI: 10.14744/tjtes.2025.72686