EXPERIMENTAL STUDY

The effect of the daidzein on anastomosis healing in a colitis model

Başar Can Turgut,[1] Muge Yurdacan Sahin,[2] Ozan Akıncı,[3] Yasemin Pekmezci,[4] Nuray Kepil,[5] İbrahim Murat Bolayırlı,[6] Mert Mahsuni Sevinc,[1] Murat Suphan Erturk[7]

[1]Department of General Surgery, Istanbul Traning and Research Hospital, Istanbul-*Türkiye*
[2]Department of General Surgery, Bakirkoy Dr. Sadi Konuk Training and Research Hospital, Istanbul-*Türkiye*
[3]Department of General Surgery, Medicana İnternational Hospital, Istanbul-*Türkiye*
[4]Department of General Surgery, Muş State Hospital, Muş-*Türkiye*
[5]Department of Pathology, Istanbul University- Cerrahpasa, Cerrahpasa Medical Faculty, Istanbul-*Türkiye*
[6]Department of Biochemistry, Istanbul University- Cerrahpasa, Cerrahpasa Medical Faculty Istanbul-*Türkiye*
[7]Department of General Surgery, Istanbul University- Cerrahpasa, Cerrahpasa Medical Faculty, Istanbul-*Türkiye*

ABSTRACT

BACKGROUND: This experimental study aimed to investigate the effects of enterally administered daidzein on colon anastomosis in a rat model of colitis.

METHODS: A total of 48 male Wistar albino rats were used and randomly divided into eight groups of six rats each. Colitis was induced by administering either water or a 4% acetic acid solution via rectal catheter, depending on the group. On day 5, all rats underwent segmental colon resection followed by end-to-end colo-colonic anastomosis. Daidzein was administered orally to four of the groups after the procedure. Relaparotomy was performed on postoperative days 3 and 7, and the anastomosed colon segments were resected. Anastomotic bursting pressure and tissue levels of superoxide dismutase, glutathione peroxidase, and hydroxyproline were measured. Histopathological damage scores were also evaluated.

RESULTS: In both early and late postoperative periods, administration of daidzein did not result in a statistically significant improvement in anastomotic safety, based on hydroxyproline levels and bursting pressure, in either colitis or non-colitis groups ($p>0.05$). Daidzein also did not show a reducing effect on superoxide dismutase and glutathione peroxidase levels in anastomotic tissue ($p>0.05$). However, in the late postoperative period, daidzein showed a favorable effect on histopathological damage scores in non-colitis groups.

CONCLUSION: Enteral administration of daidzein in rats with experimentally induced colitis did not demonstrate a statistically significant benefit in terms of colon anastomosis healing.

Keywords: Anastomosis healing; daidzein; experimental colitis; isoflavonoids; inflammatory bowel disease.

INTRODUCTION

Ulcerative colitis (UC) and Crohn's disease (CD) are intestinal disorders characterized by chronic idiopathic inflammation. Recent studies have demonstrated that epithelial dysfunction, proinflammatory cytokines, oxidative agents, and chemokines play significant roles in the pathogenesis of inflammatory bowel diseases (IBD).[1,2]

The success of wound healing in the gastrointestinal system varies according to tissue type, blood supply, and the multilay-

Cite this article as: Turgut BC, Yurdacan Sahin M, Akıncı O, Pekmezci Y, Kepil N, Bolayırlı İM, et al. The effect of the daidzein on anastomosis healing in a colitis model. Ulus Travma Acil Cerrahi Derg 2025;31:431-437.

Address for correspondence: Başar Can Turgut
Department of General Surgery, Istanbul Traning and Research Hospital, Istanbul, Türkiye
E-mail: basarcanturgut@gmail.com

Ulus Travma Acil Cerrahi Derg 2025;31(5):431-437 DOI: 10.14744/tjtes.2025.66339
Submitted: 10.01.2025 Revised: 02.04.2025 Accepted: 10.04.2025 Published: 05.05.2025
OPEN ACCESS This is an open access article under the CC BY-NC license (http://creativecommons.org/licenses/by-nc/4.0/).

ered histological structure of the tissue. Previous experimental studies have employed biochemical, histopathological, and mechanical approaches to evaluate wound healing in the gastrointestinal tract.[3-5] In general surgical practice, anastomoses and the repair of diseased intestinal segments are commonly performed during operations for enteroenteric fistulas, perforations, or tumoral masses frequently associated with IBD.

Isoflavonoids are non-steroidal phytoestrogens and polyphenolic compounds found in natural foods such as soy. The main types include daidzein, genistein, and glycitein. Experimental studies have identified isoflavonoids as potential antioxidants and anti-inflammatory agents due to their ability to suppress free oxygen radicals (FOR). The primary dietary sources of isoflavones for humans are soybeans and their derivatives, which are rich in daidzein and genistein. Isoflavones are considered chemoprotective and have been proposed as alternative treatments for a wide range of hormonal disorders, including various cancers (such as breast and prostate cancer), cardiovascular diseases, osteoporosis, and menopausal symptoms.[6,7]

Although numerous experimental studies have explored the mechanisms and pathways of isoflavonoids, a review of the literature revealed no studies to date examining the effects of daidzein—an isoflavone molecule—on anastomotic healing in an experimental colitis model.

This study utilizes an experimental colitis model to investigate the effects of daidzein, an antioxidant isoflavone, on colonic anastomotic healing following enteral administration. We aimed to evaluate the potential role of daidzein in enhancing anastomotic safety in emergency surgical cases associated with inflammatory bowel disease.

MATERIALS AND METHODS

This study was conducted with the approval of the Istanbul University Animal Experiments Ethics Committee (date: 07.07.2020, approval number: 2020/29) and in accordance with the principles of the Declaration of Helsinki.

A total of 48 male Wistar albino rats, aged 8–10 weeks and weighing between 350 and 450 grams, were used. The rats were housed in standard cages under controlled temperature and humidity, with a 12:12 hour light–dark cycle, and were provided with standard rat chow and water ad libitum. They were randomly assigned to eight groups, each consisting of six rats.

Prior to the procedure, the rats were fasted for 12 hours, during which only water was allowed. To stimulate defecation and empty the intestines, the rats were held by the tail and gently bounced on their hind legs. Anesthesia was induced via intraperitoneal injection of 50–60 mg/kg ketamine and 8–10 mg/kg xylazine, and body weights were recorded.

Colitis was induced by administering 2 mL of 4% acetic acid via a 2.67 mm diameter, 8 cm catheter inserted into the anal canal with the rat placed head-down at a 45-degree incline under general anesthesia. During administration, the catheter was slowly withdrawn to ensure the distribution of the solution along the distal 8 cm of the colon. The rats were maintained in this position for 20 seconds to prevent leakage. In non-colitis groups, the same procedure was performed using 2 mL of 0.9% NaCl solution.

On day 5, all animals underwent a 4-cm segmental colon resection approximately 6 cm proximal to the anal verge, followed by an end-to-end colo-colonic anastomosis under general anesthesia. The anastomosis was performed in a single layer using absorbable sutures.

Relaparotomy was performed under anesthesia on postoperative days 3 and 7 in the respective groups, and the anastomotic colon segment was resected for analysis. The reference drug, daidzein, was dissolved in dimethyl sulfoxide (DMSO) and administered via drinking water, beginning on day 1. Dosage was calculated based on the rats' daily water consumption. In the groups receiving daidzein, administration was continued daily throughout the study period.

Experimental Groups and Measurement Procedures

The subjects were randomly divided into eight groups as follows:

- Group 1 (A1: Control group, postoperative day 3): Received 0.9% NaCl intrarectally at the beginning of the experiment. A segmental colon resection and end-to-end anastomosis were performed on day 5 via midline laparotomy. Relaparotomy and resection of the anastomotic line were performed on postoperative day 3.

- Group 2 (A2: Control group, postoperative day 7): Same procedure as Group 1, but relaparotomy and resection were performed on postoperative day 7.

- Group 3 (B1: Colitis group, postoperative day 3): Received 4% acetic acid intrarectally to induce colitis. Surgery was performed as described above, followed by relaparotomy and anastomosis resection on postoperative day 3.

- Group 4 (B2: Colitis group, postoperative day 7): Same procedure as Group 3, with relaparotomy and resection performed on postoperative day 7.

- Group 5 (C1: Non-colitis + daidzein group, postoperative day 3): Received 0.9% NaCl intrarectally. Colon resection and anastomosis were performed on day 5, followed by enteral administration of 10 mg/kg daidzein for 3 days. Relaparotomy and resection were performed on postoperative day 3.

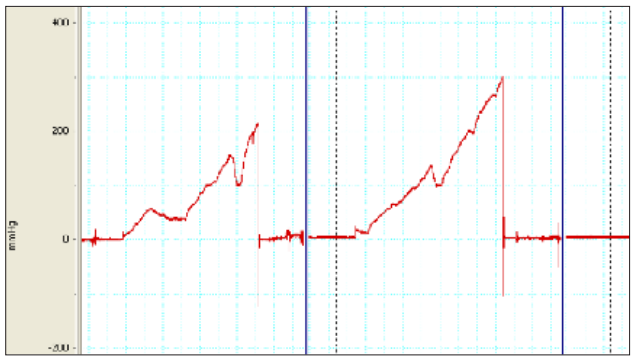

Figure 1. Manometric measurement of anastomotic bursting pressure.

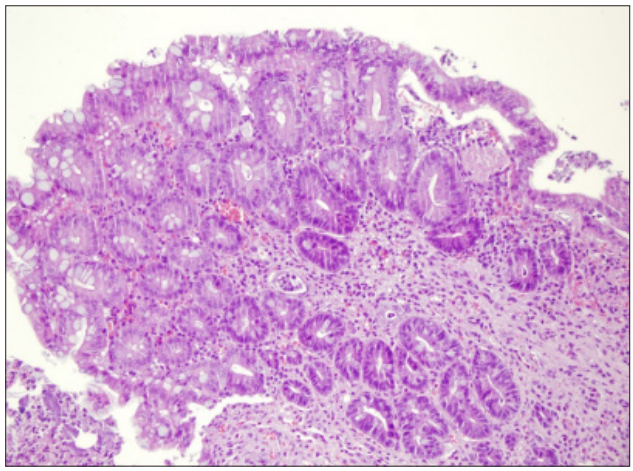

Figure 2. Goblet cell loss and cryptitis (H&E stain, ×200 magnification).

- Group 6 (C2: Non-colitis + daidzein group, postoperative day 7): Same procedure as Group 5, with daidzein administered for 7 days. Relaparotomy and resection were performed on postoperative day 7.

- Group 7 (D1: Colitis + daidzein group, postoperative day 3): Received 4% acetic acid intrarectally. After surgery on day 5, 10 mg/kg daidzein was administered enterally for 3 days. Relaparotomy and resection were performed on postoperative day 3.

- Group 8 (D2: Colitis + daidzein group, postoperative day 7): Same procedure as Group 7, with daidzein administered for 7 days. Relaparotomy and resection were performed on postoperative day 7.

Anastomosis Bursting Pressure Measurement

To measure the anastomotic bursting pressure, two catheters were inserted—one at each end of the resected anastomotic segment—and secured with 2.0 non-absorbable sutures to prevent air leakage. One catheter was connected to a mercury manometer, and the other to a volumetric infusion pump. The intestinal segment was submerged in a container filled with physiological saline. Intraluminal pressure was gradually increased using the infusion pump while pressure readings were monitored. The pressure at which a sudden drop occurred, or at which air bubbles were observed escaping from the anastomotic site, was recorded as the bursting pressure (Figure 1).

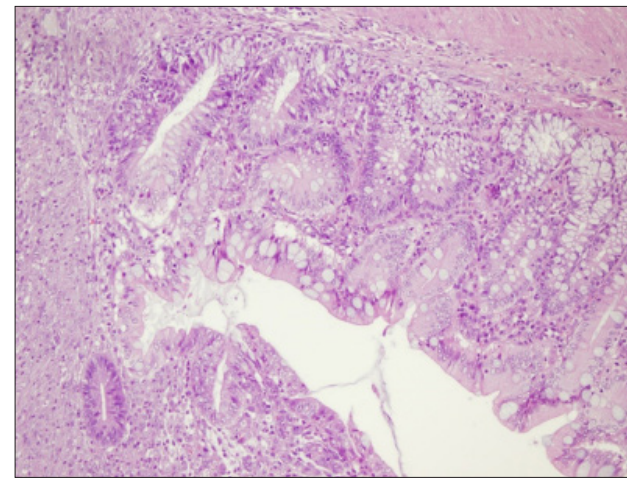

Figure 3. Mucosal tissue loss (H&E stain, ×200 magnification).

Biochemical and Histopathological Evaluation

Following the measurement of bursting pressure, tissue samples from the anastomotic line were collected for biochemical and histopathological analysis. Fibrosis was histologically evaluated and scored. Levels of hydroxyproline (HP), superoxide dismutase (SOD), and glutathione peroxidase (GPO) were measured in the remaining tissue.

A histopathological scoring system was used to assess damage caused by acetic acid-induced colitis. The parameters evaluated included tissue damage/necrosis, inflammatory cell infiltration, submucosal edema, and mucosal hemorrhage (Figures 2–3).

Statistical Analysis

Statistical analyses were performed using SPSS Statistics, Version 17.0 (Chicago, IL: SPSS Inc.). The normality of variable distributions was assessed using histogram plots and the Kolmogorov–Smirnov test. Descriptive statistics were expressed as mean, standard deviation, and median values. For the comparison of non-normally distributed (nonparametric) variables between groups, the Kruskal–Wallis test was used. Spearman's correlation test was applied to analyze the relationships between continuous variables, and changes within groups were evaluated using the Friedman test. A p-value of less than 0.05 was considered statistically significant.

RESULTS

In the colitis groups (Groups B and D), significant weight loss and diarrhea were observed until the day of the first operation (Table 1).

Table 1. Weight distribution of groups (Friedman Test)

	Weight on Day 0 (Day of Drug Administration via Rectal Route) (g)			Preoperative Weight (Day of Anastomosis) (g)			Postoperative Weight (Day of Anastomosis Resection) (g)			
Group	**Mean**	**S.D.**	**Median**	**Mean**	**S.D.**	**Median**	**Mean**	**S.D.**	**Median**	**P**
A1	401.50	±30.34	405.50	400.83	±30.73	406.00	376.50	±34.06	374.00	0.135
A2	455.50	±31.84	447.50	452.67	±27.84	449.00	431.50	±29.96	431.00	0.135
B1	368.86	±67.15	350.00	320.00	±59.90	288.00	310.57	±60.98	315.00	0.005
B2	403.67	±75.41	413.00	385.33	±51.81	394.00	355.83	±62.45	362.50	0.135
C1	414.67	±58.19	441.00	409.67	±59.57	437.00	367.50	±45.65	375.00	0.002
C2	459.00	±33.77	461.00	447.33	±19.55	444.50	433.67	±33.54	430.50	0.311
D1	377.50	±38.50	382.00	294.83	±33.90	286.50	278.83	±34.10	265.00	0.002
D2	436.33	±69.41	452.00	379.50	±48.56	391.50	362.50	±43.18	369.50	0.002

S.D.: Standard Deviation. G: Gram.

Table 2. Evaluation of early postoperative period parameters (Kruskal-Wallis Test)

	A1			B1			C1			D1			
	Mean	**S.D.**	**Median**	**Mean**	**S.D.**	**Median**	**Mean**	**S.D.**	**Median**	**Mean**	**S.D.**	**Median**	**P**
Anastomotic Burst Pressure (mmHg)	37.83	±19.00	38.00	32.00	±39.00	18.00	29.83	±11.27	30.00	36.83	±19.42	41.00	0.342
SOD (ng/mg pro)	10.46	±4.86	10.68	14.43	±8.36	14.36	10.75	±5.26	11.64	16.29	±2.37	16.40	0.203
GPO (ng/mg pro)	14.68	±1.58	14.28	35.39	±17.06	33.14	18.95	±8.49	17.93	21.53	±6.72	21.21	0.046
HP (ng/mg pro)	43.08	±4.77	43.80	60.43	±27.88	66.68	49.39	±27.24	48.78	108.05	±66.91	91.00	0.191
Histopathological Damage Score	2.50	±2.07	3.00	9.67	±1.21	9.50	.00	±.00	.00	3.00	±1.26	2.50	<0.001

S.D.: Standard Deviation. HP: Hydroxyproline. GPO: Glutathione Peroxidase. SDO: Superoxide Dismutase.

Preoperative and postoperative weight changes were recorded for all groups. A decrease in preoperative weight was noted in Group B1, with no subsequent postoperative weight gain. A continuous weight loss was observed in Groups C1, D1, and D2, whereas no significant change was noted in Groups A1, A2, B2, and C2 (Table 2).

Anastomotic bursting pressure, superoxide dismutase (SOD), glutathione peroxidase (GPO), hydroxyproline (HP) levels, and histopathological damage scores were compared among Groups A2, B2, C2, and D2. A statistically significant difference was observed between the groups in terms of anastomotic bursting pressure and histopathological damage scores. Post-hoc analysis revealed that Group A2 had significantly higher bursting pressure values compared to Group D2. Additionally, the histopathological damage score in Group A2 was higher than that in Group C2 (Table 3).

Correlations between anastomotic bursting pressure, SOD, GPO, HP, and histopathological damage scores were evaluated within each group. In Group B1, a negative correlation was observed between HP levels and bursting pressure, along with a positive correlation between histopathological damage scores and bursting pressure. In Group B2, a positive correlation was found between GPO levels and bursting pressure. In Group C1, a positive correlation was noted between GPO and HP levels. In Group C2, a negative correlation was observed between HP levels and bursting pressure. In Group D1, a positive correlation was found between histopathological damage scores and HP levels. Lastly, in Group D2, a positive correlation was observed between GPO and SOD levels, and a negative correlation between histopathological damage scores and both SOD and GPO levels.

DISCUSSION

Experimental colitis models are commonly used to investigate the pathogenesis of inflammatory bowel disease (IBD) and to facilitate the development of treatment algorithms. These models enable researchers to better understand the

Table 3. Evaluation of late postoperative period parameters (Kruskal-Wallis Test)

	A2			B2			C2			D2			
	Mean	S.D.	Median	Mean	S.D.	Median	Mean	S.D.	Median	Mean	S.D.	Median	P
Anastomotic Burst Pressure (mmHg)	289.67	±109.19	265.00	212.83	±54.32	212.50	233.67	±62.12	226.00	167.00	±16.86	165.00	0.023
SOD (ng/mg pro)	12.60	±18.74	4.17	4.98	±3.15	5.03	5.72	±3.24	6.00	1.45	±1.55	.97	0.072
GPO (ng/mg pro)	10.91	±7.12	9.25	8.13	±3.70	7.99	9.43	±3.21	9.04	5.85	±5.04	5.33	0.224
HP (ng/mg pro)	80.97	±33.87	75.79	64.82	±17.09	67.88	57.97	±30.56	60.65	162.04	±177.10	110.34	0.261
Histopathological Damage Score	6.17	±3.66	7.00	5.50	±3.21	6.00	.00	±.00	.00	3.67	±4.46	2.00	0.016

S.D.: Standard Deviation. HP: Hydroxyproline. GPO: Glutathione Peroxidase. SDO: Superoxide Dismutase.

mechanisms underlying IBD and contribute to the identification of novel therapeutic approaches. Various experimental studies have evaluated the therapeutic potential of numerous agents and methods, including vitamin D, N-acetylcysteine, quercetin, and melatonin.[8-12]

Isoflavonoids are non-steroidal phytoestrogens naturally found in dietary soy products such as soy flour, soy milk, soybeans, and tofu. Numerous studies have reported that isoflavonoids can reduce intestinal wall inflammation, attenuate reactive oxygen species (ROS) associated with inflammation, promote wound healing as evidenced by histopathological evaluations, decrease the presence of pathogenic bacteria in the intestinal lumen, and positively affect gut motility.[13-18] However, some studies have reported no significant effects of isoflavonoids on intestinal function.[19]

Daidzein, a derivative of isoflavonoids, is a phytoestrogen that exhibits both mild estrogenic and antiestrogenic effects. Research on daidzein has investigated its anti-inflammatory and antioxidant properties, its influence on serum glucose and lipid levels, its hormone-like activity, its wound-healing capacity, and its potential roles in sepsis and oxidative stress.[20-25] Although the present study did not demonstrate any ameliorative effect of daidzein on colitis-induced damage, previous studies have suggested that daidzein may exert a protective effect against tissue damage in ischemia–reperfusion models. Additionally, genistein—a molecule structurally similar to daidzein—has shown beneficial effects in the healing of colitis in other studies.[26,27]

Experimental research has shown that isoflavonoid compounds with anti-inflammatory and antioxidant properties can support wound and bone healing, as well as enhance colon anastomotic healing.[28-30] Based on this body of evidence, we aimed to investigate the potential effects of daidzein on colonic anastomosis in the context of inflammatory bowel disease, considering its known anti-inflammatory and antioxidant actions.

The presence of colitis has a detrimental impact on intestinal healing. In recent years, various experimental models have been developed to study intestinal inflammation, providing valuable insights into the mechanisms involved in maintaining mucosal homeostasis and contributing to intestinal inflammation. These models have enabled the identification of therapeutic targets and the development of new treatments—primarily biological agents. The safety and efficacy of these agents have been evaluated in numerous clinical studies, which have also reported severe complications associated with colitis, including intestinal perforation, enteroenteric and enterocutaneous fistulas, gastrointestinal bleeding, and increased mortality. Consequently, the search continues for strategies that can accelerate healing and reduce morbidity in patients with colitis.

Ulcer formation on the mucosa during colitis, increased intestinal wall permeability, and inflammation-induced apoptosis impair healing at the anastomotic site. Additionally, poor mucosal perfusion and the accompanying inflammatory response lead to elevated levels of free oxygen radicals, which interfere with the synthesis of healing factors and may compromise the structural integrity of anastomoses in colitic intestines.[4,31-39] A review of the literature reveals no previous study investigating the effect of daidzein on anastomotic healing in experimental colitis models.

In the present study, a statistically significant weight loss was observed in the colitic groups. Daidzein administration did not mitigate this effect in either colitic or non-colitic groups. This finding contrasts with earlier studies suggesting that daidzein contributes to weight regulation, although those studies employed different experimental models.[1,26,40,41]

Increased glutathione peroxidase (GPO) levels in a colitic environment reflect elevated reactive oxygen species (ROS), with GPO acting as an antioxidant marker of oxidative stress. In the early postoperative period, a high histopathological

damage score was noted in the colitis group (Group B1), whereas a significant reduction was observed in the non-colitic group treated with daidzein (Group C1). This suggests a potential protective effect of daidzein on anastomotic healing in non-colitic conditions.

In the late postoperative period, the anastomotic bursting pressure was significantly higher in the non-colitic, non-daidzein-treated group (Group A2) compared to the colitic, daidzein-treated group (Group D2), indicating that daidzein did not reverse the adverse effects of colitis on anastomotic healing. However, within the non-colitic groups, the daidzein-treated group (Group C2) showed a greater reduction in histopathological damage scores than the untreated group (Group A2), suggesting that daidzein may enhance healing in normal tissue environments, despite its lack of efficacy in inflamed tissue.

Evaluation of the early and late postoperative results revealed inconsistencies between expected outcomes and the correlations observed among various parameters. For example, in the early postoperative colitic group (Group B1), a negative correlation was found between hydroxyproline (HP) levels and anastomotic bursting pressure, yet a positive correlation was also noted between histopathological damage and bursting pressure in the same group. In the early postoperative non-colitic, daidzein-treated group (Group C1), a positive correlation was observed between GPO and HP levels. Similarly, in the colitic, daidzein-treated group (Group D1), a positive correlation was found between histopathological damage scores and HP.

In the late postoperative period, a positive correlation between anastomotic bursting pressure and GPO was observed in the colitic, non-daidzein-treated group (Group B2), while a negative correlation between bursting pressure and HP was identified in the non-colitic, daidzein-treated group (Group C2). Furthermore, in the colitic, daidzein-treated group (Group D2), a positive correlation was observed between GPO and superoxide dismutase (SOD), along with an inverse correlation between histopathological damage scores and both SOD and GPO.

CONCLUSION

This study, which investigated the effects of daidzein on anastomotic healing in an experimental rat model, demonstrated that colitis generally impairs anastomotic healing and that this adverse effect is not alleviated by the enteral administration of daidzein. A review of the literature revealed no previous clinical or experimental studies specifically addressing this issue. Therefore, we believe that further research is warranted to validate or challenge these findings, ideally by exploring different experimental models, dosages, and routes of daidzein administration.

Ethics Committee Approval: This study was approved by the Istanbul University Animal Experiments Ethics Committee (Date: 07.07.2020, Decision No: 2020/19).

Peer-review: Externally peer-reviewed.

Authorship Contributions: Concept: M.S.E., B.C.T., O.A.; Design: B.C.T., O.A., M.S.E.; Supervision: Y.P., İ.M.B., N.K.; Resource: M.Y.Ş., N.K.; Materials: İ.M.B., N.K., M.Y.Ş.; Data collection and/or processing: M.S.E., B.C.T., Y.P.; Analysis and/or interpretation: N.K., M.M.S.; Literature review: B.C.T., O.A., M.M.S.; Writing: B.C.T., M.Y.Ş. M.M.S.; Critical review: Y.P., M.Y.Ş., M.M.S.

Conflict of Interest: None declared.

Financial Disclosure: This study was funded by Istanbul University-Cerrahpaşa Scientific Research Projects Unit (BAP, 2020-35286)

REFERENCES

1. Ashton JJ, Beattie RM. Inflammatory bowel disease: Recent developments. Arch Dis Child 2024;109:370–6. [CrossRef]
2. Gilliland A, Chan JJ, De Wolfe TJ, Yang H, Vallance BA. Pathobionts in inflammatory bowel disease: Origins, underlying mechanisms, and implications for clinical care. Gastroenterology 2024;166:44–58. [CrossRef]
3. Yüceyar S, Ertürk S, Temiz M, Doğusoy G, Gümüştaş K, Ozgüroğlu M, et al. Role of the antiangiogenetic drug paclitaxel on healing of intestinal anastomosis: An experimental study. Tech Coloprocto. 2005;9:201–5. [CrossRef]
4. Vidal-Lletjós S, Andriamihaja M, Blais A, Grauso M, Lepage P, Davila AM, et al. Mucosal healing progression after acute colitis in mice. World J Gastroenterol 2019;25:3572–89. [CrossRef]
5. Özçay N, Özdemir H, Besim H. Role of platelet-rich fibrin on intestinal anastomosis wound healing in a rat. Biomed Mater 2018;13:045006. [CrossRef]
6. Wang Y, Liu XJ, Chen JB, Cao JP, Li X, Sun CD. Citrus flavonoids and their antioxidant evaluation. Crit Rev Food Sci Nutr 2022;62:3833–54. [CrossRef]
7. Laddha AP, Kulkarni YA. Pharmacokinetics, pharmacodynamics, toxicity, and formulations of daidzein: An important isoflavone. Phytother Res 2023;37:2578–604. [CrossRef]
8. Yamaguchi S, Kuroyanagi H, Milsom JW, Sim R, Shimada H. Venous anatomy of the right colon: Precise structure of the major veins and gastrocolic trunk in 58 cadavers. Dis Colon Rectum 2002;45:1337–40. [CrossRef]
9. Bademci R, Erdoğan MA, Kara AY, Yiğittürk G, Erbaş O. Therapeutic effects of vitamin D on acetic acid-induced colitis in rats. Acta Cir Bras 2020;35:e202000404. [CrossRef]
10. Dönder Y, Arikan TB, Baykan M, Akyüz M, Öz AB. Effects of quercitrin on bacterial translocation in a rat model of experimental colitis. Asian J Surg 2018;41:543–50. [CrossRef]
11. Uraz S, Tahan G, Aytekin H, Tahan V. N-acetylcysteine expresses powerful anti-inflammatory and antioxidant activities resulting in complete improvement of acetic acid-induced colitis in rats. Scand J Clin Lab Invest 2013;73:61–6. [CrossRef]
12. Tahan G, Gramignoli R, Marongiu F, Aktolga S, Cetinkaya A, Tahan V, et al. Melatonin expresses powerful anti-inflammatory and antioxidant activities resulting in complete improvement of acetic-acid-induced colitis in rats. Dig Dis Sci 2011;56:715–20. [CrossRef]
13. Danciu C, Avram S, Pavel IZ, Ghiulai R, Dehelean CA, Ersilia A, et al. Main isoflavones found in dietary sources as natural anti-inflammatory agents. Curr Drug Targets 2018;19:841–53. [CrossRef]
14. Křížová L, Dadáková K, Kašparovská J, Kašparovský T. Isoflavones. Molecules 2019;24:1076. [CrossRef]
15. Wu ZY, Sang LX, Chang B. Isoflavones and inflammatory bowel disease.

World J Clin Cases 2020;8:2081–91. [CrossRef]
16. Al-Nakkash L, Kubinski A. Soy isoflavones and gastrointestinal health. Curr Nutr Rep 2020;9:193–201. [CrossRef]
17. Gao X, Fan W, Tan L, Shi Y, Ding C, Liu S, et al. Soy isoflavones ameliorate experimental colitis by targeting ERα/NLRP3 inflammasome pathways. J Nutr Biochem 2020;83:108438. [CrossRef]
18. Atiq A, Shal B, Naveed M, Khan A, Ali J, Zeeshan S, et al. Diadzein ameliorates 5-fluorouracil-induced intestinal mucositis by suppressing oxidative stress and inflammatory mediators in rodents. Eur J Pharmacol 2019;843:292–306. [CrossRef]
19. Skolmowska D, Głąbska D, Guzek D, Lech G. Association between dietary isoflavone intake and ulcerative colitis symptoms in Polish Caucasian individuals. Nutrients 2019;11:1936. [CrossRef]
20. Moonka R, Carmichael JC. Anorectal anatomy and physiology. In: Fundamentals of anorectal surgery. Cham: Springer International Publishing; 2018. p. 1–21. [CrossRef]
21. Rantin FT, Kalinin AL, Monteiro DA. The cardiovascular system. In: Biology and physiology of freshwater Neotropical fish. 2020. p. 185–216. [CrossRef]
22. Cercek A, Cusack JC Jr, Ryan DP. Treatment of peritoneal carcinomatosis of colorectal origin. Am Soc Clin Oncol Educ Book 2015:e208–11. [CrossRef]
23. Türkiye Kanserle Savaş Vakfı. Kanser Gündemi - karsinomatozis peritonei. Available at: https://www.kanservakfi.com/kanser-gundemi-dergisi/peritoneal-karsinomatozis-11-1/ Accessed April 22, 2025
24. Pletcher E, Gleeson E, Labow D. Peritoneal cancers and hyperthermic intraperitoneal chemotherapy. Surg Clin North Am 2020;100:589–613. [CrossRef]
25. Toprak V, Akalın SA, Öcal E, Çavuş Y, Deveci E. Effects of daidzein on rat ovary against ischemia-reperfusion. Acta Cir Bras 2023;38:e384423. [CrossRef]
26. Durgun C, Aşır F. Daidzein alleviated the pathologies in intestinal tissue against ischemia-reperfusion. Eur Rev Med Pharmacol Sci 2023;27:1487–93.
27. Abron JD, Singh NP, Price RL, Nagarkatti M, Nagarkatti PS, Singh UP. Genistein induces macrophage polarization and systemic cytokine to ameliorate experimental colitis. PLoS One 2018;13:e0199631. [CrossRef]
28. Akıncı O, Tosun Y, Kepil N. The effect of genistein on anastomotic healing in intestinal ischemia/reperfusion injury. J Surg Res 2022;280:389–95. [CrossRef]
29. Tie L, An Y, Han J, Xiao Y, Xiaokaiti Y, Fan S, et al. Genistein accelerates refractory wound healing by suppressing superoxide and FoxO1/iNOS pathway in type 1 diabetes. J Nutr Biochem 2013;24:88–96. [CrossRef]
30. Oztürk A, Ilman AA, Sağlam H, Yalçinkaya U, Aykut S, Akgöz S, et al. The effects of phytoestrogens on fracture healing: Experimental research in New Zealand white rabbits. Ulus Travma Acil Cerrahi Derg 2008;14:21–7.
31. Jurjus AR, Khoury NN, Reimund JM. Animal models of inflammatory bowel disease. J Pharmacol Toxicol Methods 2004;50:81–92. [CrossRef]
32. Sheibani S, Gerson LB. Chemical colitis. J Clin Gastroenterol 2008;42:115–21.[CrossRef]
33. Mazzuoli S, Guglielmi FW, Antonelli E, Salemme M, Bassotti G, Villanacci V. Definition and evaluation of mucosal healing in clinical practice. Dig Liver Dis 2013;45:969–77. [CrossRef]
34. Flynn A, Kane S. Mucosal healing in Crohn's disease and ulcerative colitis: What does it tell us? Curr Opin Gastroenterol 2011;27:342–5. [CrossRef]
35. Seidelin JB, Coskun M, Nielsen OH. Mucosal healing in ulcerative colitis: Pathophysiology and pharmacology. Adv Clin Chem 2013;59:101–23. [CrossRef]
36. Valatas V, Bamias G, Kolios G. Experimental colitis models: Insights into the pathogenesis of inflammatory bowel disease and translational issues. Eur J Pharmacol 2015;759:253–64. [CrossRef]
37. Boal Carvalho P, Cotter J. Mucosal healing in ulcerative colitis: A comprehensive review. Drugs 2017;77:159–73. [CrossRef]
38. Han G, Ceilley R. Chronic wound healing: A review of current management and treatments. Adv Ther 2017;34:599–610. [CrossRef]
39. Osterman MT. Mucosal healing in inflammatory bowel disease. J Clin Gastroenterol 2013;47:212–21. [CrossRef]
40. Skovsen AP, Korgaard Jensen T, Gögenur I, Tolstrup MB. Small bowel anastomosis in emergency surgery. World J Surg 2024;48:341–9. [CrossRef]
41. Fanizza J, Bencardino S, Allocca M, Furfaro F, Zilli A, Parigi TL, et al. Inflammatory bowel disease and colorectal cancer. Cancers (Basel) 2024;16:2943. [CrossRef]

DENEYSEL ÇALIŞMA - *ÖZ*

Daidzeinin kolit modelinde anastomoz iyileşmesi üzerine etkisi

AMAÇ: Bu deneysel çalışmada, sıçanlarda oluşturulan kolit modelinde yapılan kolon anastomozu üzerinde enteral yolla verilen daidzein molekülünün etkilerinin araştırılması amaçlandı.
GEREÇ VE YÖNTEM: Çalışmada toplam 48 adet erkek Wistar albino sıçan kullanıldı. Sıçanlar rastgele olarak altışarlı sekiz gruba ayrıldı. Rektal kateter aracılığıyla, gruplarına göre su ya da %4'lük asetik asit solüsyonu verilerek kolit oluşturuldu. Beşinci gün tüm sıçanlara segmenter kolon rezeksiyonu ve uç uca kolo-kolonik anastomoz uygulandı. Anastomoz sonrasında dört gruba oral yolla daidzein verildi. Sıçanlara postoperatif 3. ve 7. günlerde relaparotomi yapılarak anastomozlu kolon segmenti çıkarıldı. Anastomoz patlama basıncı ile anastomoz dokusunda süperoksit dismutaz, glutatyon peroksidaz ve hidroksiprolin düzeyleri ölçüldü. Ayrıca histopatolojik hasar skorları değerlendirildi.
BULGULAR: Erken ve geç postoperatif dönemde, kolit oluşturulan veya oluşturulmayan gruplarda daidzein verilmesinin hidroksiprolin düzeyi ve anastomoz patlama basıncı açısından anastomoz güvenliğine istatistiksel olarak anlamlı bir etkisi gözlenmedi (p>0.05). Daidzein, anastomoz dokusundaki süperoksit dismutaz ve glutatyon peroksidaz düzeylerini azaltıcı yönde bir etki göstermedi (p>0.05). Geç postoperatif dönemde, kolit oluşturulmayan gruplarda daidzein molekülünün histopatolojik hasar skorları açısından olumlu etkisi olduğu gözlendi.
SONUÇ: Deneysel kolit modeli oluşturulan sıçanlarda enteral daidzein uygulamasının kolon anastomozu iyileşmesi üzerine anlamlı istatistiksel bir etkisi bulunmamıştır.

Anahtar sözcükler: Anastomoz iyileşmesi; daidzein; deneysel kolit; izoflavonoidler; inflamatuvar bağırsak hastalığı.

Ulus Travma Acil Cerrahi Derg 2025;31(5):431-437 DOI: 10.14744/tjtes.2025.66339