ORIGINAL ARTICLE

A rare cause of appendicitis in adults: parasitic appendicitis

Abidin Tüzün,[1] Cemalettin Durgun,[2] Erkan Dalbaşı[3]

[1]Department of General Surgery, University of Health Sciences Diyarbakır Gazi Yaşargil Health Application and Research Center, Diyarbakır-*Türkiye*

[2]Department of General Surgery, Dağkapı State Hospital, Diyarbakır-*Türkiye*

[3]Department of General Surgery, Private Bağlar Hospital, Diyarbakır-*Türkiye*

ABSTRACT

BACKGROUND: Acute appendicitis (AA) is the most common indication for emergency surgery in general surgery worldwide, with peak incidence occurring in the second and fifth decades of life. The main symptoms include nausea, vomiting, and pain that typically begins around the umbilicus and migrates to the lower right quadrant. While the most frequent cause is fekaloids, intestinal parasites, tumors, and fruit seeds may also rarely contribute to the etiology of appendicitis. The aim of this study was to determine the incidence of parasitic infections in the etiology of AA, along with associated demographic and histopathological findings in adult patients who underwent appendectomy.

METHODS: The records of 10,658 patients over the age of 15 who underwent appendectomy between January 2011 and January 2023 were retrospectively reviewed. Based on histopathological findings, 114 patients who underwent appendectomy due to parasitic infestation were included in the study.

RESULTS: According to the pathology results, a total of 114 patients underwent appendectomy due to parasitic infestation. Of these, 53 (46.5%) were female and 61 (53.5%) were male. Histopathological examination revealed that 70 cases (61.4%) were diagnosed as acute appendicitis, 22 (19.3%) as suppurative, 15 (13.2%) as gangrenous, and seven (6.1%) as perforated appendicitis. In terms of etiology, *Taenia saginata* was identified in four patients (3.5%), *Ascaris lumbricoides* in two patients (1.8%), and *Enterobius vermicularis* (EV) eggs or parasites in 108 patients (94.7%).

CONCLUSION: Parasitic infections, particularly *Enterobius vermicularis*, may contribute to the development of acute appendicitis, although their exact role in the pathogenesis remains unclear. In our study, *Enterobius vermicularis* was the most common cause of parasite-related appendicitis.

Keywords: Appendicitis; parasitic infestation; emergency surgery.

INTRODUCTION

Acute appendicitis (AA) is the most common cause of emergency surgery in general surgery practice worldwide and is a frequent reason for emergency department admissions due to abdominal pain. It most commonly occurs between the second and fifth decades of life.[1,2] Diagnosis is based on a combination of medical history, physical examination, laboratory tests, and imaging modalities such as ultrasonography and computed tomography. The main symptoms include nausea, vomiting, and pain that typically begins around the umbilicus and localizes to the right lower quadrant. Fever and loss of appetite may also be present in some cases.[3] Lymphoid hyperplasia resulting from obstruction of the appendix lumen plays a key role in the etiology. While fekaloids are the most common cause, intestinal parasites, tumors, and fruit seeds

Cite this article as: Tüzün A, Durgun C, Dalbaşı E. A rare cause of appendicitis in adults: parasitic appendicitis. Ulus Travma Acil Cerrahi Derg 2025;31:445-449.

Address for correspondence: Abidin Tüzün

Department of General Surgery, University of Health Sciences Diyarbakır Gazi Yaşargil Health Application and Research Center, Diyarbakır, Türkiye

E-mail: atuzun_1@hotmail.com

Ulus Travma Acil Cerrahi Derg 2025;31(5):445-449 DOI: 10.14744/tjtes.2025.34237

Submitted: 13.12.2024 Revised: 26.02.2025 Accepted: 23.03.2025 Published: 05.05.2025

OPEN ACCESS This is an open access article under the CC BY-NC license (http://creativecommons.org/licenses/by-nc/4.0/).

can also rarely contribute to appendicitis.[4] Among parasitic causes, *Enterobius vermicularis* is the most frequently identified organism in AA patients, although Schistosoma species, Taenia species, and Ascaris lumbricoides have also been reported. The prevalence of parasitic appendicitis varies by region, ranging from 0.2% to 41.8% worldwide.[5,6] The aim of this study was to determine the incidence of parasitic infections in the etiology of appendicitis, as well as the demographic and histopathological characteristics of adult patients who underwent surgery for AA.

MATERIALS AND METHODS

The records of 10,658 patients over the age of 15 who underwent appendectomy at the General Surgery Clinic of Diyarbakır Gazi Yaşargil Health Application and Research Center between January 2011 and January 2023 were retrospectively reviewed. The diagnosis of acute appendicitis was based on physical examination, imaging methods (whole-abdominal ultrasonography or computed tomography), and laboratory investigations including complete blood count and biochemical tests. Surgeries were performed either via open or laparoscopic approach, depending on the preference of the surgical team. By evaluating the histopathological data, 114 patients who underwent appendectomy due to parasitic infestation were identified and included in the study. The following variables were assessed: patients' age, gender, surgical method, type of parasite associated with appendicitis, white blood cell (WBC) count, eosinophil counts at presentation, and histopathological diagnosis of the appendectomy specimens.

The investigation protocol complied with the principles of the Declaration of Helsinki and was approved by the Ethics Committee of Health Sciences University Diyarbakır Gazi Yaşargil Training and Research Hospital on 05.07.2024, with approval number 125.

Statistical Analysis

All patient data were recorded and analyzed using SPSS version 25 (IBM, Chicago, IL, USA). Categorical variables were expressed as mean ± standard deviation and percentages.

RESULTS

According to the pathology results, 114 patients underwent appendectomy due to parasitic infestation, while 10,544 patients underwent appendectomy for other etiologic causes. Among the patients who underwent appendectomy for non-parasitic reasons, 4,328 (41.0%) were female and 6,216 (59%) were male. The mean age of this group was 30.4±13.7 years, with a minimum age of 15, a maximum of 90, and a median age of 27 years. In the parasitic infestation group, 53 patients (46.5%) were female and 61 (53.5%) were male. The mean age was 28.8±7.6 years, and the median age was 19 years. The mean WBC count was 12.4±1.3/μL and the mean eosinophil count was 480.2±81.2/μL. The median WBC and eosinophil counts were 13.1/μL and 462.8/μL, respectively. Histopathological examination of the appendectomy specimens revealed the following diagnoses: 70 cases (61.4%) were acute appendicitis, 22 (19.3%) were suppurative, 15 (13.2%) were gangrenous, and seven (6.1%) were perforated appendicitis. Lymphoid hyperplasia was observed in 24 patients (21.1%). In terms of etiology, Taenia saginata was identified in four patients (3.5%), Ascaris lumbricoides in two patients (1.8%), and *Enterobius vermicularis* (EV) eggs or parasites in 108 patients (94.7%). Of the patients, 81 (71.0%) underwent laparoscopic appendectomy, while 33 (29.0%) underwent open surgery. The mean appendix diameter was 8.5±5.2 mm, and the

Table 1. Demographic data, laboratory values, and histopathological findings of patients

Gender	
Female	53 (46.5%)
Male	61 (53.5%)
Age	
Mean ± Standard Deviation	28.8±7.6
Minimum - Maximum	15-48
Median	19
Operation Method	
Laparoscopic	81 (71.0%)
Open	33 (29.0%)
White Blood Cell Count (WBC)	
Mean ± Standard Deviation	12.4±1.3
Minimum - Maximum	5.2-20.3
Median	13.1
Eosinophil Count (μL)	
Mean ± Standard Deviation	480.2±81.2
Minimum - Maximum	324.2-892.6
Median	462.8
Histopathological Findings	
Acute Appendicitis	70 (61.4%)
Suppurative Appendicitis	22 (19.3%)
Gangrenous Appendicitis	15 (13.2%)
Perforated Appendicitis	7 (6.1%)
Lymphoid Hyperplasia	24 (21.1%)
Parasites and Fecaloid in Lumen	17 (14.9%)
Appendix Length (mm)	72.2±52.4
Appendix Diameter (mm)	8.5±5.2
Histopathologic	
Diagnosis	
Enterobius vermicularis	108 (94.7%)
Taenia saginata	4 (3.5%)
Ascaris lumbricoides (Ascariasis)	2 (1.8%)

mean length was 72.2±52.4 mm. Parasites and fecaloids were found together in the appendix lumen in 17 patients (14.9%). Demographic data, laboratory values, and histopathological findings of patients who underwent appendectomy due to parasitic infestation are summarized in Table 1. Pathological images of the parasites are presented in Figures 1 and 2.

DISCUSSION

Although parasitic infections are more common in underdeveloped and developing countries, they remain a global public health concern. *Enterobius vermicularis*, also known as Oxyuris, is one of the most common nematodes, particularly affecting pediatric and young adult populations. Parasitic infections are more common in rural areas with limited access to clean water, as well as in childcare facilities and elderly care homes where maintaining personal hygiene is challenging.[7,8] The primary mode of transmission is through consumption of food or drinking water contaminated with parasite eggs. After ingestion, the eggs hatch and mature in the human gastrointestinal tract, typically settling in the cecum.[9]

A review of the literature indicates that parasitic infections are most prevalent in Africa (8%) and least common in the Americas (2%).[8] In a meta-analysis conducted by Taghipou et al.,[10] EV was identified as the causative agent in 2,983 (2.89%) of 103,195 appendectomy specimens. Zakaria et al.[11] reviewed 21 studies and reported a parasitic infection rate of 4.5%. Similarly, in a study by Issin et al.,[12] parasitic infestation was detected in 56 (0.6%) of 9,480 appendectomy specimens. Of these, 80% were caused by EV, while Taenia subspecies were identified in 20% of the cases. In the literature, the highest prevalence of parasite-related appendicitis was reported in Libya at 68%, while the lowest was reported in Iran at 0.22%.[13,14] In our study, we found the rate of parasite-related appendicitis to be 1.06%. Although this rate appears low compared to meta-analyses, it is consistent with studies involving a similar number of patients. Additionally, we observed an association between fecalomas and parasites in 14.9% of cases.

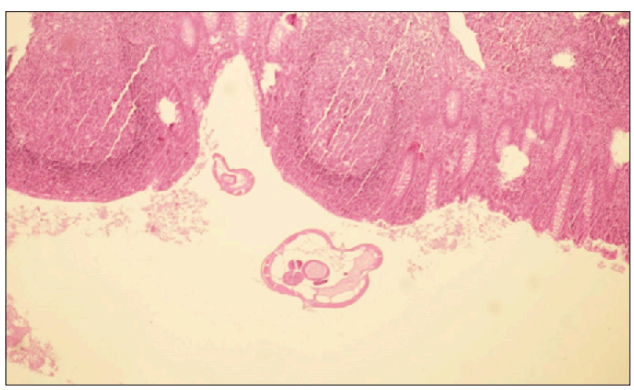

Figure 1. *Enterobius vermicularis* in the lumen of the appendix (Hematoxylin and Eosin staining [H&E], magnification ×100).

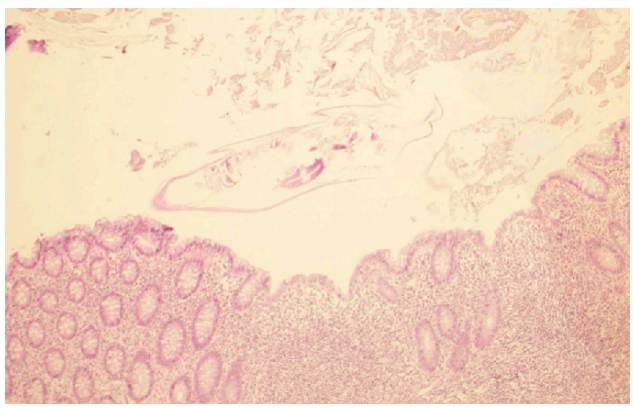

Figure 2. *Ascaris lumbricoides* in the lumen of the appendix (Hematoxylin and Eosin staining [H&E], magnification ×100).

Previous studies have identified EV as the most common parasitic agent found in the appendix, followed by Taenia species as the second most common. Other parasites, such as Entamoeba histolytica, Schistosoma species, and Ascaris lumbricoides, have also been reported as causative agents in a few studies.[15-17] In our study, EV was the most frequently identified parasite, in line with the literature, followed by Taenia species. Ascaris lumbricoides was observed in only two patients.

The relationship between parasitic infection and the pathogenesis of appendicitis is still unclear, and the association between *E. vermicularis* and appendicitis is still controversial. It is not yet known whether the parasite directly initiates inflammation. Parasitic infections can lead to various forms of appendicitis, including acute, chronic, gangrenous, perforated, or suppurative types. These outcomes may result from the parasite itself or its eggs obstructing the lumen. Histopathologically, parasitic appendicitis is most often associated with acute inflammation and lymphoid hyperplasia. In our study, similar findings were observed, with lymphoid hyperplasia detected in 21.05% of cases, consistent with previous reports.[18-20]

Dunn James reported that elevated eosinophil levels are statistically significant in parasitic infections, although eosinophilia is considered an expected finding rather than a definitive diagnostic criterion.[21] Fleming et al.[22] highlighted the importance of eosinophilia in predicting the presence of *E. vermicularis* in pediatric patients with clinically suspected acute appendicitis. In our study, eosinophilia was observed in all patients with parasitic appendicitis confirmed by pathology. This finding suggests that eosinophilia may also serve as an indicator in adult patients with parasite-related appendicitis.

It is well established that acute appendicitis is more common in children and young adults. Hardin reported that the highest incidence occurs between the ages of 10 and 30, while Humes et al.[23] found it to be most frequent between 10 and 20 years of age.[24] In our study, the mean age of patients who underwent appendectomy for both parasitic and non-parasitic causes was consistent with the findings in the literature.

Appendicitis caused by parasitic infections is more frequently seen in children and young adults, particularly in rural areas and regions with limited access to clean water.[25]

Currently, the laparoscopic approach is increasingly favored for the surgical treatment of acute appendicitis. Some studies suggest that antibiotic therapy may be effective in selected cases and could help avoid unnecessary surgical intervention. In patients with histopathologically confirmed parasitic appendicitis, appropriate antiparasitic treatment should be initiated, and family members should be screened for parasitic infections. In this way, future complications that may require surgery can be prevented. The diagnosis of enterobiasis is usually based on anamnesis. Recurrent, non-persistent perianal itching is a typical symptom. In cases of heavy parasite load, worms may be visibly moving on clothing, bed linens, or in stool. The eggs are very small and can only be observed under a microscope (50-60 µm × 20-30 µm). An increased eosinophil count may be indicative of parasitic infestation.[1,26,27] In our study, 71.0% of the patients underwent laparoscopic surgery. Following diagnosis, antiparasitic treatment was initiated for all patients, and their family members were referred to the infectious diseases outpatient clinic for screening.

Limitations

The retrospective and single-center design of this study limits the generalizability of the findings to broader populations and different geographic regions. Additionally, the absence of data on patients' sociodemographic characteristics, living conditions, and environmental risk factors hindered a more comprehensive evaluation of the etiology and risk factors associated with parasitic infestation.

CONCLUSION

Parasitic infections, particularly *Enterobius vermicularis*, can be considered among the etiological factors of acute appendicitis; however, their exact role in pathogenesis remains unclear. In our study, the incidence of parasite-related appendicitis was found to be 1.06%, with *E. vermicularis* identified as the most common causative agent. To effectively control such infections, screening of family members and implementation of appropriate antiparasitic treatment may be crucial steps in preventing recurrence and enhancing public health protection strategies.

Ethics Committee Approval: This study was approved by the Health Sciences University Diyarbakır Gazi Yaşargil Training and Research Hospital Non-Interventional Clinical Research Ethics Committee (Date: 05.07.2024, Decision No: 125).

Peer-review: Externally peer-reviewed.

Authorship Contributions: Concept: A.T., E.D., C.D.; Design: A.T., C.D.; Supervision: A.T., C.D., E.D.; Resource: A.T., E.D., C.D.; Materials: A.T., Data collection and/or processing: A.T., E.D.; Analysis and/or interpretation: A.T., E.D., C.D.; Literature review: A.T., E.D., C.D.; Writing: A.T., E.D.; Critical review: A.T., E.D., C.D.

Conflict of Interest: None declared.

Financial Disclosure: The author declared that this study has received no financial support.

REFERENCES

1. Dalbaşı E, Akgül ÖL. Are average platelet volume, red cell distribution width and platelet distribution width guiding markers for acute appendicitis treatment options? Int J Clin Pract 2021;75:e14232. [CrossRef]
2. Andersson RE. Meta-analysis of the clinical and laboratory diagnosis of appendicitis. Br J Surg 2004;91:28–37. [CrossRef]
3. Moris D, Paulson EK, Pappas TN. Diagnosis and management of acute appendicitis in adults: A review. JAMA 2021;326:2299–311. [CrossRef]
4. Yabanoğlu H, Aytaç HÖ, Türk E, Karagülle E, Calışkan K, Belli S, et al. Parasitic infections of the appendix as a cause of appendectomy in adult patients. Turkiye Parazitol Derg 2014;38:12–6. [CrossRef]
5. Thanikachalam MP, Kasemsuk Y, Mak JW, Sharifah Emilia TS, Kandasamy P. A study of parasitic infections in the luminal contents and tissue sections of appendix specimens. Trop Biomed 2008;25:166–72.
6. Arca MJ, Gates RL, Groner JI, Hammond S, Caniano DA. Clinical manifestations of appendiceal pinworms in children: An institutional experience and a review of the literature. Pediatr Surg Int 2004;20:372–5. [CrossRef]
7. Stepek G, Buttle DJ, Duce IR, Behnke JM. Human gastrointestinal nematode infections: Are new control methods required? Int J Exp Pathol 2006;87:325–41. [CrossRef]
8. Panidis S, Paramythiotis D, Panagiotou D, Batsis G, Salonikidis S, Kaloutsi V, et al. Acute appendicitis secondary to Enterobius vermicularis infection in a middle-aged man: A case report. J Med Case Rep 2011;5:559. [CrossRef]
9. Gümüş S, Söğütçü N. Parasitic appendicitis in 14.797 cases: A retrospective cohort study. Turkiye Parazitol Derg 2021;45:113–6. [CrossRef]
10. Taghipour A, Olfatifar M, Javanmard E, Norouzi M, Mirjalali H, Zali MR. The neglected role of Enterobius vermicularis in appendicitis: A systematic review and meta-analysis. PLoS One 2020;15:e0232143. [CrossRef]
11. Zakaria OM, Zakaria HM, Daoud MY, Al Wadaani H, Al Buali W, Al-Mohammed H, et al. Parasitic infestation in pediatric and adolescent appendicitis: A local experience. Oman Med J 2013;28:92–6. [CrossRef]
12. Issin G, Demir F, Simsek HA, Cagatay DV, Tayfur M, Kandemir A, et al. Seeds or parasites? Clinical and histopathological features of seeds and parasites in the appendix. Turk Patoloji Derg 2023;39:42–54. [CrossRef]
13. Fadiel MM, Elsamad NAA, Younis EZ. Parasitic infection in surgically removed appendices from patients in Al-Jalal Hospital Benghazi, Libya. Biomed J Sci Tech Res 2019;17:12967–72. [CrossRef]
14. Mardani A, Feizi F, Fakhar M, Beyranvand HB, Farrokhi M, Abbasi M, et al. Enterobius vermicularis infection among appendectomy specimens in Qom Province, Central Iran: A retrospective study. Comp Clin Pathol 2017;26:1213–9. [CrossRef]
15. Altun E, Avci V, Azatcam M. Parasitic infestation in appendicitis. A retrospective analysis of 660 patients and brief literature review. Saudi Med J 2017;38:314–8. [CrossRef]
16. Da Silva DF, da Silva RJ, da Silva MG, Sartorelli AC, Rodrigues MA. Parasitic infection of the appendix as a cause of acute appendicitis. Parasitol Res 2007;102:99–102. [CrossRef]
17. Eslahi AV, Olfatifar M, Houshmand E, Abdoli A, Bijani B, Hashemipour S, et al. Parasites in surgically removed appendices as a neglected public health concern: A systematic review and meta-analysis. Pathog Glob Health 2022;116:341–55. [CrossRef]
18. Hammood ZD, Salih AM, Mohammed SH, Kakamad FH, Salih KM, Omar DA, et al. Enterobius vermicularis causing acute appendicitis, a case report with literature review. Int J Surg Case Rep 2019;63:153–6. [CrossRef]

19. Akkapulu N, Abdullazade S. Is Enterobius vermicularis infestation associated with acute appendicitis? Eur J Trauma Emerg Surg 2016;42:465–70. [CrossRef]
20. Karatepe O, Adas G, Tukenmez M, Battal M, Altiok M, Karahan S. Parasitic infestation as cause of acute appendicitis. G Chir 2009;30:426–8.
21. Dunn JCY. Appendicitis. In: Coran AG, Caldamone A, Adzick NS, Krummel TM, Laberge JM, Shamberger R, editors. Pediatric Surgery. 7th ed. 2012:1255–63. [CrossRef]
22. Fleming CA, Kearney DE, Moriarty P, Redmond HP, Andrews EJ. An evaluation of the relationship between Enterobius vermicularis infestation and acute appendicitis in a paediatric population--A retrospective cohort study. Int J Surg 2015;18:154–8. [CrossRef]
23. Humes DJ, Simpson J. Acute appendicitis. BMJ 2006;333:530–4. [CrossRef]
24. Hardin DM Jr. Acute appendicitis: Review and update. Am Fam Physician 1999;60:2027–34.
25. Chhetri S, Al Mamari AH, Al Awfi MM, Al Khaldi NHN, Abed NM, Pandak N, et al. Enterobius vermicularis related acute appendicitis: A case report and review of the literature. Infect Dis Rep 2023;15:417–24. [CrossRef]
26. Wendt S, Trawinski H, Schubert S, Rodloff AC, Mössner J, Lübbert C. The diagnosis and treatment of pinworm infection. Dtsch Arztebl Int 2019;116:213–9. [CrossRef]
27. Harman Kamali G, Ulusoy C, Nikolovski A, Eğin S, Kamalı S. Uncommon causes of acute appendicitis: Retrospective analysis of 6785 histopathological findings in a tertiary center. Ulus Travma Acil Cerrahi Derg 2022;28:1708–15. [CrossRef]

ORİJİNAL ÇALIŞMA - *ÖZ*

Yetişkinlerde apandisitin nadir bir nedeni: Parazitik apandisit

AMAÇ: Akut apandisit (AA), dünya genelinde genel cerrahi pratiğinde en sık görülen acil cerrahi nedenidir. En sık ikinci ve beşinci dekatlarda görülür. Başlıca semptomlar bulantı, kusma ve göbek çevresinde başlayıp sağ alt kadrana yerleşen ağrıdır. En sık neden fekaloidler olmakla birlikte, bağırsak parazitleri, tümörler ve meyve çekirdekleri de nadiren apandisit etiyolojisinde yer almaktadır. Bu çalışmanın amacı, AA nedeniyle ameliyat edilen erişkin hastalarda etiyolojide paraziter enfeksiyon insidansını, hastaların demografik ve histopatolojik bulgularını belirlemektir.
GEREÇ VE YÖNTEM: Ocak 2011 ile Ocak 2023 tarihleri arasında apendektomi yapılan 15 yaş üstü 10658 hastanın dosyaları retrospektif olarak incelendi. Hastaların histopatolojik verileri incelenerek parazit enfestasyonu nedeniyle apendektomi yapılan 114 hasta çalışmaya dahil edildi.
BULGULAR: Patoloji sonuçlarına göre, parazit enfestasyonu nedeniyle apendektomi yapılan hasta sayısı 114 idi. Hastaların 53'ü (%46.5) kadın, 61'i (%53.5) erkekti. Histopatolojik incelemede apendektomi materyallerinin 70'i (%61.4) akut, 22'si (%19.3) süpüratif, 15'i (%13.2) gangrenöz ve 7'si (%6.1) perfore apandisit olarak teşhis edildi. Etiyolojide 4 (%3.5) hastada *Taenia saginata*, 2 (%1.8) hastada *Ascariasis* ve 108 (%94.7) hastada *Enterobius vermicularis* (EV) yumurta veya parazitleri gözlendi.
SONUÇ: Parazit enfeksiyonları, özellikle *Enterobius vermicularis* akut apandisite sebep olabilir. Ancak patogenezdeki rolleri belirsizliğini korumaktadır. Çalışmamızda parazitle ilişkili apandisitin en sık sebebi *Enterobius vermicularis* idi.

Anahtar sözcükler: Apandisit, parazit enfestasyonu, acil cerrahi

Ulus Travma Acil Cerrahi Derg 2025;31(5):445-449 DOI: 10.14744/tjtes.2025.34237