ORIGINAL ARTICLE

Efficacy of endoluminal vacuum therapy in managing anastomotic leakage after neoadjuvant therapy in rectal cancer patients

Selçuk Kaya,[1] Muhammet Kerim Çevik,[1] Omar Alomari,[2] Muhammed Edib Mokresh,[2] Hasan Fehmi Kucuk[1]

[1]Department of General Surgery, University of Health Sciences Kartal Dr. Lutfi Kirdar City Hospital, Istanbul-*Türkiye*
[2]Hamidiye International School of Medicine, University of Health Sciences, Istanbul-*Türkiye*

ABSTRACT

BACKGROUND: Anastomotic leakage is a significant complication following colorectal surgery, associated with increased morbidity and mortality. Endoluminal vacuum therapy (EVT) has emerged as a promising treatment option for managing such leaks, although standardized guidelines are still lacking. This study aimed to evaluate the efficacy of EVT in managing anastomotic leakage after colorectal surgery, focusing on outcomes and contributing factors.

METHODS: A retrospective analysis was conducted on 25 patients who underwent EVT for anastomotic leakage between 2018 and 2022 at our institution. Data collected included patient demographics, surgical details, timing of EVT initiation, number of EVT sessions, complications, and outcomes such as leak closure and subsequent surgical interventions. Statistical analyses were performed using Python packages.

RESULTS: The study cohort had a mean age of 56.84 years, with 68% being male. All patients received neoadjuvant therapy followed by low anterior resection and diverting ileostomy; 80% underwent open surgery. EVT was initiated for postoperative anastomotic leakage, with a mean hospital stay of 14.16 days and an average initiation time of 16.16 days post-surgery. Ileostomy closure was performed in 14 patients after endosponge therapy. The overall EVT success rate was 68%, with a mean follow-up period of 30.7 months for those who underwent ileostomy closure. No significant relationship was found between patients' age and the time to first EVT after anastomotic leakage (p=0.52). However, a significant association was observed between the timing of the first EVT and the duration of EVT termination (p=0.0003).

CONCLUSION: EVT is a viable option for managing anastomotic leakage following colorectal surgery, demonstrating high closure rates and low associated morbidity. Early initiation of EVT appears to be crucial for optimizing treatment outcomes. Further prospective studies are needed to establish standardized protocols and confirm the long-term benefits of EVT in this challenging clinical context.

Keywords: Anastomotic leakage; colorectal surgery; endo-sponge; rectal cancer.

INTRODUCTION

Rectal cancer is one of the leading causes of cancer-related deaths worldwide. Early diagnosis and timely treatment are essential, as the disease carries high rates of morbidity and mortality. One of the most feared complications following neoadjuvant chemoradiotherapy (CRT) in rectal cancer patients is anastomotic leakage.[1] This complication can lead to

Cite this article as: Kaya S, Çevik MK, Alomari O, Mokresh ME, Küçük HF. Efficacy of endoluminal vacuum therapy in managing anastomotic leakage after neoadjuvant therapy in rectal cancer patients. Ulus Travma Acil Cerrahi Derg 2025;31:450-457.

Address for correspondence: Selçuk Kaya
Department of General Surgery, University of Health Sciences, Kartal Dr. Lütfi Kırdar Training and Research Hospital, İstanbul, Türkiye
E-mail: selcukkaya_36@hotmail.com

Ulus Travma Acil Cerrahi Derg 2025;31(5):450-457 DOI: 10.14744/tjtes.2025.27078
Submitted: 22.12.2024 Revised: 26.02.2025 Accepted: 13.03.2025 Published: 05.05.2025
OPEN ACCESS This is an open access article under the CC BY-NC license (http://creativecommons.org/licenses/by-nc/4.0/).

adverse oncological and functional outcomes, including the potential need for a permanent stoma.[2,3] The rate of anastomotic leakage varies between 6% and 30% depending on several specific factors, with an average incidence of 11%.[4] Anastomotic leaks can present a broad spectrum of clinical manifestations, ranging from ileus to intra-abdominal sepsis. Delayed diagnosis can lead to serious complications, including sepsis, severe sepsis, and multiple organ failure. Due to compromised blood supply to the rectum, especially after radiotherapy (RT), most surgeons recommend the creation of a diverting ileostomy during rectal surgery.

To date, no standardized management protocol exists for the treatment of anastomotic leaks. Management is typically individualized and depends on factors such as the patient's age, comorbidities, clinical status, the location and extent of the anastomotic disruption, and the presence or absence of a diverting stoma.[5] Treatment approaches include traditional surgical interventions with variable success rates, as well as endoscopic techniques such as tissue adhesives, endoscopic clips, and self-expanding metal stents.[6]

Endoluminal vacuum therapy (EVT) (Endo-SPONGE®; B. Braun Medical BV) is an alternative to surgical procedures for managing anastomotic leakage.[7] This method aims to prevent pelvic infection and promote closure of the intracavitary space associated with the anastomotic leak, using an endoscopic approach.

EVT is a minimally invasive technique applied to anastomotic leaks in the gastrointestinal tract. It involves the use of an endosponge, a cylindrical polyurethane sponge connected to a drainage tube, which is attached to a vacuum system to provide continuous suction via an endoscopic vacuum-assisted device. The system includes an open-pore sponge with a drainage tube, a sponge pusher, silicone tube guides, and a drainage set. The setup is designed to evacuate leakage from the anastomotic cavity, prevent bacterial translocation, and support granulation tissue formation and healing.

Currently, EVT is used in the treatment of anastomotic leaks in many countries.[8,9] However, apart from a few observational studies offering limited data on its efficacy,[10,11] most of the available evidence comes from small case series.[12,13] Furthermore, these studies often involve heterogeneous case series, including both benign and malignant conditions. This has led to varying outcomes among studies regarding the efficacy of EVT.

In this study, EVT was applied to patients who developed anastomotic leakage after undergoing low anterior resection and diverting ileostomy following neoadjuvant therapy. The primary aim was to evaluate morbidity and mortality rates, length of hospital stay, the success rate of EVT, and subsequent closure of the diverting ileostomy in these patients.

MATERIALS AND METHODS

Patients who received neoadjuvant therapy followed by low anterior resection and diverting ileostomy and subsequently developed anastomotic leakage were included in this study, conducted at our General Surgery Clinic between March 2014 and March 2024. EVT was administered to all patients who met the eligibility criteria. The study was designed as a retrospective clinical analysis and was approved by the institutional Ethics Committee (Decision No: 2023/514/258/8). It was conducted in strict accordance with the ethical principles outlined in the Declaration of Helsinki.

Inclusion criteria for the study were as follows: patients aged 18 years or older with histopathologically confirmed rectal carcinoma who underwent sphincter-sparing surgery following neoadjuvant therapy. Eligible patients received either emergency or elective laparotomy or laparoscopic procedures involving colorectal or coloanal anastomoses with diverting ileostomy. All patients were required to be in good general condition, with stable vital signs and no signs of sepsis. Exclusion criteria included: patients under 18 years of age, those who did not receive neoadjuvant CRT, individuals with benign conditions requiring anastomosis, and patients who did not undergo diverting stoma formation following anastomosis.

Anastomotic leakage after rectal surgery was defined by one or more of the following: the presence of gastrointestinal content at the incision site during postoperative follow-up; drainage of colonic content from abdominal drains post-surgery; evidence of contrast leakage into the abdominal cavity on oral or rectal contrast-enhanced abdominal computed tomography (CT) scan; or visualization of anastomotic leakage during colonoscopic evaluation.

The clinical condition of patients with anastomotic leakage in the postoperative period was the primary factor guiding treatment decisions. Patients exhibiting unstable vital signs, signs of sepsis, or peritonitis were managed surgically, while stable patients were considered for EVT.

EVT Application Procedure

Patients underwent EVT under sedation using intravenous meperidine (0.5-1 mg/kg) and midazolam (2.5-5 mg) in the endoscopy unit. Following endoscopic evaluation to determine the size and depth of the bowel dehiscence, a cylindrical polyurethane sponge was cut and shaped to fit the dimensions of the cavity. The pouch was then irrigated with 0.9% NaCl solution to remove debris and purulent material. Next, an endoscope was advanced through a plastic tube. Using a colonoscope, the tube was guided to the deepest part of the cavity, after which the endoscope was withdrawn. Ultrasound gel was applied to the sponge, which was then inserted into the plastic tube. The sponge was carefully pushed into the cavity using a push rod while simultaneously withdrawing the plastic tube. Correct placement of the sponge within the cavity was confirmed via colonoscopy.

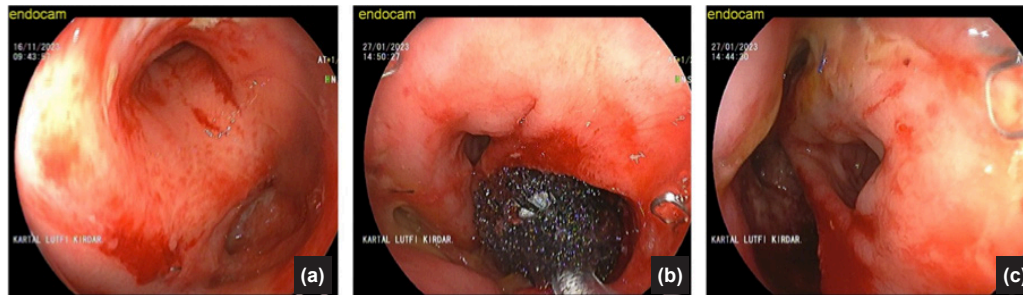

Figure 1. Endoluminal vacuum therapy process: **(a)** Anastomotic separation; **(b)** Endosponge placement; **(c)** Closure of the cavity following endosponge therapy.



Figure 2. Endosponge set.

The sponge was then connected via a drainage tube to a vacuum canister, which maintained a continuous negative pressure of 100-120 mmHg. This negative pressure facilitated the formation of clean granulation tissue in the intracavitary area and helped approximate the separated ends of the intestine. EVT treatment was continued until clean granulation tissue had formed, the depth of the pouch was reduced to less than 2 cm, and gastrointestinal continuity was restored. Depending on the initial presence of dense debris and pus, the sponge was changed every 3-4 days. Later, once clean granulation tissue began to form, the sponge was changed less frequently, no more than every 7 days, based on how firmly it adhered to the tissue. An example of the procedure is illustrated in Figure 1, and the appearance of the Endosponge set is shown in Figure 2.

Statistical Analysis

All statistical analyses and graphical visualizations were performed using Python (Python Software Foundation, Wilmington, DE, USA) packages including Pandas, Matplotlib, Seaborn, SciPy, Plotly Express, and Scikit-learn. Numerical data are presented as mean ± standard deviation, while categorical variables are reported as numbers and frequencies. The Pearson correlation coefficient (r) was used to assess linear relationships between continuous variables. Correlations among findings were evaluated, and statistical significance was set at a threshold of $p<0.05$.

RESULTS

A total of 25 patients were included in the study, with a mean age of 56.84 years. The gender distribution was 68% male (n=17) and 32% female (n=8). Among the study population, comorbidities included diabetes in three patients (12%), chronic obstructive pulmonary disease (COPD) in two (8%), atrial fibrillation in four (16%), coronary artery disease in four (16%), and hypertension in seven (28%). Additionally, five patients (20%) required transfer to the intensive care unit for postoperative monitoring (Table 1). All patients received neoadjuvant therapy followed by low anterior resection and diverting ileostomy. An open surgical technique was used in 20 patients (80%). EVT was initiated in patients who developed postoperative anastomotic leakage. The average length of hospital stay was 14.16 days, and EVT was started, on average, 16.16 days after the initial surgery. The mean number of EVT sessions performed per patient following anastomotic leakage was 7.28.

During follow-up, ileostomy closure was performed in 14 out of 25 patients (56%) following endosponge therapy. Hartmann's procedure was required in five patients (20%) due to the development of widespread peritonitis during EVT. Additionally, three patients (12%) developed strictures at the anastomotic site after endosponge therapy. Bougie dilation was successfully performed in two of these patients, while one patient required Hartmann's procedure due to unsuccessful dilation. Unfortunately, one patient developed an intra-abdominal abscess and sepsis, required intensive care, and ultimately passed away without undergoing further surgical intervention.

In one case (4%), the diverting ileostomy was not closed at the patient's request. In three patients (12%), distant organ metastases were detected during follow-up after endosponge therapy, and ileostomy closure was not performed. Thus, re-

Table 1. Distribution of general characteristics of patients

27. Characteristics	n=25
Gender	
Female	8 (32%)
Male	17 (68%)
Neoadjuvant	
Yes	25 (100%)
Open-Lap	
Lap	5 (20%)
Open	20 (80%)
ASA	
ASA 2	4 (16%)
ASA 3	16 (64%)
ASA 3 ICU	5 (20%)
Diabetes	
No	22 (88%)
Yes	3 (12%)
COPD	
No	23 (92%)
Yes	2 (8.0%)
Stroke	
No	25 (100%)
Atrial Fibrillation	
No	21 (84%)
Yes	4 (16%)
Coronary Artery Disease	
No	21 (84%)
Yes	4 (16%)
Hypertension	
No	18 (72%)
Yes	7 (28%)
Chronic Kidney Failure	
No	25 (100%)

gardless of ileostomy closure status, the overall EVT success rate in our study was 68% (17 patients). The average hospital stay for patients treated with endosponge therapy for anastomotic leakage was 14 days (Table 2).

No significant correlation was found between patient age and the time to first EVT after anastomotic leakage, number of endosponge sessions, or total duration of endosponge treatment (p=0.52, p=0.28, and p=0.91, respectively). Additionally, no significant relationship was found between the length of hospital stay and the number of EVT sessions performed (p=0.93). However, a significant association was observed between the timing of the first EVT session and the overall duration of EVT treatment (p=0.0003). Initiating EVT within

Table 2. Clinical outcomes following endoluminal vacuum therapy

Characteristics	n=25*
Length of hospital stay (days)	14.16 (10-35)
Surgery-Endosponge duration (days)	16.16 (14-94)
Separation percentage	0.42 (0-100)
Number of Endosponge	7.28 (2-16)
Endosponge related complications	
Anastomotic stricture	3 (12%)
Intra-abdominal abscess (ex-patient)	1 (4.0%)
Ileostomy not closed due to patient's request	1 (4.0%)
Ileostomy closure	13 (52%)
Hartmann surgery	6 (24%)
Oncological treatment ex (lung metastasis)	1 (4.0%)
Oncological treatment ex (liver metastasis)	2 (8.0%)
Duration of ileostomy closure (months)	9.1 (6-16)
Average follow-up period (months)	30.7 (7-48)

*Mean (SD); n (%).

10.23 days after the onset of anastomotic leakage was also associated with successful ileostomy closure (p=0.035).

The average follow-up period for patients whose ileostomies were closed after EVT was 30.7 months (ranging from 7 to 48 months). During this period, one patient required bougie dilation five times at 1-3-month intervals due to an anastomotic stricture following ileostomy closure. Follow-up for this patient is ongoing. On average, ileostomy closure occurred 9.01 months (range: 6-16 months) after the initiation of EVT treatment.

DISCUSSION

Colorectal cancer is the third most commonly diagnosed cancer worldwide and the fourth leading cause of cancer-related deaths globally.[14] It is estimated that 1.6 million new cases of colorectal cancer are diagnosed each year.[15] One of the most serious complications following rectal surgery is anastomotic leakage, with a reported incidence ranging from 2% to 36.3% and an associated mortality rate between 2% and 9%.[16] Anastomotic leakage is typically diagnosed between 5 and 8 days post-surgery, although rare cases have been reported as late as 30 days after the operation.[17] Complications such as intra-abdominal abscesses, wound infections, diffuse peritonitis, and sepsis following anastomotic leakage contribute to prolonged hospital stays, increased morbidity, and higher mortality rates.[18] Although early detection of anastomotic leakage remains a challenge for surgeons, it is critical for improving postoperative outcomes. Timely diagnosis of anastomotic leakage impacts the patient's length of hospital stay.[19]

Anastomotic leakage following surgery often necessitates varied surgical interventions depending on the severity of the anastomotic disruption, the extent of intra-abdominal abscess formation, and the patient's overall clinical condition. In many cases, this leads to the need for Hartmann's procedure.[20] Managing postoperative leaks and perforations in the gastrointestinal (GI) tract continues to pose challenges for surgeons. Historically, surgical intervention was the primary treatment for anastomotic leaks following rectal and esophageal surgeries, despite the associated increase in patient mortality and morbidity. Today, the focus has shifted toward minimizing these risks and reducing the surgical burden through minimally invasive alternatives. Initially, alternative treatments such as endoscopic stent placements, clips, and tissue adhesives were developed but showed inconsistent success. More recently, endoluminal vacuum therapy has emerged as an effective method for managing GI leaks.

Weidenhagen first described EVT in the early 2000s. In principle, EVT involves placing a sponge into an intracavitary space and applying negative pressure to facilitate both abscess drainage and granulation tissue formation. This technique reduces bacterial contamination, improves local blood circulation, and accelerates wound healing, ultimately contributing to a shorter hospital stay for the patient.[21] The primary goals of EVT are to enhance tissue reperfusion, promote wound healing, and progressively reduce the size of the cavity, thereby restoring gastrointestinal tract continuity. During treatment, tissue is drawn into the pores of the endosponge, allowing for effective debridement upon sponge removal while simultaneously minimizing contamination. In cases of rectal leaks, gastrointestinal contents can contaminate and block the endosponge, compromising the negative pressure system in the cavity. For this reason, the use of a temporary diverting ostomy is recommended.

In our comprehensive literature review, we found no studies demonstrating a relationship between patient age and EVT outcomes. In our study, given the increased prevalence of comorbidities with advancing age, we compared age with the timing of EVT initiation, the number of EVT sessions, and the duration of EVT treatment. No significant differences were identified. A study published in the World Journal of Surgery in 2020 evaluated the effectiveness of EVT in 41 patients, reporting an average age but not analyzing the relationship between age and EVT outcomes.[22]

Elaine M. Burns et al. conducted a study in the UK and reported that among 58,656 patients who underwent colorectal anastomosis between 2000 and 2008, 7.4% (4,659 patients) required relaparotomy, with an average hospital stay of 27 days.[23] In comparison, the average hospital stay for patients in our study following EVT treatment was 14 days. However, a study by Flarian Kühn in Germany indicated that patients treated with traditional methods (such as percutaneous drainage, relaparotomy with proximal colostomy, or Hartmann's procedure) following anastomotic leakage after neoadjuvant rectal cancer surgery had even shorter hospital stays.[23] Conversely, Mees et al. reported that patients in the EVT group had a shorter hospital stay (37 days) compared to those treated with other treatment modalities.[24]

In our study, early initiation of EVT following anastomotic leakage was significantly correlated with a shorter duration of endosponge therapy. Similarly, P. J. van Koperen et al. demonstrated in 2008 that initiating endosponge therapy within the first six weeks postoperatively was associated with greater treatment success in a cohort of 16 patients treated with EVT.[25] Similarly, Borslap et al. found a higher rate of diverting stoma closure when EVT was initiated within the first 21 days compared to conventional methods (73% vs. 60%).[26] Abdalla et al. reported that initiating EVT within 15 days after anastomotic leakage significantly shortened treatment duration and increased the rate of diverting ileostomy closure (72.4% vs. 27.8%, p=0.003].[27] In our study, we observed successful ileostomy closure in patients who began EVT within 10.23 days after anastomotic leakage.

All 25 patients in our study who underwent EVT had previously received neoadjuvant CRT for rectal cancer. Of these, 14 patients (56%) successfully underwent ileostomy closure. The overall EVT success rate, regardless of ileostomy closure status, was 68%. Meta-analyses report a wide range of ileostomy closure rates, from 31% to 100%, in studies evaluating EVT efficacy.[28] Widenhagen et al. were among the first to investigate EVT efficacy in 2008, reporting an 88% ileostomy closure rate among 29 patients, nine with malignancies who had received neoadjuvant therapy, and 20 with benign disease-related anastomotic leakage treated with EVT retrospectively.[29] Musetto et al. studied 11 patients with rectal cancer-related anastomotic leakage in 2017, with 10 undergoing ileostomy closure; of these, only five had received neoadjuvant therapy.[30] In 2014, Nagell and Holte reported on four patients, one of whom had received neoadjuvant therapy; all four underwent ileostomy closure following endosponge treatment.[31] A more recent analysis, published in April 2022 in the World Journal of Gastroenterology, highlighted that patients who had received neoadjuvant therapy experienced longer treatment durations, required more endoscopic sessions, and underwent more frequent sponge changes.[31,32]

In our study, the average number of endosponge sessions administered after anastomotic leakage was 7.28. In comparison, Rolf Weidenhagen et al. reported an average of 11.4 endosponge sessions per patient in their study of 29 cases treated with EVT for post-resection anastomotic leakage. However, they did not specify whether the 21 patients who underwent initial stoma creation had received neoadjuvant therapy.[29] Bernstorff et al. reported an even higher average of 16 endosponge sessions per patient in their study.[33] The lower average number sessions in our study may be attributed to our treatment protocol, which involved initially changing the sponge every 3-4 days due to the presence of debris in the pouch, as recommended in the literature, and then

extending the interval to up to 7 days once clean granulation tissue began to form.

In our study, complications related to EVT varied, consistent with the literature, which reports rates ranging from 0% to 34.5%. Shalaby et al. reported a complication rate of 11.1% in their study.[34] The most common complication observed in our cohort was pelvic abscess, occurring in one patient. According to Nagell and Holte, the incidence of this complication is approximately 11.5%.[31] We also identified anastomotic strictures in three patients following EVT. All underwent multiple endoscopic bougie dilatations. Successful dilation was achieved in two patients; however, in one patient, despite ileostomy closure, a persistent stricture led to symptoms of ileus, ultimately requiring a Hartmann procedure. In Widenhagen's study, anastomotic strictures occurred in 33% of patients and were managed with balloon dilatation.[29] Similarly, Riss et al., in a study of 15 patients following EVT, reported anastomotic stricture in one patient and recurrent pelvic abscess in five patients.[35] A histopathological study by Alexander Ostapenko in December 2022, conducted on pigs, did not reveal significant inflammatory changes that would implicate EVT in the development of anastomotic strictures.[36] Many published studies have limited follow-up durations, making it difficult to accurately assess the true incidence of anastomotic strictures.[20] However, in our study, the follow-up period was 30.6 months.

In the literature, the success rate of EVT has been reported in heterogeneous studies that include both benign and malignant cases of colorectal surgery. In contrast, our study specifically focuses on patients who underwent neoadjuvant therapy. One of the key strengths of our study is the homogeneity of the target population, focusing exclusively on patients who underwent neoadjuvant therapy followed by low anterior resection. This represents the largest-volume study in the literature on this specific patient population. Additionally, we have demonstrated that the timing of initiating the first EVT treatment following postoperative anastomotic leakage significantly influences the success of the therapy.

In recent years, EVT has emerged as a promising technique for managing anastomotic leaks after rectal surgery. However, there is currently no standardized guideline or consensus. Despite this, contemporary studies indicate that EVT is highly beneficial for treating anastomotic leaks. In 2022, expert panel meetings were convened, focusing on EVT treatments with a follow-up period of at least four years. These discussions addressed fundamental issues stemming from variability in clinical practice.[37] Experts emphasized the need to establish a standardized definition of success for sponge-assisted EVT, including the evaluation of surgical experience, clinical outcomes, and long-term results.

To our knowledge, this is the first study to investigate the application of EVT in patients with anastomotic leakage following low anterior resection and diverting ileostomy surgery after neoadjuvant therapy, using a sample size of this scale. The study identified a significant relationship between the timing of EVT initiation and treatment outcomes, specifically demonstrating that initiating EVT within 10.23 days after anastomotic leakage was associated with successful ileostomy closure. A significant association was also found between the time to first EVT and the duration of EVT treatment. No significant relationships were observed between patients' age and the time to first EVT after anastomotic leakage, the number of endosponge applications, or the duration of endosponge treatment. Additionally, there was no significant correlation between the length of hospital stay and the number of EVT sessions performed. These findings highlight the effectiveness of EVT as a minimally invasive treatment option for managing anastomotic leakage in rectal surgery patients, offering promising outcomes in terms of ileostomy closure and overall success rates.

The main limitations of this study include its retrospective design, which may introduce selection bias and limit the ability to establish causal relationships. Another limitation, common to many recent studies on EVT, is the relatively small sample size. Addressing these limitations in future prospective, multicenter studies with larger cohorts and control groups would provide more robust evidence for the effectiveness of EVT in managing anastomotic leakage.

CONCLUSION

In conclusion, EVT is a valuable tool in the management of anastomotic leaks following colorectal surgery, with the potential to reduce both mortality and morbidity. I Early initiation of EVT enhances its effectiveness. We believe that, when performed by experienced clinicians, EVT can be effectively implemented in the management of anastomotic leaks.

Ethics Committee Approval: This study was approved by the University of Health Sciences Kartal Dr. Lutfi Kirdar City Hospital Ethics Committee (Date: 27.09.2023, Decision No: 2023/514/258/8).

Peer-review: Externally peer-reviewed.

Authorship Contributions: Concept: S.K., M.K.Ç., H.F.K.; Design: S.K., O.A., M.K.Ç.; Supervision: S.K., H.F.K.; Resource: O.A., M.K.Ç., M.E.M.; Materials: S.K., M.E.M., M.K.Ç.; Data collection and/or processing: M.E.M., M.K.Ç.; Analysis and/or interpretation: O.A., M.E.M.; Literature review: S.K., O.A., M.K.Ç.; Writing: O.A., M.E.M.; Critical review: S.K., H.F.K.

Conflict of Interest: None declared.

Financial Disclosure: The author declared that this study has received no financial support.

REFERENCES

1. Sakr A, Emile SH, Abdallah E, Thabet W, Khafagy W. Predictive factors for small intestinal and colonic anastomotic leak: A multivariate analysis. Indian J Surg 2017;79:555–62. [CrossRef]

2. Vallance A, Wexner S, Berho M, Cahill R, Coleman M, Haboubi N, et al. A collaborative review of the current concepts and challenges of anastomotic leaks in colorectal surgery. Colorectal Dis 2017;19:O1–12. [CrossRef]
3. Lindgren R, Hallböök O, Rutegård J, Sjödahl R, Matthiessen P. What is the risk for a permanent stoma after low anterior resection of the rectum for cancer? A six-year follow-up of a multicenter trial. Dis Colon Rectum 2011;54:41–7. [CrossRef]
4. Jannasch O, Klinge T, Otto R, Chiapponi C, Udelnow A, Lippert H, et al. Risk factors, short and long term outcome of anastomotic leaks in rectal cancer. Oncotarget 2015;6:36884–93. [CrossRef]
5. Daams F, Luyer M, Lange JF. Colorectal anastomotic leakage: Aspects of prevention, detection and treatment. World J Gastroenterol 2013;19:2293–7. [CrossRef]
6. Weidenhagen R, Gruetzner KU, Wiecken T, Spelsberg F, Jauch KW. Endoluminal vacuum therapy for the treatment of anastomotic leakage after anterior rectal resection. Rozhl Chir 2008;87:397–402.
7. Braun B. Endo-SPONGE®. Available from: https://www.bbraun.lk/en/products/b0/endo-sponge.html Accessed 20 March 2024.
8. Kuehn F, Janisch F, Schwandner F, Alsfasser G, Schiffmann L, Gock M, et al. Endoscopic vacuum therapy in colorectal surgery. J Gastrointest Surg 2016;20:328–34. [CrossRef]
9. Riss S, Stift A, Kienbacher C, Dauser B, Haunold I, Kriwanek S, et al. Recurrent abscess after primary successful endo-sponge treatment of anastomotic leakage following rectal surgery. World J Gastroenterol 2010;16:4570–4. [CrossRef]
10. Ubels S, Verstegen M, Bouwense S, Klarenbeek B, van Workum F, Rosman C. Commentary: endoscopic vacuum therapy for anastomotic leakage after esophagectomy and total gastrectomy: obstacles to finding true evidence. Dis Esophagus. 2021 May 22;34(5):doab023. [CrossRef]
11. Tavares G, Tustumi F, Tristão LS, Bernardo WM. Endoscopic vacuum therapy for anastomotic leak in esophagectomy and total gastrectomy: a systematic review and meta-analysis. Dis Esophagus. 2021 May 22;34(5):doaa132. doi: 10.1093/dote/doaa132. Erratum in: Dis Esophagus. 2021 May 22;34(5):doab031. [CrossRef]
12. Rottoli M, Di Simone MP, Vallicelli C, Vittori L, Liguori G, Boschi L, et al. Endoluminal vacuum-assisted therapy as treatment for anastomotic leak after ileal pouch-anal anastomosis: A pilot study. Tech Coloproctol 2018;22:223–9. [CrossRef]
13. Srinivasamurthy D, Wood C, Slater R, Garner J. An initial experience using transanal vacuum therapy in pelvic anastomotic leakage. Tech Coloproctol 2013;17:275–81. [CrossRef]
14. Arnold M, Sierra MS, Laversanne M, Soerjomataram I, Jemal A, Bray F. Global patterns and trends in colorectal cancer incidence and mortality. Gut 2017;66:683–91. [CrossRef]
15. Salem ME, Hartley M, Unger K, Marshall JL. Neoadjuvant combined-modality therapy for locally advanced rectal cancer and its future direction. Oncology (Williston Park) 2016;30:546–62.
16. Arezzo A, Migliore M, Chiaro P, Arolfo S, Filippini C, Di Cuonzo D, et al. The REAL (REctal Anastomotic Leak) score for prediction of anastomotic leak after rectal cancer surgery. Tech Coloproctol 2019;23:649–63. [CrossRef]
17. Hyman N, Manchester TL, Osler T, Burns B, Cataldo PA. Anastomotic leaks after intestinal anastomosis: It's later than you think. Ann Surg 2007;245:254–8. [CrossRef]
18. Rahbari NN, Weitz J, Hohenberger W, Heald RJ, Moran B, Ulrich A, et al. Definition and grading of anastomotic leakage following anterior resection of the rectum: A proposal by the International Study Group of Rectal Cancer. Surgery 2010;147:339–51. [CrossRef]
19. Daams F, Wu Z, Lahaye MJ, Jeekel J, Lange JF. Prediction and diagnosis of colorectal anastomotic leakage: A systematic review of literature. World J Gastrointest Surg 2014;6:14–26. [CrossRef]
20. Vignali A, De Nardi P. Endoluminal vacuum-assisted therapy to treat rectal anastomotic leakage: A critical analysis. World J Gastroenterol 2022;28:1394–404. [CrossRef]
21. Strangio G, Zullo A, Ferrara EC, Anderloni A, Carlino A, Jovani M, et al. Endo-sponge therapy for management of anastomotic leakages after colorectal surgery: A case series and review of literature. Dig Liver Dis 2015;47:465–9. [CrossRef]
22. Kühn F, Janisch F, Schwandner F, Gock M, Wedermann N, Witte M, et al. Comparison between endoscopic vacuum therapy and conventional treatment for leakage after rectal resection. World J Surg 2020;44:1277–82. [CrossRef]
23. Kühn F, Wirth U, Zimmermann J, Beger N, Hasenhütl SM, Drefs M, et al. Endoscopic vacuum therapy for in- and outpatient treatment of colorectal defects. Surg Endosc 2021;35:6687–95. [CrossRef]
24. Mees ST, Palmes D, Mennigen R, Senninger N, Haier J, Bruewer M. Endo-vacuum assisted closure treatment for rectal anastomotic insufficiency. Dis Colon Rectum 2008;51:404–10. [CrossRef]
25. Van Koperen PJ, van Berge Henegouwen MI, Rosman C, Bakker CM, Heres P, Slors JF, et al. The Dutch multicenter experience of the endo-sponge treatment for anastomotic leakage after colorectal surgery. Surg Endosc 2009;23:1379–83. [CrossRef]
26. Borstlap WAA, Musters GD, Stassen LPS, van Westreenen HL, Hess D, van Dieren S, et al. Vacuum-assisted early transanal closure of leaking low colorectal anastomoses: The CLEAN study. Surg Endosc 2018;32:315–27. [CrossRef]
27. Abdalla S, Cotte E, Epin A, Karoui M, Lefevre JH, Berger A, et al. Short-term and long-term outcome of endoluminal vacuum therapy for colorectal or coloanal anastomotic leakage: Results of a nationwide multicenter cohort study from the French GRECCAR Group. Dis Colon Rectum 2020;63:371–80. [CrossRef]
28. Dhindsa BS, Naga Y, Saghir SM, Daid SGS, Chandan S, Mashiana H, et al. Endo-sponge in management of anastomotic colorectal leaks: A systematic review and meta-analysis. Endosc Int Open 2021;9:E1342–9. [CrossRef]
29. Weidenhagen R, Gruetzner KU, Wiecken T, Spelsberg F, Jauch KW. Endoscopic vacuum-assisted closure of anastomotic leakage following anterior resection of the rectum: A new method. Surg Endosc 2008;22:1818–25. [CrossRef]
30. Mussetto A, Arena R, Buzzi A, Fuccio L, Dari S, Brancaccio ML, et al. Long-term efficacy of vacuum-assisted therapy (Endo-SPONGE®) in large anastomotic leakages following anterior rectal resection. Ann Gastroenterol 2017;30:649–53. [CrossRef]
31. Nagell CF, Holte K. Treatment of anastomotic leakage after rectal resection with transrectal vacuum-assisted drainage (VAC). A method for rapid control of pelvic sepsis and healing. Int J Colorectal Dis 2006;21:657–60. [CrossRef]
32. Von Bernstorff W, Glitsch A, Schreiber A, Partecke LI, Heidecke CD. ETVARD (endoscopic transanal vacuum-assisted rectal drainage) leads to complete but delayed closure of extraperitoneal rectal anastomotic leakage cavities following neoadjuvant radiochemotherapy. Int J Colorectal Dis 2009;24:819–25. [CrossRef]
33. Verlaan T, Bartels SA, van Berge Henegouwen MI, Tanis PJ, Fockens P, Bemelman WA. Early, minimally invasive closure of anastomotic leaks: A new concept. Colorectal Dis 2011;13:18–22. [CrossRef]
34. Shalaby M, Emile S, Elfeki H, Sakr A, Wexner SD, Sileri P. Systematic review of endoluminal vacuum-assisted therapy as salvage treatment for rectal anastomotic leakage. BJS Open 2018;3:153–60. [CrossRef]
35. Riss S, Stift A, Meier M, Haiden E, Grünberger T, Bergmann M. Endo-sponge assisted treatment of anastomotic leakage following colorectal surgery. Colorectal Dis 2010;12:e104–8. [CrossRef]
36. Ostapenko A, Liechty S, Kleiner D. Endoluminal vacuum therapy for rectal anastomosis is safe and does not increase risk of strictures in a swine model. J Clin Transl Res 2022;8:453–64.
37. Bemelman WA, Arezzo A, Banasiewicz T, Brady R, Espín-Basany E, Faiz O, et al. Use of sponge-assisted endoluminal vacuum therapy for the treatment of colorectal anastomotic leaks: Expert panel consensus. BJS Open 2022;6:zrac123. [CrossRef]

ORİJİNAL ÇALIŞMA - *ÖZ*

Rektal kanser hastalarında neoadjuvan tedavi sonrası anastomoz kaçağının yönetiminde endoluminal vakum terapisinin etkinliği

AMAÇ: Anastomoz kaçağı, kolorektal cerrahi sonrası önemli bir komplikasyon olarak kalmakta olup, artan morbidite ve mortalite ile ilişkilidir. Endoluminal vakum terapisi (EVT), bu tür kaçakların yönetiminde umut verici bir tedavi seçeneği olarak ortaya çıkmıştır, ancak standartlaştırılmış öneriler eksiktir. Bu çalışmanın amacı, kolorektal cerrahi sonrası anastomoz kaçağının yönetiminde EVT'nin etkinliğini değerlendirmek, sonuçlarını ve ilişkili faktörleri incelemektir.

GEREÇ VE YÖNTEM: Kurumumuzda 2018 ile 2022 yılları arasında anastomoz kaçağı nedeniyle EVT uygulanan 25 hastanın retrospektif analizi yapıldı. Toplanan veriler arasında hasta demografileri, cerrahi detaylar, EVT başlama zamanı, EVT seans sayısı, komplikasyonlar ve kaçak kapanması ve sonraki cerrahi müdahaleler gibi sonuçlar yer aldı. Tüm istatistiksel analizler Python paketleri kullanılarak yapıldı.

BULGULAR: Çalışma kohortunun ortalama yaşı 56.84 yıl olup (%68 erkek) tüm hastalar neoadjuvan tedavi sonrası düşük anterior rezeksiyon ve diverting ileostomi ile tedavi edilmiştir, %80'i açık cerrahi geçirmiştir. EVT, postoperatif anastomoz kaçağı olan hastalara uygulanmış olup, ortalama hastanede kalış süresi 14.16 gün ve EVT başlama zamanı cerrahi sonrası ortalama 16.16 gündür. EVT sonrası ileostomi kapanması 14 hastada gerçekleştirilmiştir. EVT başarı oranı %68 olup, ileostomileri kapananlar için ortalama takip süresi 30.7 aydır. Hastaların yaşı ile anastomoz kaçağı sonrası ilk EVT arasındaki süre arasında anlamlı bir ilişki bulunamamıştır (p=0.52). Ancak, ilk EVT'ye kadar geçen süre ile EVT'nin sona erme zamanı arasında anlamlı bir ilişki bulunmuştur (p=0.0003).

SONUÇ: EVT, kolorektal cerrahi sonrası anastomoz kaçağının yönetiminde, yüksek kapanma oranları ve düşük ilişkili morbidite ile uygulanabilir bir seçenek olarak görülmektedir. Tedavi sonuçlarını optimize etmek için EVT'nin erken başlatılması önemli görünmektedir. Bu zorlayıcı klinik senaryoda EVT'nin uzun vadeli faydalarını doğrulamak ve standart protokoller oluşturmak için ileriye dönük çalışmalara ihtiyaç vardır.

Anahtar sözcükler: Anastomoz kaçağı; kolorektal cerrahi; endo-sponge; rektum kanseri.

Ulus Travma Acil Cerrahi Derg 2025;31(5):450-457 DOI: 10.14744/tjtes.2025.27078