ORIGINAL ARTICLE

Transtrochanteric vs. posterolateral approaches in hemiarthroplasty after proximal femoral nail complications: A comparative study

Oğuzhan Gökalp,[1] Bünyamin Arı,[2] Bünyamin Arı[3]

[1]Department of Orthopaedics and Traumatology, Uşak University, Faculty of Medicine, Uşak-*Türkiye*
[2]Department of Orthopaedics and Traumatology, Malatya Turgut Özal University, Faculty of Medicine, Malatya-*Türkiye*
[3]Department of Orthopaedics and Traumatology, Kütahya University of Health Sciences, Faculty of Medicine, Kütahya-*Türkiye*

ABSTRACT

BACKGROUND: Proximal femoral nailing is a widely used technique for treating intertrochanteric femur fractures but may result in complications requiring revision surgery. Hemiarthroplasty is a common solution, with the transtrochanteric and posterolateral approaches being two surgical options. This study aimed to compare these approaches in terms of surgical outcomes and complication rates.

METHODS: A retrospective analysis was conducted on 79 patients who underwent revision hemiarthroplasty for complications related to proximal femoral nailing between 2019 and 2022. Patients were divided into two groups based on the surgical approach: transtrochanteric (Group 1, n=36) and posterolateral (Group 2, n=43). Key variables included surgical time, intraoperative blood loss, transfusion requirements, functional outcomes (Harris Hip Score), and complication rates. Statistical significance was set at $p<0.05$.

RESULTS: Group 1 had a shorter surgical time (49.6±5.69 vs. 64.8±10.29 minutes; $p<0.001$) and lower intraoperative blood loss (395.8±142.89 vs. 474.2±130.94 mL; $p=0.004$) compared to Group 2. Transfusion requirements were also lower in Group 1 (0.4±0.71 vs. 1.2±1.014 units; $p=0.002$). Harris Hip Scores were similar between groups (74.7±7.17 vs. 72.4±7.8; $p=0.276$). Although overall complication rates did not differ significantly ($p=0.744$), dislocations occurred only in Group 2 (6.5%, n=2).

CONCLUSION: The findings suggest that the transtrochanteric approach may offer advantages in surgical efficiency and reduced intraoperative challenges. However, both techniques yielded similar functional outcomes and overall complication rates. Further studies are necessary to validate these findings and assess their applicability in varied clinical contexts.

Keywords: Intertrochanteric fractures; proximal femoral nail complications; hemiarthroplasty; transtrochanteric approach; posterolateral approach.

INTRODUCTION

Femoral intertrochanteric fractures are commonly observed in the elderly population and can lead to significant health complications. With an aging population, the incidence of these fractures is rising, and surgical intervention is typically the preferred method of treatment.[1,2] Proximal femoral nailing (PFN) is widely used in the surgical management of such fractures and has demonstrated favorable outcomes in many patients.[3,4] However, the number of complications is also increasing due to the growing use of PFN. These complications include non-union, delayed union, peri-implant fractures, implant fracture or failure, pull-out of the lag screw from the femoral head or neck, and infection.[5,6]

Cite this article as: Gökalp O, Arı B, Arı B. Transtrochanteric vs. posterolateral approaches in hemiarthroplasty after proximal femoral nail complications: A comparative study. Ulus Travma Acil Cerrahi Derg 2025;31:458-464.

Address for correspondence: Oğuzhan Gökalp
Department of Orthopaedics and Traumatology, Uşak University, Faculty of Medicine, Uşak, Türkiye
E-mail: oguzhangokalp@gmail.com

Ulus Travma Acil Cerrahi Derg 2025;31(5):458-464 DOI: 10.14744/tjtes.2025.36607
Submitted: 11.12.2024 Revised: 29.01.2025 Accepted: 20.02.2025 Published: 05.05.2025
OPEN ACCESS This is an open access article under the CC BY-NC license (http://creativecommons.org/licenses/by-nc/4.0/).

Revision surgery is usually performed using partial arthroplasty to manage complications that arise after PFN. The surgical approach chosen during partial arthroplasty plays a significant role in determining complication rates and functional outcomes. Although the traditional posterolateral approach provides wide exposure during surgery, it may increase the risk of prosthesis dislocation due to the cutting of the posterolateral capsule and external rotators.[2,7]

Recent studies have explored the effectiveness of different surgical approaches in reducing the risk of prosthesis dislocation. Merter et al.[8] reported that the posterolateral approach is associated with a higher risk of prosthesis dislocation and greater intraoperative blood loss. However, this study included only patients who underwent the posterolateral approach and highlighted the importance of considering less invasive techniques.

Bombaci et al.[9] introduced the transtrochanteric approach as a promising alternative that reduces the risk of prosthesis dislocation by preserving the external rotators and the posterolateral capsule through an incision made in the trochanteric region. They also reported that this approach has the potential to significantly lower complication rates, offering hope for improved patient outcomes.

However, the effectiveness of this method has been evaluated in only a limited number of studies, particularly in terms of surgical time, blood loss, transfusion requirements, and functional outcomes compared to the posterolateral approach. Therefore, the role of the transtrochanteric approach in clinical practice requires further comprehensive evaluation.

This study aimed to compare the posterolateral and transtrochanteric surgical approaches with respect to surgical time, blood loss, transfusion requirements, complications, and functional outcomes in patients who underwent revision partial arthroplasty due to mechanical complications following PFN treatment for intertrochanteric fractures.

MATERIALS AND METHODS

This study was conducted in accordance with the ethical principles outlined in the Declaration of Helsinki. Ethical approval was obtained from the Ethics Committee of Uşak University for this non-interventional, retrospective study (Approval Number: 440-440-05, Date: 10.10.2024). Written informed consent was obtained from all patients prior to their inclusion in the study.

Seventy-nine patients who underwent PFN, either by the researchers or at other institutions, for intertrochanteric femur fractures and subsequently underwent hemiarthroplasty by the researchers between 2019 and 2022 due to mechanical complications or non-union were included in the study. Patients who underwent the transtrochanteric approach were classified as Group 1 (n=36), and those who underwent the posterolateral approach were classified as Group 2 (n=43). In Groups 1 and 2, the following patients were excluded: three patients (two from Group 1 and one from Group 2) who declined follow-up or refused to participate in the study; seven patients (three from Group 1 and four from Group 2) with a follow-up period of less than two years; four patients (three from Group 1 and one from Group 2) diagnosed with malignancy; and five patients (two from Group 1 and three from Group 2) who died after the sixth postoperative week due to comorbidities or causes unrelated to surgical complications. However, mortality occurring within the first six weeks or resulting from complications at a later stage was recorded (Fig. 1). The remaining patients were retrospectively evaluated based on demographic characteristics, fracture type, type of complication, surgical duration, blood loss, and transfusion



Figure 1. Flow chart.

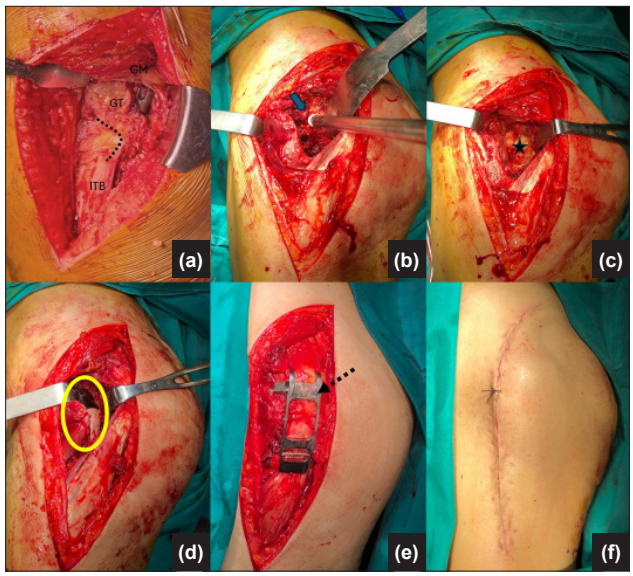

Figure 2. Surgery via the transtrochanteric approach: **(a)** Implant removal. ITB: Iliotibial Band; GM: Gluteus Maximus Muscle; GT: Great Trochanter. Dotted line shows fracture line. **(b)** Removal of the femoral head. Thick arrow indicates a femoral head. **(c)** Exposure for the acetabulum. Star indicates acetabular fossa. **(d)** Placement of hemiarthroplasty implant. Implant indicated by circle. **(e)** Trochanteric fixation. Dotted arrow indicates hook plate. **(f)** Post-closure view.

requirement. Anesthetic risk was assessed using the American Society of Anaesthesiologists (ASA) classification system.

Surgical Techniques

Transtrochanteric Approach: The patient was positioned in the lateral decubitus position, and a vertical incision was made along the fracture line, starting from the trochanteric region. The previously applied PFN components were removed. The external rotators were preserved, and the trochanteric fragment was retracted posterosuperiorly to provide access to the femoral head and neck (Fig. 2).

Posterolateral Approach: The patient was also positioned in the lateral decubitus position, and an incision was made along the fibers of the gluteus maximus. The previously applied PFN components were removed. The external rotators were tagged with marker sutures and then tenotomized. The trochanteric and main fragments were retracted anteriorly to access the femoral head and neck.

In both approaches, a cementless partial hip prosthesis was used. If fixation of the trochanteric fragment was necessary, it was secured with sutures, a plate, or cerclage fixation depending on the fracture type. In patients operated on using the posterolateral approach, the external rotators were reattached. In all cases, a drain was placed at the end of the surgery and left in place for a minimum of 20 hours and a maximum of 24 hours (Fig. 3).

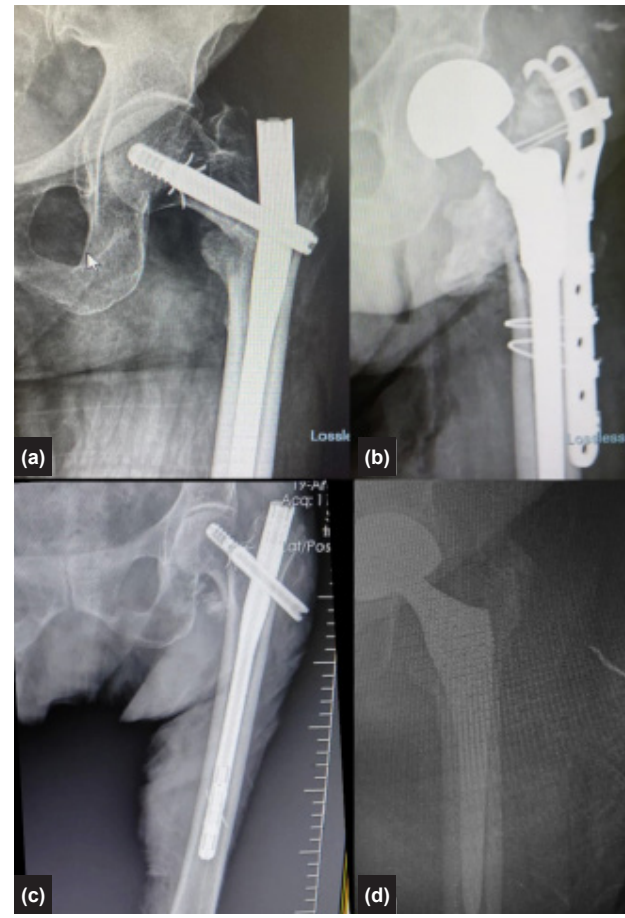

Figure 3. X-ray images showing different implant selections for both groups: a. Left femur intertrochanteric fractures treated with proximal femoral nail (PFN). Implant failure and non-union. b. Transtrochanteric approach + revision stem + trochanteric plate fixation (trochanteric hook plate) and autografting using ground femoral head. c. Implant failure and non-union. d. Posterolateral approach + primary stem + trochanteric suture fixation (polyester polydioxanone sutures).

Perioperative data were obtained from anaesthesia observation forms, while postoperative data were collected from clinical nurse observation forms. Functional assessments were conducted by the researchers using the Harris Hip Score during the patients' final follow-up visits.

Various precautions were taken to minimize potential sources of bias in this study. To prevent selection bias, inclusion and exclusion criteria were clearly defined, and all patients were treated retrospectively by a single surgical team. Preoperative and postoperative data were collected using standardized clinical protocols to minimize data bias. The similarity between the groups was confirmed through statistical analyses. To reduce the risk of bias in subjective assessments such as the Harris Hip Score, all evaluations were performed by the same team using standardized methods.

Table 1. Demographics and surgical characteristics of the study groups

	Transtrochanteric Approach	Posterolateral Approach	
	Min-Max Mean±SD		P-Value
Age	76-89 80.8±3.42	70-92 79±6.37	0.070*
	n (%)		
Sex			
Male	8 (33.3%)	11 (35.5%)	0.868**
Female	16 (66.7%)	20 (64.5%)	
ASA Score			
2	2 (8.3%)	3 (9.7%)	0.898***
3	18 (75%)	24 (77.4%)	
4	4 (16.7%)	4 (12.9%)	
Trochanteric Fixation			
No Fixation/Suture	13 (54.2%)	24 (77.4%)	0.188***
Plate Fixation	4 (16.7%)	3 (9.7%)	
Cerclage Fixation	7 (29.2%)	4 (12.9%)	
Femoral Component			
Primary Stem	17 (70.8%)	22 (71%)	0.991**
Revision Stem	7 (29.2%)	9 (29%)	

*Mann-Whitney U Test; **Chi-Square Test; ***Fisher's Exact Test; p<0.005.

Statistical Analysis

Statistical analyses were conducted to compare demographic, surgical, and clinical variables between the groups. Continuous variables were presented as mean ± standard deviation (Mean ± SD), and comparisons between groups were made using the Mann-Whitney U test. Categorical variables were expressed as percentages (%), and group differences were analyzed using the Chi-square test or Fisher's Exact Test. In all analyses, $p<0.05$ was considered statistically significant. All statistical analyses were performed using the Statistical Package for the Social Sciences (SPSS) version 24 (IBM Corp., Armonk, NY, USA).

RESULTS

The mean age of patients in Group 1 was 80.8±3.42 years (range: 76-89), and in Group 2, it was 79±6.37 years (range: 70-92). The difference in age between the groups was not statistically significant (p=0.070). Gender distribution was also similar; although women were more prevalent in Group 1 (66.7%; n=16), the difference was not statistically significant (p=0.868) (Table 1).

When the groups were examined in terms of trochanteric fixation methods, the proportion of patients who did not receive fixation or underwent suture repair was 54.2% (n=13) in Group 1 and 77.4% (n=24) in Group 2. In Group 1, plate fixation was applied in 16.7% (n=4) of patients, and cerclage fixation in 29.2% (n=7). In Group 2, these rates were 9.7% (n=3) and 12.9% (n=4), respectively. No statistically significant difference was found between the groups regarding fixation methods (p=0.188). Regarding the femoral components used, primary stem use was 70.8% (n=17) in Group 1 and 71% (n=22) in Group 2. Revision stems were used in 29.2% (n=7) of Group 1 and 29% (n=9) of Group 2. No statistically significant difference was observed between the groups in terms of the type of stem used. Both groups also demonstrated a similar distribution of ASA scores (p=0.898), indicating that the patient cohorts were well-matched (Table 1).

There was no statistically significant difference in follow-up duration between the two groups. The mean follow-up period was 30.8±6.25 months (range: 24-46) for Group 1 and 30.9±5.99 months (range: 22-45) for Group 2 (p=0.952). When surgical durations were evaluated, the operative time was 49.6±5.69 minutes (range: 40-65) in Group 1, and 64.8±10.29 minutes (range: 45-85) in Group 2. The surgical duration was significantly shorter in Group 1 (p<0.001). Regarding intraoperative blood loss, Group 1 had an average of 395.8±142.89 mL (range: 300-800), while Group 2 had 474.2±130.94 mL (range: 300-800). Blood loss was significantly higher in Group 2 (p=0.004). The mean transfusion

Table 2. Intergroup comparisons of outcomes

	Transtrochanteric Approach	Posterolateral Approach	
	Min-Max Mean±SD		P Value
Duration of Surgery (min)	40-65 49.6±5.69	45-85 64.8±10.29	<0.001*
Intraoperative Bleeding (mL)	300-800 395.8±142.89	300-800 474.2±130.94	0.004*
Erythrocyte Transfusion (units)	0-2 0.4±0.71	0-3 1.2±1.014	0.002*
Follow-up Time (months)	24-46 30.8±6.25	22-45 30.9±5.99	0.952*
Harris Hip Score	64-88 74.7±7.17	60-88 72.4±7.8	0.276*
	n (%)		
Mortality	2 (7.7%)	3 (8.8%)	0.999**
Complications			
No Complication	21 (87.5%)	24 (77.4%)	0.744**
Fracture	1 (4.2%)	1 (3.2%)	
Dislocation	0 (0%)	2 (6.5%)	
Infection	2 (8.3%)	4 (12.9%)	

*Mann-Whitney U Test; **Fisher's Exact Test; p<0.005.

requirement was 0.4±0.71 units (range: 0-2) in Group 1 and 1.2±1.014 units (range: 0-3) in Group 2, with the difference being statistically significant (p=0.002) (Table 2).

Functional assessments showed no significant difference between the groups in Harris Hip Scores: 74.7±7.17 in Group 1 and 72.4±7.8 in Group 2 (p=0.276). When complication rates were compared, 21 patients (87.5%) in Group 1 and 24 patients (77.4%) in Group 2 experienced no complications. Dislocation occurred only in Group 2 (6.5%; n=2). Infection rates were 8.3% (n=2) in Group 1 and 12.9% (n=4) in Group 2. Fracture non-union was observed in one patient from each group. Overall, there was no statistically significant difference in general complication rates (p=0.744) (Table 2).

DISCUSSION

In recent years, the global increase in the elderly population has led to a rise in age-related health issues, such as osteoporosis. Intertrochanteric femur fractures, one of the most common complications of osteoporosis, are frequently treated with PFN, which has demonstrated favorable outcomes in terms of union rates, shorter operative times, and reduced blood loss compared to alternative fixation methods.[1,5,10] However, PFN is also associated with complications such as implant failure, fracture non-union, infection, and other mechanical issues.[11-13] These complications often necessitate secondary surgeries, with hemiarthroplasty or total arthroplasty being essential treatment options.[7,14]

In our study, we compared two surgical approaches (transtrochanteric and posterolateral) in patients who underwent partial hip arthroplasty following PFN-related complications. Our findings revealed that both approaches produced similar functional outcomes, as measured by the Harris Hip Score. However, the transtrochanteric approach demonstrated certain advantages, including shorter surgical duration and reduced transfusion requirements. Specifically, the mean surgical time in the transtrochanteric group was 49.6±5.69 minutes, compared to 64.8±10.29 minutes in the posterolateral group, a statistically significant difference. Similarly, transfusion needs were significantly lower in patients treated with the transtrochanteric approach. The study by Solarino et al.[12] also reported prolonged surgical time and increased blood loss in arthroplasty procedures performed after PFN. The fact that these parameters were lower in our study supports the effectiveness of the transtrochanteric approach. In a meta-analysis by Filippini et al.,[15] it was emphasized that although the posterolateral approach offers advantages such as shorter operative time and lower intraoperative fracture rates, it carries a higher risk of prosthesis dislocation. Similarly, a meta-analysis by Shuai et al.[16] found that the posterior

approach is associated with a significantly higher risk of dislocation, while also providing a shorter surgical time. In the same study, it was noted that there was no significant difference in blood loss between the posterolateral and anterior approaches. However, the authors mentioned that no studies were available comparing these with lateral approaches.

In our study, the more invasive nature of the posterolateral approach contributed to significant differences in blood loss and complication rates. Notably, patients who underwent this approach required more transfusions, suggesting greater blood loss in the postoperative period.

Although no statistically significant difference was found between the groups in overall complication rates, complications such as infection and periprosthetic fractures were observed in both groups. The literature reports that such complications are frequently observed, particularly in arthroplasty procedures following failed internal fixation.[7,17,18] For example, the study by Morice et al.[18] highlighted high rates of infection and periprosthetic fractures in secondary arthroplasty cases. The complication rates observed in our study were similar to those reported in the literature, emphasizing the importance of managing complications after hemiarthroplasty. This suggests that the complication rates may be independent of the surgical approach used.

A distinguishing feature of the transtrochanteric approach is the preservation of the posterior capsule and external rotators, which may contribute to a reduced risk of dislocation. In the study by Bombaci et al.,[9] it was noted that this approach provides greater stability due to the preservation of these structures. In our study, no dislocations were observed in the transtrochanteric group, while two patients (6.5%) in the posterolateral group experienced dislocations. Although this difference was not statistically significant, it clinically supports the theoretical advantages of the transtrochanteric approach as reported in the literature.

In the study by Merter et al.,[8] the rate of prosthesis dislocation in hemiarthroplasties performed using the posterior approach was reported as 12.5%. The surgical time was noted as 70±15 minutes, and intraoperative blood loss was 500±120 mL. These findings are consistent with our study, which also showed that the posterior approach is associated with longer surgical durations and higher complication rates. In contrast, our results demonstrated that the transtrochanteric approach offers advantages, including a lower risk of prosthesis dislocation and shorter surgical time. These findings align with the study by Gürsoy et al.,[19] who compared the transtrochanteric and posterolateral approaches in the primary treatment of intertrochanteric femur fractures and reported benefits of the transtrochanteric approach, such as reduced dislocation rates and shorter operative times. However, unlike their study, our research focused on a different clinical context—revision surgery following complications from PFN. Revision surgery is inherently more complex than primary procedures, as it involves additional challenges such as implant removal, bone reshaping, and a higher risk of complications. Moreover, our findings regarding nonunion rates are consistent with those reported by Gürsoy et al.[19] In both studies, no statistically significant difference was observed between the transtrochanteric and posterolateral approaches in terms of nonunion rates. This suggests that, despite the complexity of revision cases, the choice of surgical approach may not significantly impact fracture healing outcomes, further highlighting the importance of individualized treatment strategies.

Our study has a retrospective design, a limited number of patients, a short postoperative follow-up period, and compares only two surgical approaches. No other surgical techniques were included. Therefore, our recommendations should be supported by prospective studies with larger patient cohorts and long-term follow-up.

CONCLUSION

This study demonstrates that both the transtrochanteric and posterolateral approaches are viable options for partial hip arthroplasty in the management of mechanical complications following PFN in the treatment of intertrochanteric femur fractures. However, the transtrochanteric approach was found to offer notable advantages, including reduced blood loss and lower transfusion requirements. Our findings show that this method is suitable not only for primary cases but also for more complex procedures such as revision surgery. Additional benefits, such as a lower risk of dislocation and shorter operative time, further emphasize the value of this approach. Building on the reported outcomes of hemiarthroplasty in primary cases, our study demonstrates that the transtrochanteric approach is also a safe and effective option for revision surgery following PFN, thus providing a novel contribution to the literature.

Ethics Committee Approval: This study was approved by the Uşak University Non-Interventional Ethics Committee (Date: 10.10.2024, Decision No: 440-440-059).

Peer-review: Externally peer-reviewed.

Authorship Contributions: Concept: O.G., B.A., B.AR.; Design: O.G., B.A., B.AR.; Supervision: O.G.; Resource: O.G.; Materials: O.G., B.A.; Data collection and/or processing: O.G., B.A., B.AR.; Analysis and/or interpretation: O.G., B.A., B.AR.; Literature review: B.A.; Writing: B.A.; Critical review: O.G., B.AR.

Conflict of Interest: None declared.

Financial Disclosure: The author declared that this study has received no financial support.

REFERENCES

1. Shelton T, Hecht G, Slee C, Wolinsky P. A Comparison of geriatric hip fracture databases. J Am Acad Orthop Surg 2019;27:e135–41. [Cross-

Ref]
2. Roberts KC, Brox WT, Jevsevar DS, Sevarino K. Management of hip fractures in the elderly. J Am Acad Orthop Surg 2015;23:131–7. [CrossRef]
3. Queally JM, Harris E, Handoll HHG, Parker MJ. Intramedullary nails for extracapsular hip fractures in adults. Cochrane Database Syst Rev 2014;9:CD004961. [CrossRef]
4. Saeed OA. Evaluation of the outcome of proximal femoral nail in the treatment of unstable intertrochanteric fracture in adult. AMJ Adv Med J 2024;9:37–45. [CrossRef]
5. Gatz M, Horst K, Hildebrand F. Therapie proximaler Femurfrakturen. [Article in German] Unfallchirurgie 2024;127:335–42. [CrossRef]
6. Siddiqui YS, Khan AQ, Asif N, Khan MJ, Sherwani MKA. Modes of failure of proximal femoral nail (PFN) in unstable trochanteric fractures. MOJ Orthop Rheumatol. 2019;11:7–16. [CrossRef]
7. Assi C, Otayek J, Mansour J, Daher J, Caton J, Samaha C, et al. Outcomes of total hip arthroplasty using dual mobility cups following failed internal fixation of proximal femoral fractures at a mean follow-up of 6 years. SICOT J 2024;10:3. [CrossRef]
8. Merter A, Başarır K, Kocaoğlu H, Karaca MO, Özbek EA, Kalem M. Conversion to hip arthroplasty after cut-out complication of proximal femoral nailing (PFN) in pertrochanteric fractures. J Ankara Univ Fac Med 2021;74:112–7. [CrossRef]
9. Bombaci H. Transtrochanteric approach in intertrochanteric femur fractures. J Trauma 2008;65:1171–3. [CrossRef]
10. Kannus P, Parkkari J, Sievänen H, Heinonen A, Vuori I, Järvinen M. Epidemiology of hip fractures. Bone 1996;18:57S–63S. [CrossRef]
11. Mortazavi SJ, Greenky MR, Bican O, Kane P, Parvizi J, Hozack WJ. Total hip arthroplasty after prior surgical treatment of hip fracture: Is it always challenging? J Arthroplasty 2012;27:31–6. [CrossRef]
12. Solarino G, Bizzoca D, Dramisino P, Vicenti G, Moretti L, Moretti B, et al. Total hip arthroplasty following the failure of intertrochanteric nailing: First implant or salvage surgery? World J Orthop 2023;14:763–70. [CrossRef]
13. Archibeck MJ, Carothers JT, Tripuraneni KR, White RE Jr. Total hip arthroplasty after failed internal fixation of proximal femoral fractures. J Arthroplasty 2013;28:168–71. [CrossRef]
14. Barquet A, Gelink A, Giannoudis PV. Proximal femoral fractures and vascular injuries in adults: Incidence, aetiology and outcomes. Injury 2015;46:2297–313. [CrossRef]
15. Filippini M, Bortoli M, Montanari A, Pace A, Di Prinzio L, Lonardo G, et al. Does surgical approach influence complication rate of hip hemiarthroplasty for femoral neck fractures? A literature review and meta-analysis. Medicina 2023;59:1220. [CrossRef]
16. Shuai L, Huiwen W, Shihao D, Fangyuan W, Juehua J, Jun L, et al. A comparison of different surgical approaches to hemiarthroplasty for the femoral neck fractures: A meta-analysis. Front Surg 2023;9:1049534. [CrossRef]
17. Lee YK, Kim JT, Alkitaini AA, Kim KC, Ha YC, Koo KH. Conversion hip arthroplasty in failed fixation of intertrochanteric fracture: A propensity score matching study. J Arthroplasty 2017;32:1593–8. [CrossRef]
18. Morice A, Ducellier F, Bizot P. Total hip arthroplasty after failed fixation of a proximal femur fracture: Analysis of 59 cases of intra- and extra-capsular fractures. Orthop Traumatol Surg Res 2018;104:681–6. [CrossRef]
19. Gursoy S, Simsek ME, Akkaya M, Dogan M, Bozkurt M. Transtrochanteric approach can provide better postoperative care and lower complication rate in the treatment of hip fractures. Clin Interv Aging 2019;14:137–43. [CrossRef]

ORİJİNAL ÇALIŞMA - *ÖZ*

Proksimal femoral çivi komplikasyonları sonrası hemiartroplastide transtrokanterik ve posterolateral yaklaşımlar: Karşılaştırmalı bir çalışma

AMAÇ: Proksimal femoral çivi (PFN), intertrokanterik femur kırıklarının tedavisinde yaygın olarak kullanılan bir yöntemdir, ancak bazı durumlarda revizyon cerrahisi gerektiren komplikasyonlarla sonuçlanabilir. Bu komplikasyonların tedavisinde hemiartroplasti yaygın bir çözümdür ve cerrahi seçenekler arasında transtrokanterik ve posterolateral yaklaşımlar bulunmaktadır. Bu çalışmanın amacı, bu iki cerrahi yaklaşımı cerrahi sonuçlar ve komplikasyonlar açısından karşılaştırmaktır.

GEREÇ VE YÖNTEM: Bu retrospektif analizde, 2019 ile 2022 yılları arasında proksimal femoral çivi (PFN) komplikasyonları nedeniyle revizyon hemiartroplasti yapılan 79 hasta incelendi. Hastalar, uygulanan cerrahi yaklaşıma göre iki gruba ayrıldı: Transtrokanterik yaklaşım (Grup 1, n=36) ve posterolateral yaklaşım (Grup 2, n=43). Anahtar değişkenler arasında cerrahi süre, intraoperatif kan kaybı, transfüzyon gereksinimi, fonksiyonel sonuçlar (Harris Kalça Skoru) ve komplikasyon oranları yer aldı. İstatistiksel anlamlılık için $p<0.05$ olarak belirlendi.

BULGULAR: Grup 1'de cerrahi süre (49.6±5.69 dakika ve 64.8±10.29 dakika; $p<0.001$) ve intraoperatif kan kaybı (395.8±142.89 ml ve 474.2±130.94 ml; $p=0.004$) Grup 2'ye göre daha düşük bulundu. Benzer şekilde, transfüzyon gereksinimi de Grup 1'de daha düşüktü (0.4±0.71 ünite vs. 1.2±1.014 ünite; $p=0.002$). Harris kalça skoru bakımından gruplar arasında anlamlı bir fark bulunmadı (74.7±7.17 ve 72.4±7.8; $p = 0.276$). Genel komplikasyon oranları arasında anlamlı bir fark görülmemekle birlikte ($p=0.744$), çıkıklar yalnızca Grup 2'de gözlendi (%6.5, n=2).

SONUÇ: Bulgular, transtrokanterik yaklaşımın cerrahi etkinlik ve intraoperatif zorlukların azaltılması açısından avantaj sağlayabileceğini göstermektedir. Bununla birlikte, her iki tekniğin fonksiyonel sonuçlar ve komplikasyon oranları bakımından karşılaştırılabilir olduğu görülmüştür. Bu bulguların farklı klinik senaryolarda doğrulanması için ileri çalışmalara ihtiyaç vardır.

Anahtar sözcükler: İntertrokanterik kırıklar; proksimal femoral çivi komplikasyonları; hemiartroplasti; transtrokanterik yaklaşım; posterolateral yaklaşım.

Ulus Travma Acil Cerrahi Derg 2025;31(5):458-464 DOI: 10.14744/tjtes.2025.36607