CASE SERIES

Management of vertebral artery injuries in civilian cervical gunshot wounds: A case series and literature review

Duygu Dolen,[1] Cafer İkbal Gülsever,[2] Pulat Akın Sabancı[1]

[1]Department of Neurosurgery, Istanbul University, Faculty of Medicine, İstanbul-*Türkiye*
[2]Department of Neurosurgery, Istanbul University, Faculty of Medicine, İstanbul-*Türkiye*

ABSTRACT

Cervical gunshot injuries, although rare, carry a significant risk of vertebral artery injuries (VAIs), which can lead to complex neurological and vascular complications. Effective management requires individualized strategies tailored to the clinical presentation and associated injuries. This study presents three cases of civilian cervical gunshot wounds involving VAIs and reviews the literature to highlight optimal management approaches. Three male patients, aged 24, 41, and 44, presented with cervical gunshot wounds and varying degrees of spinal cord and vertebral artery injuries. Two patients were managed conservatively with close monitoring, broad-spectrum antibiotics, and supportive care due to the absence of progressive neurological deficits or active bleeding. The third patient underwent emergency surgical decompression and vertebral artery clipping to control massive hemorrhage and prevent further neurological deterioration. Where feasible, endovascular treatment was prioritized due to its lower complication rates compared to open surgery. Follow-up revealed diverse outcomes, ranging from paraplegia to quadriparesis, highlighting the variable presentations and long-term consequences associated with these injuries. The third patient developed a delayed arteriovenous fistula (AVF) two years post-injury, which was successfully treated with endovascular embolization. Civilian cervical gunshot injuries involving the vertebral artery require individualized treatment plans. Conservative management may be appropriate for clinically stable cases, while surgical or endovascular interventions are crucial for managing vascular instability or progressive neurological deficits. Long-term follow-up is essential to detect and address delayed complications such as pseudoaneurysms or AVFs. This case series underscores the importance of a multidisciplinary approach, involving neurosurgery, vascular surgery, otolaryngology, and interventional radiology, to optimize outcomes and deliver comprehensive care.

Keywords: Cervical gunshot injuries; civilian trauma; endovascular treatment; multidisciplinary management; vertebral artery injury.

INTRODUCTION

Historically, spinal gunshot injuries have ranked as the third most common cause of spinal trauma, following falls and motor vehicle accidents. Recent statistics indicate a rising incidence of such injuries.[1-3] The thoracic spine is most frequently affected (45-63%), followed by the cervical spine (20-30%) and lumbar spine (10-24%).[2]

The ballistics of military and civilian firearms differ significantly, resulting in distinct biomechanical injury patterns. Civilian low-velocity handguns typically cause less extensive tissue damage and spinal instability compared to high-velocity military weapons.[4,5]

Treatment strategies for gunshot injuries vary considerably between medical centers. Some focus on restoring stability and neurological function, while others prioritize the prevention of complications. Nonetheless, nonoperative management is the prevailing approach for treating civilian gunshot wounds when feasible.[6]

Penetrating cervical injuries, in particular, carry a higher risk of vertebral artery involvement.[7] Although vertebral artery

Cite this article as: Dolen D, Gülsever Cİ, Sabancı PA. Management of vertebral artery injuries in civilian cervical gunshot wounds: A case series and literature review. Ulus Travma Acil Cerrahi Derg 2025;31:480-485.

Address for correspondence: Cafer İkbal Gülsever
Department of Neurosurgery, Istanbul University, Faculty of Medicine, İstanbul-Türkiye
E-mail: cafer.gulsever@gmail.com

Ulus Travma Acil Cerrahi Derg 2025;31(5):480-485 DOI: 10.14744/tjtes.2025.74401
Submitted: 25.10.2024 Revised: 21.01.2025 Accepted: 26.03.2025 Published: 05.05.2025
OPEN ACCESS This is an open access article under the CC BY-NC license (http://creativecommons.org/licenses/by-nc/4.0/).

injuries (VAIs) resulting from cervical gunshot wounds have been previously reported, this study presents distinct management strategies specifically for VAIs caused by civilian cervical gunshot injuries. It emphasizes the importance of multidisciplinary care and long-term follow-up, both of which remain underexplored in the

CASE REPORTS

Case 1: Cervical Gunshot Injury Resulting in Vertebral Artery Injury and Paraplegia

A 24-year-old male was presented to the Emergency Room (ER) 16 hours after sustaining a cervical gunshot wound. He had been transferred from another hospital, where he was diagnosed with multiple cervical fractures and a suspected vertebral artery injury. Upon arrival, the patient was hemodynamically stable. Neurological examination revealed a complete neurological deficit below the level of C5.

Physical examination identified an entry wound on the right side of the neck and an exit wound below the right scapula, with no signs of active bleeding or cerebrospinal fluid (CSF) leakage. An emergent whole-body computed tomography (CT) scan revealed fractures of the right C5, C6, and C7 laminae, as well as the spinous process of the T1 vertebra (Fig. 1). A craniocervical CT-angiogram indicated an injury to the right vertebral artery. Following consultation with neuroradiology, and given the absence of active bleeding, a conservative management approach was adopted. Magnetic resonance imaging (MRI) of the cervicothoracic spine revealed a concussive injury of the medulla extending from C3 to C6, visualized as hyperintense areas on T2-weighted sequences (Fig. 2). These findings supported the decision for conservative treatment in order to minimize the risk of further neurological deterioration.

The patient was admitted to the intensive care unit (ICU) due to his complete neurological deficit and the presence of widely scattered bone fragments within the spinal canal. During his ICU stay, he received broad-spectrum antibiotic therapy, and physical rehabilitation was initiated within the first week. A tracheostomy was also performed during this period.

One month later, following transfer to the general ward, the patient demonstrated 2/5 muscle strength in the upper limbs, although he remained paraplegic. The patient experienced a cardiac arrest due to aspiration, requiring a two-day readmission to the ICU. Follow-up imaging revealed no new pathology.

The patient's family received training in nursing care, and he was transferred to a physical rehabilitation clinic two months after initial admission. At the time of discharge, neurological examination revealed 3/5 diparesis in the upper limbs and 2/5 paraparesis in the lower limbs.

Case 2: Complex Cervical Gunshot Injury with Vertebral Artery Rupture and Neurologic Preservation

A 41-year-old male was admitted to the ER of another hospital following a gunshot injury. The bullet entered through the right cheek, and due to profuse oral bleeding, he was immediately intubated. He was transferred to our trauma center four hours after the initial admission.

Upon arrival, the patient showed signs of severe trauma, including right-sided anisocoria. At the time of initial assessment, the patient exhibited severe hemodynamic instability, which precluded a complete neurological examination. Craniocervical CT and CT angiography revealed multiple fractures of the C1 and C2 vertebrae (Fig. 3). The right distal vertebral artery was not visualized above the C1 level. Emergency cerebral digital subtraction angiography (DSA) confirmed a rupture of the right vertebral artery at the V2 segment (Fig. 4).

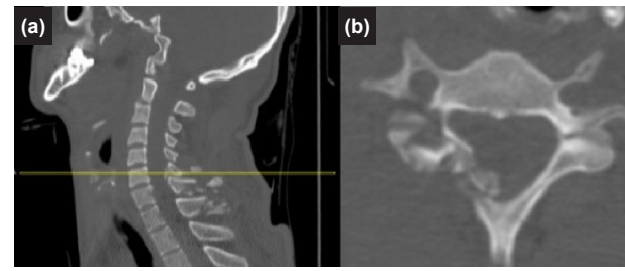

Figure 1. (a, b) Computed tomography (CT) scan of the cervical spine showing a pedicle and lamina fracture of the C6 vertebra, along with multilevel fractures of the spinous processes.

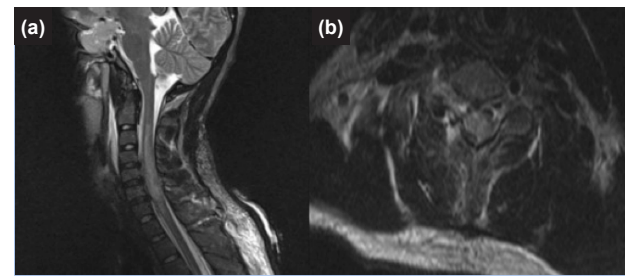

Figure 2. (a, b) Cervicothoracic magnetic resonance imaging (MRI) demonstrating a concussion injury of the medulla extending from C3 to C6, visible as hyperintense areas on T2-weighted sequences. The imaging illustrates the extent of spinal cord damage, which guided the decision for conservative management.

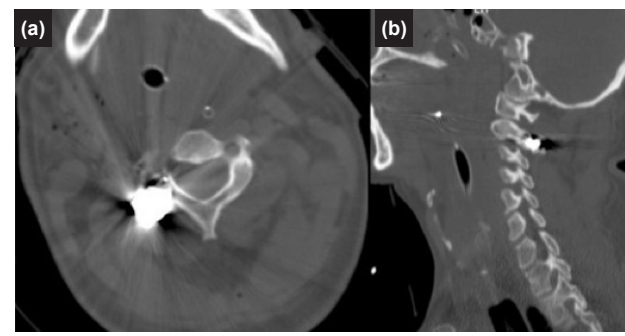

Figure 3. (a, b) Cervical computed tomography (CT) scan showing right facet fractures of the C1 and C2 vertebrae, along with visible metallic artifacts.

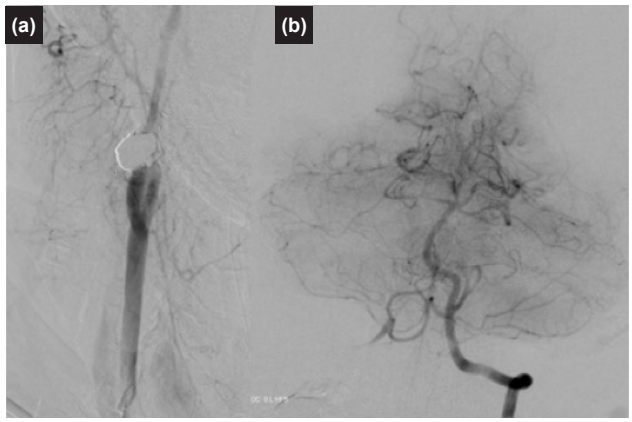

Figure 4. (a, b) Cerebral digital subtraction angiography (DSA) demonstrating a rupture of the right vertebral artery, with no blood flow visualized above the C1 vertebra. These findings supported the surgical decision to apply proximal and distal vascular clips.

Endovascular embolization of the right vertebral artery was initially planned; however, conservative management was pursued due to technical issues in the catheterization laboratory. Despite these limitations, the otolaryngology team sutured both the internal and external entry points of the bullet tract. The patient required massive transfusions of blood and colloids, which ultimately necessitated surgical intervention. The neurosurgical team performed a partial laminectomy and facetectomy at C1 and C2 to retrieve the bullet. During the procedure, the patient experienced massive hemorrhage, prompting proximal and distal clipping of the right vertebral artery. Postoperatively, he was monitored in the ICU.

Following ICU care, the patient required an additional procedure by the Plastic and Reconstructive Surgery team due to wound necrosis. He was discharged home one month after admission, with a tracheostomy in place but no additional neurological deficits.

Table 1. Summary of vertebral artery injury (VAI) case series in the literature (chronological order)

Study	Year	Number of Cases	Mechanism of Injury	Management Strategies	Complications Reported	Key Outcomes
Syre et al.[24]	2013	10	Civilian gunshot wounds	Multidisciplinary approach	Spinal cord injury, pseudoaneurysms	Favorable outcomes with tailored treatment
Zhao et al.[25]	2016	6	Bilateral vertebral artery injury	Endovascular treatment	Subarachnoid hemorrhage	Effective single-stage embolization
Akinduro et al.[26]	2016	8	Iatrogenic vertebral artery injury	Conservative, endovascular	None significant	Improved neurological outcomes
Balasundaram et al.[27]	2019	12 (pediatric cases)	Pseudoaneurysms from trauma	Endovascular embolization	None significant	High success rate in pediatric patients
Piper et al.[28]	2021	14	Penetrating trauma	Surgical, endovascular	Stroke, pseudoaneurysms	Proposed a comprehensive treatment algorithm
Mugge et al.[29]	2024	9	Cervical spine surgery-related	Stereotactic arteriography	None significant	Improved intraoperative precision
Morsi et al.[30]	2024	7	Traumatic vessel injury	Endovascular embolization (N-butyl cyanoacrylate)	None significant reported	Safe and effective for vascular control
Present Study	2024	3	Civilian gunshot wounds	Conservative (2 cases), surgical clipping (1 case)	Arteriovenous fistula (AVF) in 1 case, resolved with embolization	Highlights importance of case-specific, tailored care

This table highlights the number of cases, mechanisms of injury, management strategies, reported complications, and key outcomes. Over time, there has been a clear shift from surgical approaches to endovascular techniques and conservative management in stable cases, reflecting a growing preference for safer, less invasive methods. This progression underscores the importance of individualized treatment strategies, as exemplified in the present study.
ASIA: American Spinal Injury Association; AVF: Arteriovenous fistula; CSF: Cerebrospinal fluid; CT: Computed tomography; DSA: Digital subtraction angiography; ER: Emergency room; GCS: Glasgow Coma Scale; ICU: Intensive care unit; MRI: Magnetic resonance imaging; PICA: Posterior inferior cerebellar artery; SLICS: Subaxial Injury Classification and Severity Scale; TLICS: Thoracolumbar Injury Classification and Severity Scale; VAI: Vertebral artery injury.

Case 3: Cervical Gunshot Injury with Delayed Arteriovenous Fistula and Quadriparesis

A 44-year-old male presented to the ER after sustaining a cervical gunshot injury. On examination, he demonstrated 2/5 strength in the lower limbs, anesthesia below the L3 level, and absent reflexes. Initial CT imaging revealed a fracture of the anterior arch and left lateral mass of the C1 vertebra, along with a retained bullet in the cervical spine. Based on these findings, the patient underwent emergency C1-C2 decompression and fusion to stabilize the spine and prevent further neurological deterioration.

The patient was discharged home with a comprehensive physical therapy plan. However, two years later, during a physical therapy session, he experienced a sudden, severe headache followed by progressive quadriparesis (1/5 strength in all limbs). Physical examination revealed absent bilateral plantar reflexes and urinary incontinence, indicating worsening neurological function.

Spinal angiography was performed and revealed a delayed arteriovenous fistula (AVF) draining from the suboccipital plexus to the inferior petrosal sinus and internal jugular vein. The neurointerventional team successfully performed embolization of the AVF, restoring vascular integrity and preventing further complications. Following the procedure, the patient was discharged home with persistent but improved quadriparesis (2/5 strength in all limbs) and continued physical therapy as part of ongoing rehabilitation. This case highlights the importance of regular imaging follow-up and the role of a multidisciplinary team in effectively managing delayed vascular complications.

DISCUSSION

Spinal gunshot wounds resulting in spinal cord injury most commonly occur in the third decade of life,[2] with a clear male predominance and a male-to-female ratio of 4:1.[8,9] Vertebral artery injuries occur in about 3.1% of civilian cases, with gunshot wounds being the leading mechanism.[10]

Management strategies for VAIs have evolved significantly over the past few decades. While surgical exploration was routinely recommended prior to the 1990s, accumulating evidence now supports conservative management in up to 80% of stable cases.[5,11-13] The vertebral arteries are particularly vulnerable to trauma as they course through the transverse foramina from C6 to C1.[14] These injuries are often penetrating, as observed in our cases, and are associated with spinal cord injury in 50-59% of patients.[9,15] In our series, two patients were managed conservatively. These cases underscore the value of a non-invasive approach when vascular integrity is preserved, as evidenced by the absence of active bleeding and stable imaging findings at the time of presentation.

Imaging plays a pivotal role in the management of spinal gunshot injuries. CT is the first-line modality for evaluating stability and multisystem injuries; however, retained bullet fragments may reduce image quality.[16,17] MRI is valuable for assessing medullary concussion injuries and soft tissue damage, but it must be performed with caution due to the potential risk of bullet fragment migration.[17-19] DSA remains the gold standard for both diagnosing and treating vascular injuries.[20] In our first case, CT and MRI confirmed a medullary concussion injury without evidence of active vascular bleeding, supporting the decision for conservative treatment. In contrast, the third case highlighted the importance of long-term follow-up, as delayed DSA imaging revealed an arteriovenous fistula.

Vertebral artery injuries are often classified according to neck zones. Zone 2, which includes the vertebral artery at its most vulnerable segment (C6 to C2), is the most frequently injured area.[21,22] Surgical and endovascular approaches for VAIs have evolved significantly, with endovascular techniques gaining preference due to their lower complication rates and technical feasibility.[23] In our third case, endovascular embolization was successfully performed to treat a delayed AVF, underscoring the value of minimally invasive techniques in managing complex vascular injuries.

Our findings align with broader trends in the literature, as summarized in Table 1. This table illustrates the shift from predominantly surgical management to a greater reliance on endovascular and conservative strategies in stable cases. While earlier studies emphasized surgical ligation, more recent research highlights the safety and efficacy of endovascular embolization and individualized conservative care.(Table 1)[24-30] This shift reflects an increasing emphasis on tailoring treatment to the severity and characteristics of each injury, a principle applied across all three cases presented in this study.

Complications, including pseudoaneurysms and arteriovenous fistulas, occur in 21-28% of VAI cases.[10] Our third case reinforces the importance of vigilant long-term follow-up, as the AVF was detected years after the initial trauma and required prompt intervention using endovascular methods.

Surgical treatment remains indicated in cases of progressive neurological deficits, instability, or persistent CSF leaks. However, it is associated with a higher complication rate compared to conservative management and should be reserved for well-defined indications.[31] In our second case, surgical decompression and vertebral artery clipping were critical to controlling massive hemorrhage caused by bullet mobilization. This case underscores the life-saving role of surgical intervention in emergent, high-risk scenarios.

The case reports presented here highlight the clinical variability of VAIs resulting from civilian cervical gunshot wounds. Each case demonstrated distinct clinical presentations, management strategies, and outcomes, reinforcing the importance of individualized care. Providing optimal treatment requires a multidisciplinary approach, involving neurosurgeons, vascular surgeons, interventional radiologists, and rehabilita-

tion teams working in collaboration. The inclusion of insights from the literature (Table 1) further underscores the necessity of multidisciplinary collaboration, particularly as management strategies continue to evolve toward less invasive and highly specialized approaches. This collaborative model enables individualized treatment planning, reduces the risk of complications, and offers the best possible chance for recovery, as demonstrated in our case series.

CONCLUSION

Civilian cervical gunshot injuries involving vertebral artery damage require tailored, multidisciplinary approaches to achieve optimal outcomes. While conservative management is appropriate for clinically stable patients, surgical or endovascular interventions remain essential for cases involving instability or progressive neurological deficits. These cases underscore the importance of vigilant long-term follow-up to detect and manage delayed complications, such as AVFs. This study highlights the real-world application of collaborative care in the management of complex spinal and vascular trauma.

Acknowledgment: The authors would like to thank the medical and surgical teams for their invaluable contributions to the care of these patients.

Peer-review: Externally peer-reviewed.

Authorship Contributions: Concept: D.D., C.İ.G., P.A.S.; Design: D.D., C.İ.G., P.A.S.; Supervision: P.A.S.; Resource: D.D., C.İ.G., P.A.S.; Materials: D.D., C.İ.G., P.A.S.; Data collection and/or processing: D.D., C.İ.G., P.A.S.; Analysis and/or interpretation: D.D., C.İ.G., P.A.S.; Literature review: D.D., C.İ.G., P.A.S.; Writing: D.D., C.İ.G., P.A.S.; Critical review: D.D., C.İ.G., P.A.S.

Conflict of Interest: None declared.

Financial Disclosure: The author declared that this study has received no financial support.

REFERENCES

1. Beaty N, Slavin J, Diaz C, Zeleznick K, Ibrahimi D, Sansur CA. Cervical spine injury from gunshot wounds. J Neurosurg Spine 2014;21:442–9. [CrossRef]
2. Jakoi A, Iorio J, Howell R, Zampini JM. Gunshot injuries of the spine. Spine J 2015;15:2077–85. [CrossRef]
3. DeVivo MJ, Go BK, Jackson AB. Overview of the national spinal cord injury statistical center database. J Spinal Cord Med 2002;25:335–8. [CrossRef]
4. Bono CM, Heary RF. Gunshot wounds to the spine. Spine J 2004;4:230–40. [CrossRef]
5. Heiden JS, Weiss MH, Rosenberg AW, Kurze T, Apuzzo ML. Penetrating gunshot wounds of the cervical spine in civilians. Review of 38 cases. J Neurosurg 1975;42:575–9. [CrossRef]
6. Klimo P Jr, Ragel BT, Rosner M, Gluf W, McCafferty R. Can surgery improve neurological function in penetrating spinal injury? A review of the military and civilian literature and treatment recommendations for military neurosurgeons. Neurosurg Focus 2010;28:E4. [CrossRef]
7. Meier DE, Brink BE, Fry WJ. Vertebral artery trauma: Acute recognition and treatment. Arch Surg 1981;116:236–9. [CrossRef]
8. Patil R, Jaiswal G, Gupta TK. Gunshot wound causing complete spinal cord injury without mechanical violation of spinal axis: Case report with review of literature. J Craniovertebr Junction Spine 2015;6:149–57. [CrossRef]
9. Willis BK, Greiner F, Orrison WW, Benzel EC. The incidence of vertebral artery injury after midcervical spine fracture or subluxation. Neurosurgery 1994;34:435–41. [CrossRef]
10. Asensio JA, Dabestani PJ, Wenzl FA, Miljkovic SS, Kessler JJ 2nd, Fernandez CA, et al. A systematic review of penetrating extracranial vertebral artery injuries. J Vasc Surg 2020;71:2161–9. [CrossRef]
11. Bumpass DB, Buchowski JM, Park A, Gray BL, Agarwal R, Baty J, et al. An update on civilian spinal gunshot wounds: Treatment, neurological recovery, and complications. Spine (Phila Pa 1976) 2015;40:450–61. [CrossRef]
12. Van Deurzen DF, Van As AB, Verleisdonk EJ. Is routine angiography necessary in patients with a gunshot wound to the neck? A retrospective analysis. Eur J Trauma 2002;28:90–4. [CrossRef]
13. Golueke P, Sclafani S, Phillips T, Goldstein A, Scalea T, Duncan A. Vertebral artery injury--Diagnosis and management. J Trauma 1987;27:856–65. [CrossRef]
14. Parent AD, Harkey HL, Touchstone DA, Smith EE, Smith RR. Lateral cervical spine dislocation and vertebral artery injury. Neurosurgery 1992;31:501–9. [CrossRef]
15. Jean WC, Barrett MD, Rockswold G, Bergman TA. Gunshot wound to the head resulting in a vertebral artery pseudoaneurysm at the base of the skull. J Trauma 2001;50:126–8. [CrossRef]
16. Slavin J, Beaty N, Raghavan P, Sansur C, Aarabi B. Magnetic resonance imaging to evaluate cervical spinal cord injury from gunshot wounds from handguns. World Neurosurg 2015;84:1916–22. [CrossRef]
17. Bashir EF, Cybulski GR, Chaudhri K, Choudhury AR. Magnetic resonance imaging and computed tomography in the evaluation of penetrating gunshot injury of the spine. Case report. Spine (Phila Pa 1976) 1993;18:772–3. [CrossRef]
18. Teitelbaum GP, Yee CA, Van Horn DD, Kim HS, Colletti PM. Metallic ballistic fragments: MR imaging safety and artifacts. Radiology 1990;175:855–9. [CrossRef]
19. Ditkofsky N, Colak E, Kirpalani A, Mathur S, Deva D, Pearce D, et al. MR imaging in the presence of ballistic debris of unknown composition: A review of the literature and practical approach. Emerg Radiol 2020;27:527–32. [CrossRef]
20. Finitsis SN, Falcone S, Green BA. MR of the spine in the presence of metallic bullet fragments: Is the benefit worth the risk? AJNR Am J Neuroradiol 1999;20:354–6.
21. Bear HM, Zoarski GH, Rothman MI. Evaluation of vertebral artery injury from ballistic trauma to the neck. Emerg Radiol 1997;4:346–8. [CrossRef]
22. Dalgic A, Okay O, Nacar O, Daglioglu E, Pasaoglu L, Belen D. Vertebral artery insult at the transverse foramina by gun shot wounds: Report of two cases. Turk Neurosurg 2009;19:413–6.
23. Monson DO, Saletta JD, Freeark RJ. Carotid vertebral trauma. J Trauma 1969;9:987–99. [CrossRef]
24. Syre P 3rd, Rodriguez-Cruz L, Desai R, Greene KA, Hurst R, Schuster J, et al. Civilian gunshot wounds to the atlantoaxial spine: A report of 10 cases treated using a multidisciplinary approach. J Neurosurg Spine 2013;19:759–66. [CrossRef]
25. Zhao WY, Zhao KJ, Huang QH, Xu Y, Hong B, Liu JM. Single-stage endovascular treatment of subarachnoid hemorrhage related to bilateral vertebral artery dissecting aneurysms. Interv Neuroradiol 2016;22:138–42. [CrossRef]
26. Akinduro OO, Baum GR, Howard BM, Pradilla G, Grossberg JA, Rodts GE Jr, et al. Neurological outcomes following iatrogenic vascular injury during posterior atlanto-axial instrumentation. Clin Neurol Neurosurg 2016;150:110–6. [CrossRef]
27. Balasundaram P, Sebastian LJD, Jain N, Prabhakar A, Garg A, Gaikwad

S. Management of arterial pseudoaneurysms of the neck in a pediatric population: An endovascular case series and review of literature. World Neurosurg 2019;125:e273–81. [CrossRef]
28. Piper K, Rabil M, Ciesla D, Agazzi S, Ren Z, Mokin M, et al. Penetrating vertebral artery injuries: A literature review and proposed treatment algorithm. World Neurosurg 2021;148:e518–26. [CrossRef]
29. Mugge L, Dang DD, Ziu M, Fanous A. Intraoperative stereotactic arteriography in complex cervical spine surgery. Cureus 2024;16:e56783. [CrossRef]
30. Morsi RZ, Baskaran A, Thind S, Carrión-Penagos J, Desai H, Kothari SA, et al. Endovascular embolization of traumatic vessel injury using n-butyl cyanoacrylate: A case series. Indian J Otolaryngol Head Neck Surg 2024;76:1554–62. [CrossRef]
31. Venger BH, Simpson RK, Narayan RK. Neurosurgical intervention in penetrating spinal trauma with associated visceral injury. J Neurosurg 1989;70:514–8. [CrossRef]

OLGU SERİSİ - *ÖZ*

Sivil servikal ateşli silah yaralanmalarında vertebral arter yaralanmalarının yönetimi: Bir olgu serisi ve literatür incelemesi

Servikal ateşli silah yaralanmaları nadir görülmekle birlikte, vertebral arter yaralanmaları (VAY) açısından yüksek risk taşır ve karmaşık nörolojik ve vasküler komplikasyonlara yol açabilir. Bu yaralanmalar, klinik tabloya ve eşlik eden hasarlara bağlı olarak bireyselleştirilmiş tedavi stratejileri gerektirir. Bu çalışmada, sivil servikal ateşli silah yaralanmalarına bağlı üç vertebral arter yaralanması olgusu sunulmuş ve optimal yönetim yaklaşımlarını vurgulamak amacıyla literatür gözden geçirilmiştir. Yaşları 24, 41 ve 44 olan üç erkek hasta, değişen derecelerde omurilik ve vertebral arter yaralanmaları ile servikal ateşli silah yaralanması nedeniyle başvurmuştur. İki hasta, ilerleyici nörolojik defisit veya aktif kanama olmaması nedeniyle yakın takip, geniş spektrumlu antibiyotikler ve destekleyici bakım ile konservatif olarak yönetilmiştir. Üçüncü hasta, ciddi kanamayı kontrol altına almak ve daha fazla nörolojik bozulmayı önlemek için acil cerrahi dekompresyon ve vertebral arter klipleme gerektirmiştir. Endovasküler tedavi, açık cerrahiye kıyasla daha düşük komplikasyon oranları nedeniyle tercih edilmiştir. Takip sürecinde sonuçlar paraplejiden kuadripareziye kadar değişiklik göstermiştir ve bu durum, bu yaralanmaların değişken seyrini ve uzun dönem sonuçlarını vurgulamaktadır. Üçüncü hastada, yaralanmadan iki yıl sonra gelişen bir arteriyovenöz fistül (AVF) endovasküler embolizasyon ile başarıyla tedavi edilmiştir. Sivil servikal ateşli silah yaralanmalarına bağlı vertebral arter hasarları, bireyselleştirilmiş tedavi planları gerektirir. Stabil vakalarda konservatif yönetim uygunken, vasküler instabilite veya ilerleyici nörolojik defisitlerin tedavisi için cerrahi veya endovasküler müdahaleler gereklidir. Gecikmiş komplikasyonları, özellikle psödoanevrizma veya AVF gibi sorunları tespit etmek ve yönetmek için uzun süreli takip kritik öneme sahiptir. Bu olgu serisi, nöroşirürji, damar cerrahisi, kulak burun boğaz ve girişimsel radyolojiyi içeren multidisipliner bir yaklaşımın önemini vurgulamaktadır

Anahtar sözcükler: Servikal ateşli silah yaralanmaları; sivil travma; endovasküler tedavi; multidisipliner yönetim; vertebral arter yaralanması.

Ulus Travma Acil Cerrahi Derg 2025;31(5):480-485 DOI: 10.14744/tjtes.2025.74401