CASE REPORT

A superficial temporal artery pseudoaneurysm following dog bites in a 4-year-old child: The first case reported in the literature

Emrah Işıktekin

Department of Plastic, Reconstructive and Aesthetic Surgery, Balıkesir University Faculty of Medicine, Balıkesir-*Türkiye*

ABSTRACT

Pseudoaneurysms of the extracranial arterial system are rare, largely due to the small size and thin walls of superficial vessels. This report presents a case of a pseudoaneurysm of the superficial temporal artery (STA) following dog bites in a 4-year-old child, an injury sustained three months prior. The lesion was initially misdiagnosed as an abscess, possibly involving an occult foreign body, and was unsuccessfully drained in the Emergency Department (ED). Physical examination revealed a palpable mass measuring 21 × 18 × 12 mm in the left frontotemporal region above the eyebrow. There were no signs of local inflammation or fluctuation. The child's facial expressions and eyebrow movements were normal, and laboratory tests were within normal limits. Doppler ultrasound demonstrated a partially thrombosed pseudoaneurysm with a well-defined swirl pattern, known as the "yin and yang" sign. The patient was admitted for surgery, and the frontal branch of the superficial temporal artery was dissected to the neck of the pseudoaneurysm after debridement and removal of blood clots. A pseudoaneurysm measuring approximately 1 cm in diameter was observed on the deep side of the lesion, extending up to the eyebrow. The affected artery was ligated using a segmental running locking suture and then excised. Postoperatively, the patient was transferred to the clinic in stable condition without complications. Pathological analysis revealed that the tumor wall consisted of a mixed thrombus with signs of organization. The patient experienced no complications during follow-up. It is of utmost importance to obtain a comprehensive clinical history, conduct a meticulous physical examination, and perform detailed imaging studies, including ultrasound, to avoid overlooking critical pathologies in emergency situations. Such measures are essential for early detection and management of underlying medical conditions, thereby preventing further complications and improving the overall prognosis.

Keywords: Dog bite trauma; pseudoaneurysm; superficial temporal artery.

INTRODUCTION

Pseudoaneurysms of the superficial temporal artery (STA) are uncommon. This rarity is attributable to the small size and narrow diameter of superficial vessels, which are characteristically thin and more prone to complete transection than partial laceration when subjected to sharp trauma.[1] Pseudoaneurysms can result from a variety of underlying causes. In this case report, we describe an unusual presentation following trauma caused by a dog bite. To the best of our knowledge, this is the first reported case in the literature with such an etiology. This report aims to highlight the importance of prompt diagnosis and discuss the available management options for pseudoaneurysm of the STA.

CASE REPORT

This report presents a case of an STA pseudoaneurysm in a 4-year-old child, developing three months after sustaining dog bite injuries. The lesion was misdiagnosed in the emergency department (ED) as a possible abscess, potentially containing an occult foreign body, and an attempt was made to drain it in

Cite this article as: Işıktekin E. A superficial temporal artery pseudoaneurysm following dog bites in a 4-year-old child: The first case reported in the literature. Ulus Travma Acil Cerrahi Derg 2025;31:486-489.

Address for correspondence: Emrah Işıktekin

Department of Plastic, Reconstructive and Aesthetic Surgery, Balıkesir University Faculty of Medicine, Balıkesir, Türkiye

E-mail: md.emrahisiktekin@gmail.com

Ulus Travma Acil Cerrahi Derg 2025;31(5):486-489 DOI: 10.14744/tjtes.2025.94797

Submitted: 25.10.2024 Revised: 20.02.2025 Accepted: 20.02.2025 Published: 05.05.2025

OPEN ACCESS This is an open access article under the CC BY-NC license (http://creativecommons.org/licenses/by-nc/4.0/).

the ED. The attending physician incised the lesion; however, no purulent discharge or foreign body was found, only blood clots and active bleeding were observed. After irrigation and wound cleaning, the incision was closed, a bandage was applied, and the patient was referred to the department of plastic, reconstructive, and aesthetic surgery. On physical examination, a palpable mass measuring 21×18×12 mm was noted in the left frontotemporal region above the eyebrow (Fig. 1). There were no signs of local inflammation or fluctuation. Facial expressions and eyebrow movements were normal. Laboratory tests results were within normal limits. Doppler ultrasound revealed a partially thrombosed pseudoaneurysm with a well-defined swirl pattern (Fig. 2). In many cases, including this one, colour Doppler imaging reveals a well-defined swirl pattern, clinically referred to as the "yin and yang sign."[2] The patient was admitted for surgery, and the frontal branch of the STA was dissected to the neck of the pseudoaneurysm following debridement and removal of blood clots. A pseudoaneurysm approximately 1 cm in diameter was identified on the deep side of the lesion, extending toward the eyebrow. The affected artery was ligated using a segmental running locking suture and excised (Fig. 3). Postoperatively, the patient was transferred to the clinic in stable condition without complications. Pathological analysis revealed that the tumor wall consisted of a mixed thrombus with signs of organization. The patient remained complication-free during follow-up. To the best of our knowledge, this is the first reported case of an STA pseudoaneurysm developing some time after a dog bite, highlighting the importance of thorough initial evaluation and accurate diagnosis in patients presenting with an unexpected mass following dog bite trauma. The patient's parents provided written informed consent for the report of his case details and imaging studies.

DISCUSSION

The most common complication of dog bites is infection. Frequently observed infectious complications include abscesses, osteomyelitis, tetanus, and sepsis.[3] An abscess is defined as a localized collection of purulent material, typically surrounded by inflammation and granulation tissue in response to infection. Although contrast-enhanced computed tomography (CT) is the primary and standard imaging modality for evaluating head and neck infections, most uncomplicated abscesses can be accurately diagnosed through a thorough clinical examination. Key clinical signs include erythema, induration, tenderness to palpation, and fluctuance. These abscesses are typically managed effectively with incision and drainage.[4] In the differential diagnosis of suspected abscesses, it is essential to consider and evaluate conditions such as periorbital cellulitis, retained foreign bodies, osteomyelitis, methicillin-resistant Staphylococcus aureus (MRSA) infection, and infected dog bite wounds using CT imaging.[5] As demonstrated in this case, pseudoaneurysms must also be included in the differential diagnosis of abscesses.



Figure 1. Preoperative photograph of the patient.

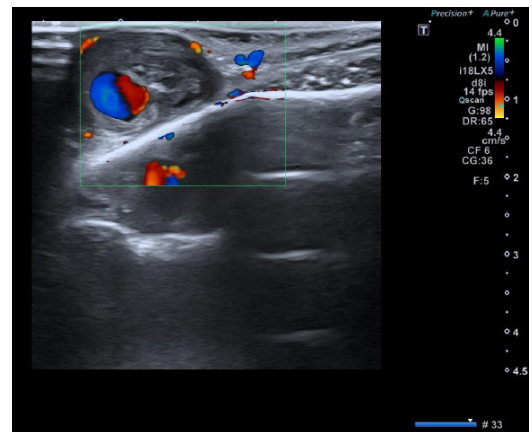

Figure 2. Preoperative Doppler ultrasound image.



Figure 3. Intraoperative photograph of the superficial temporal artery (STA) pseudoaneurysm.

Although pseudoaneurysms of the head and neck are rare, they are often associated with a history of trauma that may suggest vascular injury. In cases of blunt or penetrating trauma, a hematoma may form due to damage to the arterial wall, while sustained turbulent blood flow between the damaged vessel and the hematoma usually results in the formation of a pseudoaneurysm.[6] Pseudoaneurysms resulting from animal bites are uncommon in the literature. Reported animals responsible for such injuries include dogs, cats, snakes, and squirrels.[7] Most pseudoaneurysms following animal bites have been reported in the radial or ulnar arteries. This report, however, presents the first known case of a superficial temporal artery pseudoaneurysm as a complication of a dog bite. Pediatric STA pseudoaneurysms are rare and infrequently described in the literature.[8] This rarity may be attributed to the smaller arterial diameter in pediatric patients compared to adults, making these vessels more susceptible to rupture rather than transection during trauma. Dog bite injuries not only cause lacerations to the skin but can also result in serious damage to soft tissue and vasculature.[9] When evaluating a patient with a dog bite, the assessment should include the possibility of occult arterial injuries, such as transection or pseudoaneurysm, which may present in a delayed fashion and lead to significant morbidity or even mortality.[10] Debridement and primary repair are commonly used in the management of dog bites after wound cleaning. Antibiotic therapy and rabies vaccination can be added to the treatment if necessary.

A pseudoaneurysm may present either acutely or in a delayed manner. According to the literature, the interval between an animal bite and the diagnosis of a pseudoaneurysm can range from a few hours to three weeks. However, in our case, the pseudoaneurysm was first identified three months after the dog bite.[7] Although physical examination, including auscultation, plays a significant role in the diagnosis of pseudoaneurysms, ultrasonography remains the most effective imaging modality for assessing these pseudoaneurysms. It is non-invasive, does not involve radiation, and does not require the patient to remain completely still, making it particularly valuable for detecting pseudoaneurysms in children.[11,12] Color Doppler ultrasonography can also aid in diagnosis by identifying the neck of the pseudoaneurysm and tracing the feeding artery.[13] In our case, blood flow within the lesion appeared red and blue, illustrating the classic "yin and yang sign" due to turbulent internal flow. In addition to being an accessible and cost-effective diagnostic method for trauma-induced pseudoaneurysms of the STA, ultrasound can also be used intraoperatively to trace the course of the artery.

The risk of rupture and spontaneous expansion make the treatment of an aneurysm mandatory.[14] Historically, surgery has been the first-line option, especially when the lesion is located superficially and is directly accessible. Ligation of the blood vessel causing the lesion is the initial step in surgery, followed by excision of the ligated segment.[15] However, surgical removal of a pseudoaneurysm has inherent limitations, such as scar formation, intraoperative bleeding, and, in rare cases, tissue perfusion problems.[14] As an alternative to surgery, advances in interventional radiology have provided an effective option for treating pseudoaneurysms through endovascular embolization, with excellent results reported.[16] Interventional radiology offers a less invasive and more selective approach compared to traditional surgical techniques. However, this method requires specialized equipment and a well-trained radiologist.[11] In our hospital, endovascular embolization is not available. Due to active bleeding from the lesion and the presence of an external scar, urgent surgical intervention was chosen as the first-line treatment.

CONCLUSION

In conclusion, a pseudoaneurysm of the STA as a complication of a dog bite has not been previously reported in the literature. Given the limited data on the diagnosis, management, and treatment of STA pseudoaneurysms, it is crucial to include them in the differential diagnosis, particularly when trauma has occurred near the anatomical site. Physicians should also recognize ultrasound as a valuable diagnostic tool in such cases.

Acknowledgement: Special thanks to Balıkesir University Faculty of Medicine, Department of Radiology for technical assistance and diagnosis. Their extraordinary contributions have greatly improved the quality of this case report.

Peer-review: Externally peer-reviewed.

Conflict of Interest: None declared.

Financial Disclosure: The author declared that this study has received no financial support.

REFERENCES

1. Conner WC 3rd, Rohrich RJ, Pollock RA. Traumatic aneurysms of the face and temple: A patient report and literature review, 1644 to 1998. Ann Plast Surg 1998;41:321–6. [CrossRef]
2. Kuang R, Zhou J, Deng J, Xia T, Li M. Case report: A case of a child with facial foreign body abscess and facial artery pseudoaneurysm. Front Pediatr 2022;10:886031. [CrossRef]
3. Ali SS, Ali SS. Dog bite injuries to the face: A narrative review of the literature. World J Otorhinolaryngol Head Neck Surg 2022;8:239–44. [CrossRef]
4. Baba A, Kurokawa R, Kurokawa M, Reifeiss S, Policeni BA, Ota Y, et al Advanced imaging of head and neck infections. J Neuroimaging 2023;33:477–92. [CrossRef]
5. Graham JK, Colio PA. Dog bites with resultant periorbital cellulitis. Adv Emerg Nurs J 2025;47:31–6. [CrossRef]
6. Rivera PA, Dattilo JB. Pseudoaneurysm. In: StatPearls. Treasure Island (FL): StatPearls Publishing; 2024.
7. Hosseinzadeh A, Shahriarirad R, Dalfardi F, Arianpour H, Zarimeidani F. An unsuspected extracranial internal carotid pseudoaneurysm following dog bites: A case report and review of literature. Int J Emerg Med 2024;17:108. [CrossRef]
8. Gowda G, Mendoza D, Tullos A, Zagory J, Sheahan M. Temporal artery pseudoaneurysm in a pediatric patient. J Vasc Surg Cases Innov Tech 2023;9:101305. [CrossRef]
9. Miller SJ, Copass M, Johansen K, Winn HR. Stroke following rottweiler

attack. Ann Emerg Med 1993;22:262–4. [CrossRef]
10. Calkins CM, Bensard DD, Partrick DA, Karrer FM. Life-threatening dog attacks: A devastating combination of penetrating and blunt injuries. J Pediatr Surg 2001;36:1115–7. [CrossRef]
11. Srinivasan S, Lohan R, Tan HK, Chung R, Babu SB. Usefulness of ultrasonography in diagnosis, percutaneous management and follow up of post-traumatic scalp pseudoaneurysms. J Clin Ultrasound 2018;46:558–61. [CrossRef]
12. Chen SP, Su X. Superficial temporal artery arteriovenous fistula and pseudoaneurysm: The yin-yang sign. Radiology 2020;294:508. [CrossRef]
13. Mennitt K, Deol M, Gao J. Emergency color Doppler sonography of the extremity artery: A pictorial essay. Clin Imaging 2017;42:240–8. [CrossRef]
14. Dediol E, Manojlovic S, Biocic J, Franceski D, Ivanac G. Facial artery pseudoaneurysm without evidence of trauma. Int J Oral Maxillofac Surg 2011;40:988–90. [CrossRef]
15. Ahn HS, Cho BM, Oh SM, Park SH. Traumatic pseudoaneurysm of the superficial temporal artery in a child: A case report. Childs Nerv Syst 2010;26:117–20. [CrossRef]
16. Buxo Z, Rexroth J, Johnson BS, Fessler RD, Carron M. Pseudoaneurysm of the lingual artery in a patient with facial trauma from gunshot wounds. J Craniofac Surg 2025;36:e122–4. [CrossRef]

CASE REPORT - *ÖZ*

Dört yaşındaki çocuk hastada köpek ısırığı sonrası görülen süperfisiyal temporal arter psödoanevrizması: Literatürdeki ilk vaka

Ekstrakraniyal arteriyel sistemin psödoanevrizmaları nadirdir. Bunun nedeni, yüzeysel damarların boyutlarının ince ve çaplarının küçük olmasıdır. Bu yazıda, üç ay önceki köpek ısırması sonrasında 4 yaşındaki bir çocukta yüzeysel temporal arterde oluşan psödoanevrizma ve kliniği sunuldu. Acil servise başvuran hastanın lezyonu ilk olarak muhtemelen bir yabancı cisim ile abse oluşumu olarak düşünülmüş ve drene edilmeye çalışılmıştır. İnsizyon sonrası lezyonun abse olmadığı, aktif kanama ve trombüslerin fark edilmesi üzerine plastik, rekonstrüktif ve estetik cerrahi kliniği'ne yönlendirilmiştir. Yapılan fizik muayenede sol frontotemporal bölgede, kaş üstünde, 21x18x12 milimetre boyutlarında ele gelen kitle tespit edildi. Lokal enflamatuvar belirtiler veya fluktasyon saptanmadı. Üst yüz mimikleri ve kaş hareketleri normaldi. Laboratuvar testleri normal sonuçlar verdi. Doppler ultrasonografide "yin ve yang işareti" adı verilen, girdap şeklinde belirgin bir psödoanevrizma ile birlikte kısmi tromboz saptandı. Hasta, sızıntı şeklinde aktif kanaması olması nedeniyle acil ameliyata alındı ve yüzeysel temporal arterin ön dalı, debridman ve kan pıhtılarının uzaklaştırılmasından sonra psödoanevrizma boynuna kadar disseke edildi. Lezyonun, kaşa kadar olan derin kısmında yaklaşık 1 cm çapında psödoanevrizma görüldü ve arter, segmental kilitli sütür ile anevrizma her iki ucundan bağlanarak eksize edildi. Ameliyat sonrası hasta, komplikasyonsuz olarak klinikte izlendi ve taburcu edildi. Patolojik analizde, tümör duvarının organizasyonlu karışık trombüsten oluştuğu görüldü. Hastanın takipleri sırasında herhangi bir komplikasyon gelişmedi. Sunulan vakada da görüldüğü üzere, travmatik patolojilerin gözden kaçırılmaması için detaylı bir anamnez alınması, titiz bir klinik muayene yapılması ve ultrason dâhil detaylı görüntüleme çalışmalarının yapılması büyük önem taşımaktadır. Bu tür önlemler, bu gibi nadir vakalarda altta yatan tıbbi durumların erken tespiti ve yönetimini sağlamak, böylece daha fazla komplikasyonu önlemek ve prognozu iyileştirmek için gereklidir.

Anahtar sözcükler: Köpek ısırığı travması; psödoanevrizma; superfisial temporal arter.

Ulus Travma Acil Cerrahi Derg 2025;31(5):486-489 DOI: 10.14744/tjtes.2025.94797