CASE REPORT

Rare complication of a common procedure: Pneumomediastinum following an endodontic procedure

Cemre Ozenbas,[1] Sercan Aydin[2]

[1]Department of Radiology, Izmir Tınaztepe University, Private Buca Hospital, İzmir-*Türkiye*
[2]Department of Thoracic Surgery, Buca Seyfi Demirsoy Training And Research Hospital, İzmir-*Türkiye*

ABSTRACT

Pneumomediastinum is a rare but potentially serious complication characterized by the presence of air within the mediastinal structures. Although typically associated with thoracic trauma or vigorous coughing, it can also occur after dental procedures involving high-speed air-turbine drills. During such procedures, air may enter the cervical fascial planes and extend to the mediastinum, posing risks such as deep neck infections or mediastinitis. This report describes the case of a 38-year-old woman who developed cervical emphysema and pneumomediastinum on the same day following endodontic treatment. Computed tomography (CT) imaging revealed air densities extending from the submandibular region to the mediastinum. There was no evidence of pneumothorax, pleural effusion, or pericardial effusion. The patient was managed conservatively with oxygen therapy and intravenous antibiotics, leading to complete recovery within one week. This case underscores the importance of recognizing pneumomediastinum in patients presenting with neck swelling and subcutaneous crepitus after dental procedures. As it can be mistaken for postoperative edema, infection, or an allergic reaction, early CT imaging is essential for accurate diagnosis and prompt management. Raising awareness of this rare complication among healthcare professionals is critical to ensuring timely detection and effective treatment.

Keywords: Dental; endodontic; pneumomediastinum.

INTRODUCTION

Pneumomediastinum, defined by the presence of air within the mediastinal structures, is an uncommon complication that can result from various causes, including trauma, infections, or spontaneous events. While it is typically associated with thoracic injuries or intense episodes of coughing, dental procedures have also been identified as rare triggers of pneumomediastinum.[1,2]

Tooth extractions, particularly those involving high-speed air-turbine drills, can introduce air into the subcutaneous tissues. This air may then travel along fascial planes and potentially reach the mediastinum.[3] Although often benign and self-limiting, pneumomediastinum can enable the spread of oral flora through the deep cervical fascial planes into the mediastinum, resulting in serious complications such as deep neck infections, thrombophlebitis, and mediastinitis.[1,4]

In this report, we present a rare case of cervical emphysema and pneumomediastinum following an endodontic procedure. The patient presented to the emergency department with swelling in the jaw and neck. We discuss the clinical presentation, emphasize key diagnostic considerations, and outline the treatment strategies used in this case.

CASE REPORT

A 38-year-old female patient with no known medical history presented to the emergency department with swelling of the jaw, left side of the face, and neck. Upon further questioning, it was revealed that she had undergone a root ca-

Cite this article as: Ozenbas C, Aydin S. Rare complication of a common procedure: Pneumomediastinum following an endodontic procedure. Ulus Travma Acil Cerrahi Derg 2025;31:490-492.

Address for correspondence: Cemre Ozenbas
Department of Radiology, Izmir Tınaztepe University, Private Buca Hospital, İzmir, Türkiye
E-mail: cozenbas@hotmail.com

Ulus Travma Acil Cerrahi Derg 2025;31(5):490-4924 DOI: 10.14744/tjtes.2025.63531
Submitted: 01.01.2025 Revised: 23.02.2025 Accepted: 24.02.2025 Published: 05.05.2025
OPEN ACCESS This is an open access article under the CC BY-NC license (http://creativecommons.org/licenses/by-nc/4.0/).

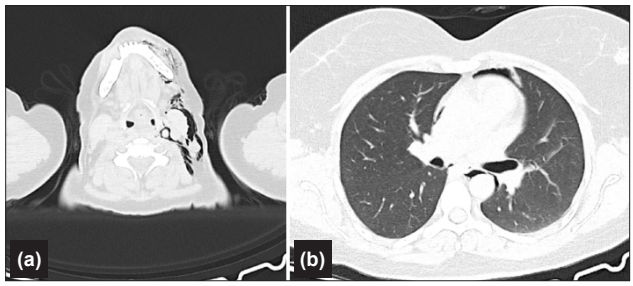

Figure 1. (a) Axial computed tomography (CT) image demonstrates widespread air densities in the subcutaneous tissues and within the deep neck fascial planes on the left side of the jaw. **(b)** Axial CT image reveals air densities within the mediastinum.

nal procedure earlier that day. Physical examination showed widespread edema and crepitus involving the jaw, left side of the face, neck, and supraclavicular region. Her vital signs were stable, and laboratory results were within normal limits. The presence of crepitus raised suspicion for emphysema and pneumomediastinum, prompting a computed tomography (CT) scan of the neck and thorax. CT imaging revealed air densities extending from the submandibular region through the neck to the mediastinum, involving both superficial and deep tissue planes. Air was also noted around the heart and extending down to the level of diaphragm (Figures 1 and 2). There was no evidence of pneumothorax, pleural effusion, or pericardial effusion.

The patient was admitted for observation and started on oxygen therapy along with intravenous antibiotics. After a



Figure 2. Coronal computed tomography (CT) reformat image shows air tracking from the deep fascial planes on the left side of the neck into the mediastinum, with air surrounding the major vascular structures.

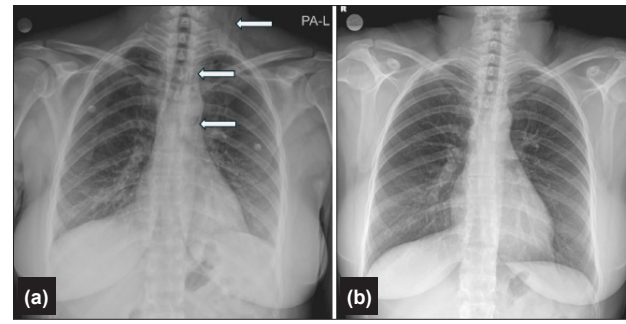

Figure 3. (a) Posteroanterior (PA) chest radiograph obtained one day after endodontic treatment shows lucencies indicating the presence of air in the left side of the neck and the mediastinum (arrows). **(b)** PA chest radiograph obtained one week after endodontic treatment demonstrates complete resolution of the lucencies consistent with the previously identified air.

three-day hospital stay, the patient was discharged in good condition. A follow-up chest X-ray performed one week later showed resolution of subcutaneous emphysema and pneumomediastinum (Fig. 3). Written informed consent was obtained from the patient for this case report, including permission to share imaging for academic purposes.

DISCUSSION

The clinical presentation of pneumomediastinum can vary, ranging from mild subcutaneous crepitus to more concerning symptoms such as dyspnea, chest pain, or neck swelling. On auscultation, it may be identified by a characteristic "crunching" sound synchronized with the cardiac cycle, known as Hamman's crunch. In some cases, it may mimic cardiac tamponade due to increased intrapulmonary pressure.[5]

Imaging plays a critical role in the diagnosis of pneumomediastinum. Posteroanterior and lateral chest radiographs are commonly used, with the lateral view being essential, as up to 50% of cases may be missed if only the posteroanterior view is performed. Key radiographic signs include a hyperlucent band in the retrosternal area, radiolucent lines extending into the neck, and air outlining mediastinal structures such as the aorta, trachea, or esophagus.[6,7] Kaneki et al.[8] reported that up to 30% of spontaneous pneumothorax cases may show normal findings on standard radiographs. Therefore, CT is considered the gold standard for diagnosing pneumomediastinum.

Pneumomediastinum following dental procedures is a rare but documented complication. Spille et al.,[9] in their literature review, identified 33 cases of pneumomediastinum related to dental treatments between 2010 and 2021. Of these cases, 48.5% occurred after tooth extractions, while 51.5% followed other treatments such as fillings or endodontic procedures. Diagnosis was made using CT in 90.9% of cases, and all but one patient, who required surgical intervention, were treated with intravenous antibiotics. Between 1960 and 2012, only seven cases of pneumomediastinum following endodon-

tic treatment were reported.[10] In our case, pneumomediastinum developed following a root canal procedure.

In more than 90% of cases, pneumomediastinum develops within the first hour after tooth extraction; however, there are reports in the literature of cases being identified up to one week after the procedure.[11,12] In our case, pneumomediastinum was detected on the same day as the endodontic treatment.

Jaw and neck swelling following dental procedures can easily be mistaken for postoperative edema, allergic reaction, or infection. Without a thorough physical examination and detailed medical history, emphysema and pneumomediastinum may go undetected. These conditions should be considered in patients presenting to the emergency department with neck swelling after dental treatment. In suspected cases, CT imaging is essential for early diagnosis and to prevent potential complications.

CONCLUSION

Pneumomediastinum is a rare but serious complication of dental procedures that requires prompt recognition and appropriate management. This case highlights the importance of considering pneumomediastinum in patients presenting with neck swelling and subcutaneous crepitus following dental treatment. Early diagnosis through CT imaging and timely intervention can prevent severe complications and lead to favorable outcomes. Increased awareness among healthcare providers is essential for improving early detection and enhancing patient care.

Peer-review: Externally peer-reviewed.

Authorship Contributions: Concept: C.O.; Design: C.O.; Supervision: S.A.; Resource: C.O., S.A.; Materials: C.O., S.A.; Data collection and/or processing: C.O., S.A.; Analysis and/or interpretation: C.O.; Literature review: C.O.; Writing: C.O.; Critical review: S.A.

Conflict of Interest: None declared.

Financial Disclosure: The author declared that this study has received no financial support.

REFERENCES

1. Kumbasar U, Oktay Peker R, Demircin M, Dogan R. Rare mediastinal complications of dental procedures. Curr Thorac Surg 2019;4:95–8. [CrossRef]
2. Haddad C, Awali M, Ismail S, Saad N, Choucair J. Pneumomediastinum following dental extraction–a case report in a tertiary hospital. Glob J Med Clin Case Rep 2022;9:26–8. [CrossRef]
3. Brzycki RM. Case report: Subcutaneous emphysema and pneumomediastinum following dental extraction. Clin Pract Cases Emerg Med 2021;5:58–61. [CrossRef]
4. Fukuchi M, Suzuki O, Nasu D, Koizumi K, Muta Y, Imaizumi H, et al. Descending necrotizing mediastinitis treated with tooth extractions following mediastinal and cervical drainage. Case Rep Gastroenterol 2015;9:311–6. [CrossRef]
5. Kouritas VK, Papagiannopoulos K, Lazaridis G, Baka S, Mpoukovinas I, Karavasilis V, et al. Pneumomediastinum. J Thorac Dis 2015;7:S44–9.
6. Bejvan SM, Godwin JD. Pneumomediastinum: Old signs and new signs. AJR Am J Roentgenol 1996;166:1041–8. [CrossRef]
7. Ba-Ssalamah A, Schima W, Umek W, Herold CJ. Spontaneous pneumomediastinum. Eur Radiol 1999;9:724–7. [CrossRef]
8. Kaneki T, Kubo K, Kawashima A, Koizumi T, Sekiguchi M, Sone S. Spontaneous pneumomediastinum in 33 patients: Yield of chest computed tomography for the diagnosis of the mild type. Respiration 2000;67:408–11. [CrossRef]
9. Spille J, Wagner J, Spille DC, Naujokat H, Gülses A, Wiltfang J, et al. Pronounced mediastinal emphysema after restorative treatment of the lower left molar-A case report and a systematic review of the literature. Oral Maxillofac Surg 2023;27:533–41. [CrossRef]
10. Durukan P, Salt O, Ozkan S, Durukan B, Kavalci C. Cervicofacial emphysema and pneumomediastinum after a high-speed air drill endodontic treatment procedure. Am J Emerg Med 2012;30:2095. [CrossRef]
11. Monsour PA, Savage NW. Cervicofacial emphysema following dental procedures. Aust Dent J 1989;34:403–6. [CrossRef]
12. Ocakcioglu I, Koyuncu S, Kupeli M, Bol O. Pneumomediastinum after tooth extraction. Case Rep Surg 2016;2016:4769180. [CrossRef]

ORİJİNAL ÇALIŞMA - *ÖZ*

Sık uygulanan bir prosedürün nadir bir komplikasyonu: Endodontik tedavi sonrası pnömomediastinum

Pnömomediastinum, mediastinal yapılarda hava bulunmasıyla karakterize, nadir ancak potansiyel olarak ciddi bir komplikasyondur. Genellikle torasik travma veya şiddetli öksürük gibi nedenlerle ilişkilendirilse de, yüksek hızlı hava türbinli aletlerin kullanıldığı dental işlemler sonrasında da ortaya çıkabilir. Bu işlemler sırasında servikal fasyalara giren hava, mediastene kadar ilerleyebilir. Çoğu zaman kendiliğinden düzelmesine rağmen, zamanında müdahale edilmezse derin boyun enfeksiyonları, mediastinit veya tromboflebit gibi ciddi komplikasyonlara yol açabilir. Bu yazıda, endodontik tedavi sonrası aynı gün çene ve boyunda şişlik ile başvuran 38 yaşındaki bir kadının servikal amfizem ve pnömomediastinum vakası sunuldu. Bilinen bir hastalığı olmayan hastanın fizik muayenesinde, ödeme ek olarak cilt altı krepitasyonu saptanmıştır. Bilgisayarlı tomografi (BT) görüntülemesi, submandibular bölgeden mediastene kadar uzanan hava dansitelerini göstermiştir. Pnömotoraks, plevral veya perikardiyal efüzyon saptanmamıştır. Hasta, oksijen tedavisi ve intravenöz antibiyotik tedavisiyle konservatif olarak yönetilmiş ve bir hafta içinde tamamen iyileşmiştir. Bu vaka, dental işlemler sonrası boyun şişliği ve cilt altı krepitasyonu ile başvuran hastalarda pnömomediastinumun tanınmasının önemini vurgulamaktadır. Postoperatif ödem, enfeksiyon ve alerjik durumlarla karışabileceğinden, erken BT görüntülemesi doğru tanı ve zamanında müdahale için kritik öneme sahiptir. Sağlık profesyonellerinin bu nadir komplikasyona karşı farkındalığı, erken teşhis ve etkili hasta yönetimi sağlanmasında kilit rol oynar.

Anahtar sözcükler: Diş; endodonti; pnömomediastinum.

Ulus Travma Acil Cerrahi Derg 2025;31(5):490-492 DOI: 10.14744/tjtes.2025.63531