EXPERIMENTAL STUDY

Evaluation of hepatic and remote organ injury in an experimental liver ischemia-reperfusion model in rats and the effects of quercetin on this damage

Neziha Senem Arı,[1] Esin Yuluğ,[2] Bünyamin Arı,[3] Cansu Kaya,[4] Gökşen Derya Reis Köse,[5] Tuğba Zengin,[6] Oğuzhan Keskin,[7] Tuğba Arıcı,[8] Engin Yenilmez[2]

[1]Department of Histology and Embryology, Kutahya Health Sciences University Faculty of Medicine, Kutahya-*Türkiye*
[2]Department of Histology and Embryology, Karadeniz Technical University Faculty of Medicine, Trabzoc-*Türkiye*
[3]Department of Orthopedics and Traumatology, Kütahya Health Sciences University Faculty of Medicine, Kutahya-*Türkiye*
[4]Department of Medical Biology, Karadeniz Technical University Faculty of Medicine, Trabzon-*Türkiye*
[5]Ivf Center, Zeynep Kamil Women and Children Diseases Traning and Research Hospital, İstanbul-*Türkiye*
[6]Ivf Center, Trabzon Kanuni Training and Research Hospital, Trabzon-*Türkiye*
[7]Department of Pulmonary Disease, Çanakkale University Faculty of Medicine, Çanakkale-*Türkiye*

ABSTRACT

BACKGROUND: This study aims to show the changes in the liver, lung, kidney, and heart in the liver ischemia-reperfusion model in rats and the effect of quercetin on these changes histopathologically and immunohistochemically.

METHODS: Eighteen Sprague Dawley rats were classified into three groups: Group 1 sham, Group 2 ischemia-reperfusion (IR), Group 3 ischemia-reperfusion + quercetin (IR+Q). For three days, distilled water was given to Group 1, and quercetin was given to Group 3 via gavage. At the end of the third day, abdominal opening-closing was applied to Group 1, and 4 hours of reperfusion was applied to Groups 2 and 3 after 1 hour of ischemia by clamping the hepatoduodenal ligament, and all rats were euthanized. Liver, lung, kidney, and heart tissue samples were stained with Hematoxylin Eosin (HE), Masson Trichrome, Periodic Acid-Schiff (PAS), and TUNEL (Terminal deoxynucleotidyl transferase (TdT) deoxyuridine triphosphate nick end labeling assay) to assess apoptosis and examined histopathologically and immunohistochemically under a light microscope.

RESULTS: In the liver, the damage score was significantly higher in the IR group than in the sham group, while it was significantly lower in the IR+Q group than in the IR group. While there was no significant difference between the groups in semi-quantitative scoring parameters, the Apoptotic Index was significantly higher in the IR group than in the sham group and significantly lower in the IR+Q group than in the IR group. In the lung, no significant difference in lung damage scores between the groups was observed. While the Apoptotic Index was significantly higher in the IR group than in the sham group, it was significantly lower in the IR+Q group than in the IR group. In the kidneys, tubular cell degeneration and intertubular vascular congestion were significantly higher in the IR group than in the sham group. While the Apoptotic Index was higher in the IR group than in the sham and IR+Q groups, it was higher in the IR+Q group than in the sham group. In the heart, there was no difference between the groups in terms of myocardial cell degeneration and vascular damage. The apoptotic index was significantly higher in the IR group than in the sham and IR+Q groups.

CONCLUSION: Our results indicate that histopathological damage occurs in the liver, lung, kidney, and heart in the experimentally created IR model, and quercetin application decreases IR-related damage and apoptosis in these organs.

Keywords: Ischemia-reperfusion injury; liver; quercetin; remote organ.

Cite this article as: Arı NS, Yuluğ E, Arı B, Kaya C, Reis Köse GD, Zengin O, et al. Evaluation of hepatic and remote organ injury in an experimental liver ischemia-reperfusion model in rats and the effects of quercetin on this damage. Ulus Travma Acil Cerrahi Derg 2025;31:823-830.

Address for correspondence: Neziha Senem Arı
Department of Histology and Embryology, Kutahya Health Sciences University Faculty of Medicine, Kutahya, Türkiye
E-mail: nezihasenem.ari@ksbu.edu.tr

Ulus Travma Acil Cerrahi Derg 2025;31(9):823-830 DOI: 10.14744/tjtes.2025.61423
Submitted: 26.03.2025 Revised: 10.04.2025 Accepted: 01.06.2025 Published: 05.09.2025
OPEN ACCESS This is an open access article under the CC BY-NC license (http://creativecommons.org/licenses/by-nc/4.0/).

INTRODUCTION

An organ's inability to meet oxygen and nutrient demands due to impaired blood flow causes depletion of energy stores, metabolite accumulation, and oxidative stress, resulting in ischemia within a specified time.

Reinstating blood flow aggravates cellular damage through the enhancement of reactive oxygen radicals (ROS) and the inflammatory response. This condition is called ischemia-reperfusion damage (IRD). The risk of liver ischemia-reperfusion damage is heightened in liver tissue following trauma or prolonged surgical procedures like tumor resection and transplantation.[1]

Experimental animal models, in which inflammatory factors like chemokines, cytokines, and transcription factors are released due to oxidative stress and reperfusion following ischemia, have helped elucidate the pathophysiology of IRD.[2] Mitochondrial peptides from necrotic cells during ischemia stimulate Kupffer cells, macrophages in the liver. Kupffer cells release ROS and inflammatory mediators, inducing apoptosis in endothelial cells of vascular structures. The inflammatory response intensifies with the presence of neutrophils and inflammatory mediators that infiltrate the liver parenchyma.[3]

The presence of IRD in the liver can also threaten other organs. This phenomenon occurs because the inflammatory response is carried to distant organs with the help of cytokines released as a result of oxidative stress. In some cases, this response can lead to fatal outcomes by causing multiple organ dysfunction syndrome (MODS) or systemic inflammatory response syndrome (SIRS).[4] Oxidative stress and increased ROS levels are the main pathologies targeted for the prevention and treatment of IRD. Antioxidant treatment mitigates liver problems caused by IRD.[2]

Quercetin, a flavonoid present in numerous plants such as seeds, red onions, blueberries, and apples, is a natural antioxidant. This pigment exhibits antioxidant, anti-inflammatory, and antifibrotic activities. Quercetin mitigates ischemia-reperfusion injury in multiple organs and tissues.[5] Quercetin's antioxidant properties include free radical scavenging, nitric oxide synthase reduction, and xanthine oxidase inhibition.[6] It exerts its anti-inflammatory effect by inhibiting cyclooxygenase and lipoxygenase enzymes and by reducing inflammatory mediators such as prostaglandins and leukotrienes.[7] The heme oxygenase 1 enzyme, crucial for antioxidant and anti-inflammatory responses, is activated by it.[2]

This study explored the histopathological alterations in the liver, lung, kidney, and heart tissues of rats caused by IRD in the liver, assessing the impact of quercetin.

MATERIALS AND METHODS

The experimental procedures were carried out at Karadeniz Technical University Medical Faculty Surgical Research Center in Trabzon, Türkiye. Eighteen female Spraque Dawley rats weighing between 250 and 300 g were used for the study. The animals were treated in accordance with the National Institutes of Health's Guide for the Care and Use of Laboratory Animals. The Institutional Animal Ethical Committee of Karadeniz Technical University, Trabzon, Türkiye approved our study (protocol no: 2017-25). The rats were housed in type III cages, provided with tap water and standard rat chow (Bayramoğlu Yem ve Un Sanayi Tic. A.Ş., Erzurum, Türkiye), and maintained at a temperature of 22±1°C under a 12 hours light-12 hours dark cycle.

Experimental Design

In the study, rats were classified into three groups.

Group 1 (Sham group, n=6): The rats, which received 1 mL of distilled water by gavage for 3 days before the experiment, were sacrificed by exsanguination, and their organs were removed 4 hours after opening the abdomen, waiting 1 hour, and then closing it.

Group 2 (Ischemia-Reperfusion (IR) group, n=6): On the day of the experiment, rats reperfused for 4 hours after 1 hour of ischemia were sacrificed by exsanguination, and their organs were removed.

Group 3 (Ischemia-Reperfusion + Quercetin (IR+Q) group, n=6): The rats that were given quercetin (Sigma-Aldrich; Merck KGaA, Darmstadt, Germany) by gavage for 3 days before the experiment and reperfused for 4 hours after 1 hour of ischemia were sacrificed by exsanguination, and their organs were removed.

Experimental Protocol

The hepatic ischemia was induced through clamping of the portal vein, hepatic artery, and bile duct (hepaticoduodenal ligament) during the abdominal median laparotomy under general anesthesia. After an hour, the liver was reperfused for 4 hours before the rats were sacrificed by exsanguination. For histological analysis, the liver, lung, kidney, and heart were removed.

Histological Procedures

In the tissues prepared for examination with a light microscope, Hematoxylin-Eosin (H&E) staining was performed to observe the histological structure, and Masson's trichrome staining was performed to examine connective tissue. Periodic acid-Shiff (PAS) staining was performed to investigate glycogen accumulation in the liver, lung, kidney, and heart; microvilli and basal membranes of epithelial cells in kidney tubules; and goblet cells in the lung.

Hepatic ischemia/reperfusion damage was graded (0 for minimal, 1 for mild, 2 for moderate, and 3 for severe) based on patterns of cytoplasmic vacuolization, nuclear pyknosis, hypereosinophilia, loss of cell borders, and neutrophil infiltration.[8] A semi-quantitative score from 0-3 (ranging from none to

severe) was assigned to hepatocytes degeneration, pyknotic nuclei, sinusoidal dilatation, mononuclear cell infiltration, vascular congestion, and hemorrhage in the liver.[9]

Semi-quantitative damage scoring in the evaluation of lung tissue was performed as follows: Grade 0, normal morphology; Grade 1, mild intra-alveolar edema and inflammatory cell infiltration; Grade 2, moderate alveolar edema and inflammatory cell infiltration; Grade 3, inflammatory cell infiltration with severe alveolar edema and focal hemorrhage; Grade 4, diffuse inflammatory cell infiltration and deterioration in the alveolar structure.[10]

In the evaluation of kidney tissue, degeneration of tubular cells (tubular dilatation, shedding, and vacuolization of tubular epithelial cells) and intertubular vascular congestion were scored semi-quantitatively as Grade 0, none; Grade 1, mild; Grade 2, moderate; and Grade 3, severe.[11]

Myocardial cell degeneration scoring in the evaluation of heart tissue was performed as Grade 0 (normal), no degeneration in myocytes; Grade 1 (mild), few degenerated myocytes; Grade 2 (moderate), myocyte degeneration around 50%; Grade 3 (severe), myocyte degeneration over 50%.[12]

Immunohistochemical Procedures

Terminal deoxynucleotidyl transferase (TdT) deoxyuridine triphosphate (dUTP) nick end labeling assay (TUNEL) staining was performed to evaluate apoptosis in organs (11 684 817 910 Roche Diagnostic, Mannheim, Germany). TUNEL (+) cells with homogeneously stained brown nuclei without areas of necrosis were defined as apoptotic. In the evaluation, apoptotic and normal cells were recorded by counting 100 cells in 5 different areas at ×400 magnification, and the Apoptotic Index (AI) was calculated as follows: AI=TUNEL (+) cell number/total cell number × 100.

RESULTS

Histological and Immunohistochemical Evaluation of Liver Tissue

Pyknotic hepatocyte nuclei with eosinophilic cytoplasm, hepatocyte degeneration, sinusoidal dilatation and congestion, centrilobular necrosis, hemorrhage, apoptosis, and reduced glycogen accumulation were observed in the liver of the IR group. In the IR+Q group, sinusoidal dilatation, hepatocytes with occasional eosinophilic cytoplasm and pyknotic nuclei, and a higher glycogen accumulation were detected compared to the IR group (Fig. 1).

While the damage score in the IR group was significantly higher than in the sham group (p<0.008), the damage score in the IR+Q group was significantly lower than that in the IR group (p=0.015). No statistically significant difference in semi-quantitative scoring was found between the groups (p>0.05) (Table 1).

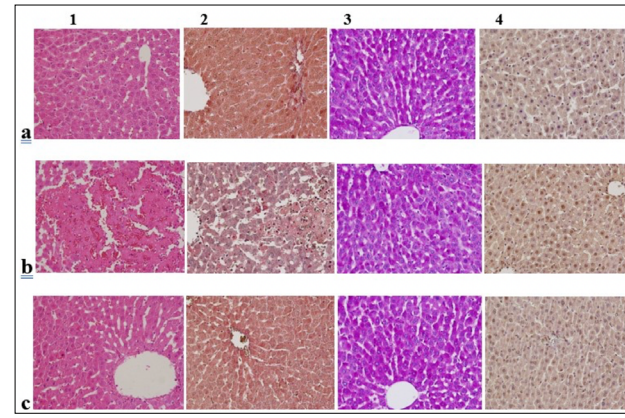

Figure 1. Liver (Line a: Sham group, Line b: IR group, Line c: IR+Q group); Column 1: H&E, Column 2: Masson trichrome, Column 3: PAS, Column 4: TUNEL staining (X400)

Table 1. Liver scoring results and Apoptotic Index (AI) evaluation

	Sham mean±SD	IR mean±SD	IR+Q mean±SD	P
Liver Dam. Score	0.5±0.84	2.5±0.84^{x}	0.67±1.21^{s}	<0.013
Hep. Deg.	0.33±0.51	2.17±1.32	0.67±1.21	<0.055
Pic. Nuc.	0.33±0.51	2.17±1.32	0.67±1.21	<0.055
Sin. Dil.	0.0±0.0	0.83±0.75	0.33±0.81	<0.052
Mon. Cell Inf.	0.0±0.0	0.83±0.75	0.33±0.81	<0.052
Vas. Cong.	0.0±0.0	1.50±1.22	1.50±1.22	<0.052
Hemorrhage	0.0±0.0	0.33±0.81	0.33±0.81	<0.588
Apoptotic Index (%)	26.33±0.51	63.97±6.84*	22.7±11.16°	p≤0.0001

Data were given as mean ± standard deviation. n=6 rats in each group. Liver Dam. Score: Liver Damage Score; Hep. Deg: Hepatocyte Degeneration; Pic. Nuc.: Pyknotic Nucleus; Sin. Dil.: Sinusoidal Dilation; Mon. Cell Inf: Mononuclear Cell Infiltration; Vas. Cong.: Vascular Congestion.^{x}: (p<0.008) Damage score in the IR group was found to be significantly higher than in the sham group. ^{s}: (p<0.015) In the IR+Q group, the damage score was significantly decreased compared to the IR group. *: (p≤0.0001) Apoptotic Index was found to be higher in the IR group than in the sham group. $^{\circ}$: (p≤0.0001) The Apoptotic Index was decreased in the IR+Q group compared to the IR group. No significant differences were found in the comparison of other parameters among the groups.

Table 2. Lung damage score and Apoptotic Index (AI) evaluation

	Sham mean±SD	IR mean±SD	IR+Q mean±SD	P
Lung Damage	1.17±0.41	2.17±1.17	1.50±0.55	p<0.152
Apoptotic Index (%)	25.12±7.84	59.21±9.46^{x}	35.22±5.8^{s}	p≤0.0001

Data were given as mean ± standard deviation. n=6 rats in each group. ^{x}: (p≤0.0001) The apoptotic index was found to be higher in the IR group than in the sham group. ^{s}: (p≤0.0001) The apoptotic index was decreased in the IR+Q group compared to the IR group.

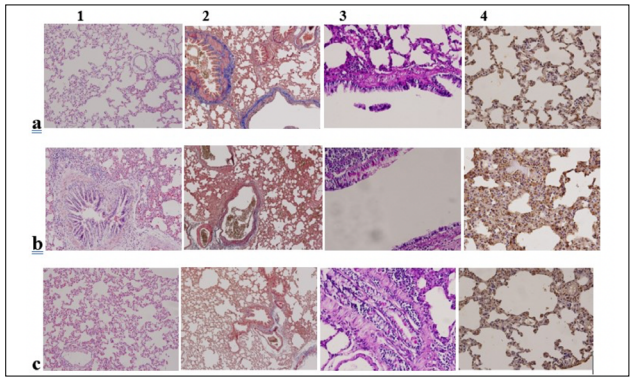

Figure 2. Lung (Line a: Sham group, Line b: IR group, Line c: IR+Q group); Column 1: H&E, Column 2: Masson trichrome, Column 3: PAS, Column 4: TUNEL staining (X400).

In the liver, the AI% obtained through the TUNEL method was markedly increased in the IR group compared to the sham group (p≤0.0001), but was substantially diminished in the IR+Q group relative to the IR group (p≤0.0001) (Table 1).

Histological and Immunohistochemical Evaluation of Lung Tissue

While an increase in alveolar epithelial thickness, vascular congestion, interalveolar hemorrhage, intra-alveolar edema, neutrophil infiltration were observed in the lung in the IR group, in the IR+Q group, there was a slight decrease in the thickening of the alveolar epithelium and interalveolar hemorrhage compared to the IR group. In addition, when the lung was evaluated with PAS staining, an increase in mucin secretion and goblet cells in the bronchial wall was observed in the IR and IR+Q groups (Fig. 2).

When the groups were evaluated in terms of lung damage score, no significant difference was found between the groups (p<0.152) (Table 2).

The apoptotic index in the IR group was significantly higher than that in the sham group (p≤0.0001), but it was significantly lower in the IR+Q group relative to the IR group (p≤0.0001).

Histological and Immunohistochemical Evaluation of Kidney Tissue

In the cortex of the kidney's IR group, detached and vacuolized tubular epithelial cells, dilated tubules, congested intertubular vessels, and increased intertubular collagen were detected, while the renal medulla showed cast structures and necrotic tubular epithelial cells within the lumen. In the IR+Q group, both cortical intertubular congestion with epithelial shedding and medullary shedding and necrosis with cast structures were observed. In Figure 3, interruptions in the brush border epithelium and basal membrane structures of the kidney were minimally observed in the sham group, infrequently in the IR+Q group, and significantly in the IR group upon PAS staining evaluation.

Tubular cell degeneration was significantly higher in the IR group than in the sham group (p<0.004) (Table 3). Again, intertubular vascular congestion was significantly higher in the IR group than in the sham group (p<0.015) (Table 3).

In the evaluation of the apoptotic kidney index, the apoptotic index in the IR group was significantly higher than in the sham and IR+Q groups (p≤0.0001, p≤0.0001, respectively); the apoptotic index in the IR+Q group was higher than in the sham group (p<0.001) (Table 3).

Table 3. Kidney damage score and Apoptotic Index (AI) evaluation

	Sham mean±SD	IR mean±SD	IR+Q mean±SD	P
Tub. Cell Deg.	0.50±0.55	2.17±0.75^{x}	1.00±0.90	p<0.014
Vas. Cong.	0.33±0.52	1.50±0.55°	0.50±0.55	p<0.014
Apoptotic Index (%)	17.25±20.89	76.6±10.15*	45.08±12.76∞	p≤0.0001

Data were given as mean ± standard deviation. n=6 rats in each group. Tub. Cell Deg.: Tubular Cell Degeneration; Vas. Cong.: Vascular Congestion. ^{x}: (p<0.004) Tubular cell degeneration was significantly higher in the IR group than in the sham group. °: (p<0.015) Intertubular vascular congestion was significantly higher in the IR group than in the sham group. *: (p≤0.0001) Apoptotic index was found to be significantly higher in the IR group than in the sham group. ∞: (p≤0.0001) The apoptotic index was significantly lower in the IR+Q group than in the IR group.

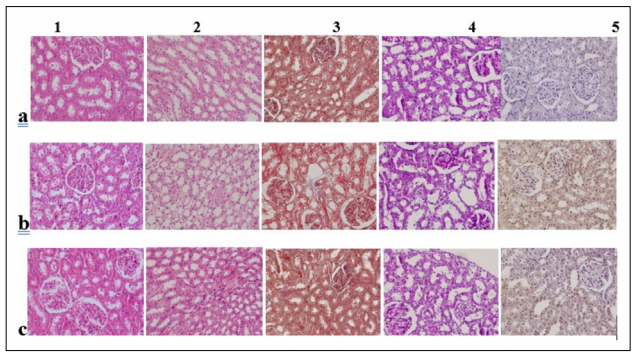

Figure 3. Kidney (Line a: Sham group, Line b: IR group, Line c: IR+Q group); Column 1: H&E, Column 2: H&E (renal medulla), Column 3: Masson trichrome, Column 4: PAS, Column 5: TUNEL staining (X400).

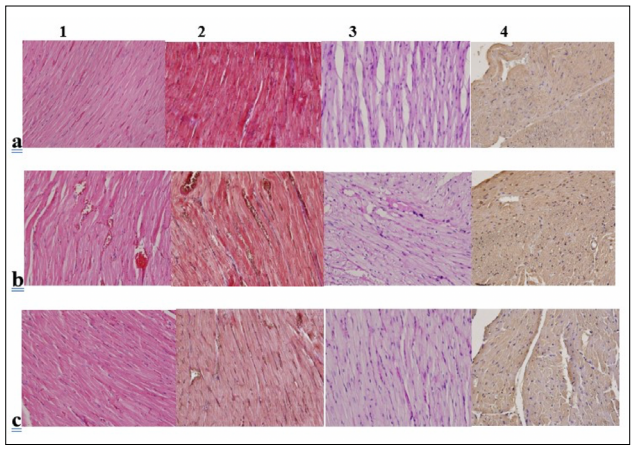

Figure 4. Heart (Line a: Sham group, Line b: IR group, Line c: IR+Q group); Column 1: H&E, Column 2: Masson trichrome, Column 3: PAS, Column 4: TUNEL staining (X400).

Histological and Immunohistochemical Evaluation of Heart Tissue

In the heart tissue of the IR group, degeneration and loss of striation in cardiac muscle fibers, perinuclear edema between muscle fibers, and vascular hemorrhage were observed; in the IR+Q group, a decrease in edema between perinuclear and muscle fibers was observed locally. When the groups were examined with Masson's trichrome staining, there was no difference between the groups in terms of collagen distribution. When the groups with PAS staining were evaluated, no difference was observed between the groups in the glycogen accumulation in the muscle fibers (Fig. 4).

When myocardial cell degeneration was evaluated, no significant difference was found between the groups (p<0.090). In addition, myocardial fibrosis and vascular congestion were scored semi-quantitatively. There were no patients with myocardial fibrosis. There were no significant differences between the groups in terms of vascular damage (Table 4).

The evaluation of the apoptotic index performed by the TUNEL technique in the heart showed that the apoptotic index was significantly higher in the IR group than in the sham and IR+Q groups (p≤0.0001, p≤0.0001, respectively) (Table 4).

DISCUSSION

Ischemia–reperfusion damage is the name given to the damage caused by the ischemic and inflammatory response that develops in the tissue after the blood flow is interrupted and restored. It is a common complication of the liver following prolonged liver surgery such as transplantation or tumor resection, after trauma, or in situations of shock.[1] Using an experimental liver IR model, we evaluated IRD in our study.

The complex, multifactorial pathophysiological process gives rise to IRD. Local tissue acidosis and ischemia triggering inflammatory response mediators and leukocyte migration in the blood lead to systemic damage and dysfunction. Acidosis and local ischemia developing in the tissue that cannot meet oxygen and nutrient needs cause systemic inflammatory response syndrome, which results in distant tissue damage and dysfunction through inflammatory mediators and leukocytes that mix with the blood.[4]

In the creation of the IRD model in the liver, clamping durations have varied. In our study, we imposed ischemia for an hour followed by reperfusion for four hours. A previous study investigated the impact of quercetin on the liver under experimentally induced IRD (45 minutes ischemia, 1 hour reperfusion).[13] Jaeschke distinguished between the acute (first

Table 4. Myocardial cell degeneration, heart vascular congestion score results, and Apoptotic Index (AI) evaluation

	Sham mean±SD	IR mean±SD	IR+Q mean±SD	P
Myo. Cell Deg.	1.17±0.98	2.33±0.82	1.67±0.52	p<0.090
Vas. Cong.	1.33±0.82	2.17±0.75	1.83±0.41	p<0.166
Apoptotic Index (%)	29.33±6.45	61.39±16.9^{x}	37.09±7.41^{s}	p≤0.0001

Data were given as mean ± standard deviation. n=6 rats in each group. Myo. Cell Deg.: Myocardial Cell Degeneration; Vas. Cong.: Vascular Congestion. ^{x}: (p≤0.0001) The Apoptotic Index was found to be significantly higher in the IR group than in the sham group. ^{s}: (p≤0.0001) The Apoptotic Index was significantly lower in the IR+Q group than in the IR group.

6 hours) and late/subacute (later 6 hours) phases of liver IRD. The acute phase is the period of increased ROS production, activation of Kupffer cells, and increased proinflammatory cytokines; the subacute phase is characterized by intense inflammatory cytokine and neutrophil infiltration.[14] The acute phase after IRD was evaluated in our study.

The researchers Taghizadieh et al.[15] observed a marked reduction in the hepatic antioxidants, including glutathione peroxidase (GPX) and superoxide dismutase (SOD), during the IRD process. These changes result in oxidative stress and cell damage.[1] Numerous studies have investigated the cellular impacts of excessive ROS activity in IRD, as well as the use of antioxidants to counteract these effects. The positive effects of several antioxidant agents like melatonin,[15-16] carnosine,[16] quercetin, and desferrioxamine[13] have been shown to improve IRD in previous research.

Quercetin is a potent antioxidant and anti-inflammatory flavonoid. Previous research reveals its ability to quench oxidative stress and inflammation through various mechanisms, including inhibiting lipid peroxide radical formation, binding metal ions, scavenging radicals, affecting inducible nitric oxide synthase activity, suppressing xanthine oxidase, reducing leukocyte immobilization, and inhibiting tumor necrosis factor-alpha (TNF-α).[6,13]

In Baykara's research, matching our IR durations, the IR group exhibited damaged hepatocyte cell cords, numerous and scattered hepatocyte necrosis, neutrophil infiltration within parenchymal regions, and sinusoidal enlargement and congestion, similar to our findings.[16] According to Tokyol et al.'s study,[13] histopathological findings and liver damage scores following a 45-minute ischemia and 1-hour reperfusion period were consistent with our results. In Baykara's study, whose IR durations were the same as in our research, in the IR group, the integrity of hepatocyte cell cords was impaired, multiple and diffuse hepatocyte necrosis areas, neutrophil infiltration in parenchymal areas, enlargement and congestion in sinusoids were observed in the IR group, compatible with the findings of our study.[16] The difference in general damage between the groups was statistically significant, whereas the differences in individual parameters were not. The insufficient number of rats might account for this outcome.

In the IRD of one organ, damage to distant organs may occur in addition. Systemic inflammation occurs due to oxidative mediators released during IRD and subsequent leukocyte adhesion through these mediators.[3] In our study, lung, kidney, and heart tissues were used to evaluate distant organ damage.

As it is the initial capillary bed the blood encounters following hepatic circulation, the liver experiences the greatest impact from the inflammatory mediators generated during IRD.[17] Major liver surgeries can result in both acute lung damage and acute respiratory failure syndrome, which are significant complications in IRD patients.[18] The IR+Q group showed decreased thickening of alveolar epithelium, vascular congestion, interalveolar hemorrhage, intra-alveolar edema, neutrophil infiltration, and increase in apoptosis, as well as decreased AI, compared to the IR group, but no significant difference was noted in damage scoring between the two groups. Although Oğuz et al.'s study[19] revealed histopathological changes due to liver IRD-induced lung tissue damage, they found that sulforaphane—an antioxidant and anti-inflammatory agent like quercetin—failed to mitigate this damage. Ninety minutes of ischemia and 18 hours of reperfusion increased high-mobility group box 1 (HMGB1) protein levels linked to inflammation in rat lungs.[18] Eight hours of liver reperfusion following 75 minutes of ischemia resulted in increased apoptosis and stress response enzymes in type II alveolar cells, inflammatory cytokines in plasma, and greater neutrophil ratio in bronchoalveolar lavage.[17] Similarly, we think the increase in mucin secretion and goblet cells in the bronchi in our study's IR and IR+Q groups is related to airway inflammation.

An organ most frequently affected by IRD in the liver is the kidney. The reported incidence of acute kidney damage after liver operations is between 40% and 85%.[20] When the kidney tissue after IRD was examined in our study, cellular degeneration and necrosis findings were observed in both cortex and medulla regions in the IR group. Again, in damage scoring, tubular cell degeneration and vascular congestion scores were higher in the IR group. However, although quercetin partially reduced histopathological deterioration, it was not effective in improving damage scoring. AI that increased in the IR group was found to be slightly lower in the IR+Q group. Miranda et al.[21] reported increased malondialdehyde (MDA) and myeloperoxidase (MPO) levels in the kidneys after liver IRD in rats. This study showed that the event is related to oxidative stress. In a study in which apoptosis and related Fas gene expression were measured in kidney tissue after liver transplantation, it has been shown that both events began 1 hour after transplantation and increased up to 12 hours.[22] In our study, sufficient IRD time was applied to apoptosis formation in accordance with these data. In a study by Takhtfooladi et al.,[23] in which ischemia for 30 minutes and reperfusion for 24 hours was applied in the liver, kidney damage was evaluated and, unlike our study, diffuse necrosis and glomerular fibrosis findings were observed. This difference may be because the study included the subacute period in terms of reperfusion.

In the IR+Q group, histopathological degeneration findings noted in the IR group, including nuclear pyknosis, perinuclear and interstitial edema, vascular hemorrhage, and congestion, were partially alleviated but without statistical significance. No evidence of myocardial cell degeneration, vascular damage, or myocardial fibrosis was found. A study with 150 minutes of ischemia and 12 hours of reperfusion yielded a high damage score due to myocardial necrosis and edema.[24] The difference is attributed to varying durations. In the IR+Q group, the heart tissue exhibited a decrease in AI levels

compared to the IR group. Applying IRD to heart tissue, as in our study, resulted in apoptosis, yet quercetin diminished this effect.[25]

We did not find any significant difference between the groups, except for a slight increase in intertubular collagen in the IR group, in the connective tissue of the sections of each of the four organs we stained with Masson Trichrome. This result may be due to the fact that our experimental period was not sufficient for collagen increase. We think that more precise results can be obtained by including the 6-24 hour subacute period of IRD in the experiment.

CONCLUSION

In the light of the findings, it was shown that the experimentally created IR model in the liver causes histopathological damage to the liver and distant organs, and quercetin has positive effects on this damage. For these results to be clinically applicable, there is a need for experimental and clinical studies to be carried out at different IRD times, at different doses of quercetin, supported by further investigations.

Ethics Committee Approval: This study was approved by the Karadeniz Technical University Ethics Committee (Date: 19.07.2017, Decision No: 2017-25).

Peer-review: Externally peer-reviewed.

Authorship Contributions: Concept: N.S.A., E.Y., C.K., O.K.; Design: N.S.A., E.Y., T.A.; Supervision: N.S.A, C.K., T.Z., E.Y.; Resource: N.S.A., E.Y., T.Z., T.A.; Materials: N.S.A., E.Y., B.A., E.Y.; Data collection and/or processing: N.S.A., B.A., G.D.R.K., E.Y.; Analysis and/or interpretation: N.S.A., B.A., C.K., E.Y.; Literature review: N.S.A., E.Y., O.K., T.A.; Writing: N.S.A., E.Y., G.D.R.K., O.K.; Critical review: N.S.A., C.K., T.Z., O.K.

Conflict of Interest: None declared.

Financial Disclosure: The author declared that this study has received no financial support.

REFERENCES

1. Montalvo-Jave EE, Escalante-Tattersfield T, Ortega-Salgado JA, Piña E, Geller DA. Factors in the pathophysiology of the liver ischemia-reperfusion injury. J Surg Res 2008;147:153-9. [CrossRef]
2. Li S, Fujino M, Takahara T, Li XK. Protective role of heme oxygenase-1 in fatty liver ischemia-reperfusion injury. Med Mol Morphol 2019;52:61-72. [CrossRef]
3. Oliveira THCD, Marques PE, Proost P, Teixeira MMM. Neutrophils: a cornerstone of liver ischemia and reperfusion injury. Lab Investig 2018;98:51-62. [CrossRef]
4. Guo WA. The search for a magic bullet to fight multiple organ failure secondary to ischemia/reperfusion injury and abdominal compartment syndrome. J of Surg Res 2012;184:792-3. [CrossRef]
5. Chen BL, Wang LT, Huang KH, Wang CC, Chiang CK, Liu SH. Quercetin attenuates renal ischemia/reperfusion injury via an activation of AMP-activated protein kinase-regulated autophagy pathway. J Nutr Biochem 2014;25:1226-34. [CrossRef]
6. Al-Harbi MS. Antioxidant, protective effect of black berry and quercetin against hepatotoxicity induced by aluminum chloride in male rats. Int J Pharmacol 2019;15: 494-502. [CrossRef]
7. Warren CA, Paulhill KJ, Davidson LA, Lupton JR, Taddeo SS, Hong MY, et al. Quercetin may suppress rat aberrant crypt foci formation by suppressing inflammatory mediators that influence proliferation and apoptosis. J Nutr 2009;139:101-5. [CrossRef]
8. Kesik V, Guven A, Vurucu S, Tunc T, Uysal B, Gundogdu G, et al. Melatonin and 1400 W ameliorate both intestinal and remote organ injury following mesenteric ischemia/reperfusion. J Surg Res 2009;157:97-105. [CrossRef]
9. Saral Ö, Yildiz O, Aliyazicioğlu R, Yuluğ E, Canpolat S, Öztürk F, et al. Apitherapy products enhance the recovery of CCL4-induced hepatic damages in rats. Turk J Med Sci 2016;46:194-202. [CrossRef]
10. Tekinbas C, Ulusoy H, Yulug E, Erol MM, Alver A, Yenilmez E, et al. One-lung ventilation: for how long?. J Thorac Cardiovasc Surg 2007;134:405-10. [CrossRef]
11. Altun G, Cakiroglu Y, Pulathan Z, Yulug E, Mentese A. Renoprotective potential of exogen erythropoietin on experimental ruptured abdominal aortic aneurysm model: An animal study. Iran J of Basic Med Sci 2020;23:271.
12. Tokatli F, Uzal C, Doganay L, Kocak Z, Kaya M, Ture M, et al. The potential cardioprotective effects of amifostine in irradiated rats. Int J Radiat Oncol Biol Phys 2004;58:1228-34. [CrossRef]
13. Tokyol C, Yilmaz S, Kahraman A, Cakar H, Polat C. The effects of desferrioxamine and quercetin on liver injury induced by hepatic ischaemia-reperfusion in rats. Acta Chir Belg 2006;106:68-72. [CrossRef]
14. Jaeschke H. Reactive oxygen and mechanisms of inflammatory liver injury: present concepts. J Gastroenterol Hepatol 2011;26:173-9. [CrossRef]
15. Taghizadieh M, Hajipour B, Asl NA, Khodadadi A, Somi MH, Banei M. Combination effect of melatonin and dexamethasone on liver ischemia/reperfusion injury. Bratisl Lek Listy 2016;117:47-53. [CrossRef]
16. Baykara B. 2006 Karaciğer iskemi reperfüzyon hasarında karnozin ve melatonin'in koruyucu etkileri. Doctoral dissertation. Dokuz Eylül University Health Sciences Institute.
17. Hirsch J, Niemann CU, Hansen KC, Choi S, Su X, Frank JA, et al. Alterations in the proteome of pulmonary alveolar type II cells in the rat after hepatic ischemia-reperfusion. Criti Care Med 2008;36:1846. [CrossRef]
18. Yang Z, Deng Y, Su D, Tian J, Gao Y, He Z, et al. TLR4 as receptor for HMGB1-mediated acute lung injury after liver ischemia/reperfusion injury. Lab Invest 2013;93: 792-800. [CrossRef]
19. Oguz A, Kapan M, Kaplan I, Alabalik U, Ulger BV, Uslukaya O, et al. The effects of sulforaphane on the liver and remote organ damage in hepatic ischemia-reperfusion model formed with pringle maneuver in rats. Int J Surg 2015;18:163-8. [CrossRef]
20. Barri YM, Sanchez EQ, Jennings LW, Melton LB, Hays S, Levy MF, et al. Acute kidney injury following liver transplantation: definition and outcome. Liver Transpl 2009;15: 475-83. [CrossRef]
21. Correia Miranda LE, Capellini VK, Reis GS, Celotto AC, Carlotti Jr CG, Evora PRB. Effects of Partial Liver Ischemia Followed by Global Liver Reperfusion on the Remote Tissue Expression of Nitric Oxide Synthase: Lungs and Kidneys. In Transplant Proc 2010;42:1557-62. [CrossRef]
22. Li B, Chen B, Zhang G, Wang K, Zhou L, Hu S. Cell apoptosis and fas gene expression in liver and renal tissues after ischemia-reperfusion injury in liver transplantation. Transplant Proc 2010;42:1550-6. [CrossRef]
23. Takhtfooladi MA, Shahzamani M, Asghari A, Fakouri A. Naloxone pretreatment prevents kidney injury after liver ischemia reperfusion injury. Int Urol Nephrol 2016;48:1113-20. [CrossRef]
24. Papoutsidakis N, Arkadopoulos N, Smyrniotis V, Tzanatos H, Kalimeris K, Nastos K, et al. Early myocardial injury is an integral component of experimental acute liver failure-a study in two porcine models. Arch Med Sci 2011;7:217-23. [CrossRef]
25. Liu H, Guo X, Chu Y, Lu S. Heart protective effects and mechanism of quercetin preconditioning on anti-myocardial ischemia reperfusion (IR) injuries in rats. Gene 2014;545:149-55. [CrossRef]

DENEYSEL ÇALIŞMA - *ÖZ*

Sıçanlarda deneysel karaciğer iskemi-reperfüzyon modelinde karaciğer ve uzak organ hasarının değerlendirilmesi ve bu hasara *quercetin*'in etkileri

AMAÇ: Bu çalışma, sıçanlarda karaciğer iskemi-reperfüzyon modelinde karaciğer, akciğer, böbrek ve kalpte meydana gelen değişiklikleri ve *quercetin*'in bu değişiklikler üzerindeki etkisini histopatolojik ve immünohistokimyasal olarak göstermeyi amaçlamaktadır.
GEREÇ VE YÖNTEM: On sekiz Sprague Dawley sıçan 3 gruba ayrıldı: Grup 1 sham, Grup 2 iskemi-reperfüzyon, Grup 3 iskemi-reperfüzyon + quercetin. 3 gün boyunca Grup 1'e distile su, Grup 3'e ise *quercetin* gavaj yoluyla verildi. 3. günün sonunda Grup 1'e abdominal açma-kapama, Grup 2 ve 3'e ise hepatoduodenal ligament klemplenerek 1 saatlik iskeminin ardından 4 saatlik reperfüzyon uygulandı ve tüm sıçanlar sakrifiye edildi. Karaciğer, akciğer, böbrek ve kalp doku örnekleri hematoksilen eozin (HE), Masson Trikrom, Periyodik Asit-Schiff (PAS) ve apoptozu değerlendirmek için TUNEL (Terminal deoksinükleotidil transferaz (TdT) deoksiüridin trifosfat nick end labeling assay) ile boyandı ve ışık mikroskobu altında histopatolojik ve immünohistokimyasal olarak incelendi.
BULGULAR: Karaciğerde hasar skoru; IR grubunda sham grubuna göre anlamlı derecede yüksek iken, IR+Q grubunda IR grubuna göre anlamlı derecede düşüktü. Yarı kantitatif skorlama parametrelerinde gruplar arasında anlamlı bir fark bulunmazken, apoptotik indeks İR grubunda sham grubuna göre anlamlı derecede yüksek, İR+Q grubunda ise İR grubuna göre anlamlı derecede düşüktü. Akciğerde, akciğer hasarı skorlarında gruplar arasında anlamlı bir fark gözlenmedi. Apoptotik indeks IR grubunda sham grubuna göre anlamlı derecede yüksekken, IR+Q grubunda IR grubuna göre anlamlı derecede düşüktü. Böbreklerde, tübüler hücre dejenerasyonu ve intertübüler vasküler konjesyon IR grubunda sham grubuna göre anlamlı derecede yüksekti. Apoptotik indeks IR grubunda sham ve IR+Q gruplarına göre daha yüksek iken, IR+Q grubunda sham grubuna göre daha yüksekti. Kalpte, miyokardiyal hücre dejenerasyonu ve vasküler hasar açısından gruplar arasında fark yoktu. Apoptotik indeks IR grubunda sham ve IR+Q gruplarına göre anlamlı olarak daha yüksekti.
SONUÇ: Sonuçlarımız, deneysel olarak oluşturulan IR modelinde karaciğer, akciğer, böbrek ve kalpte histopatolojik hasar oluştuğunu ve *quercetin* uygulamasının bu organlarda IR ile ilişkili hasarı ve apoptozisi azalttığını göstermektedir.

Anahtar sözcükler: İskemi-reperfüzyon hasarı; karaciğer; quercetin; uzak organ hasarı.

Ulus Travma Acil Cerrahi Derg 2025;31(9):823-830 DOI: 10.14744/tjtes.2025.61423