ORIGINAL ARTICLE

Impact of traumatic lens injury on visual and anatomical prognosis following open globe injuries: an analysis from a tertiary trauma referral center

Yağmur Seda Yeşiltaş,[1] Hakan Güngör,[2] Ali Hakan Durukan[1]

[1]Department of Ophthalmology, University of Health Sciences, Gülhane Training and Research Hospital, Ankara-*Türkiye*
[2]Department of Ophthalmology, Kars Harakani State Hospital, Kars-*Türkiye*

ABSTRACT

BACKGROUND: This study aims to evaluate the impact of traumatic lens injury on visual and anatomical prognosis in open globe injuries (OGI).

METHODS: The medical charts of patients with OGIs treated at a tertiary ocular trauma referral center between November 2016 and January 2025 were retrospectively reviewed. Patients were categorized into two groups: those with lens injury (LI) and those without lens injury (NLI). Primary outcome measures were final best-corrected visual acuity (BCVA), functional visual success (BCVA ≥ 0.1 [decimal]), and globe survival. Multivariate logistic regression analyses were utilized to model independent predictors of functional visual success and globe survival. Predictor variables were selected based on clinical relevance and prior trauma literature: lens injury, Zone 3 involvement, injury type, number of surgeries, and initial retinal detachment.

RESULTS: A total of 98 eyes were included in the study; 73 eyes had LI, while 25 eyes did not. Eyes with LI had significantly poorer initial BCVA (mean logMAR 2.33 vs. 1.76; p=0.003) and more frequently sustained Zone 1 injuries (p<0.001). Final BCVA (logMAR 1.62 vs. 1.00; p=0.022), functional visual success (23.3% vs. 60.0%; p=0.002), and globe survival (63.0% vs. 88.0%; p=0.037) were all significantly lower in the LI group. In the multivariable analysis, lens injury independently reduced the likelihood of functional visual success (adjusted OR 0.40; 95% CI 0.11–0.81; p=0.019), whereas it was not an independent determinant of globe survival. The presence of initial retinal detachment was the strongest adverse factor for both functional visual success (adjusted OR 0.07; 95% CI 0.02-0.44; p<0.001) and globe survival (adjusted OR 0.13; 95% CI 0.04–0.40; p<0.001).

CONCLUSION: Traumatic lens injury independently predicts poorer functional visual success following OGIs. Retinal detachment at presentation remains the most influential determinant of both visual and anatomical prognosis and holds critical importance in trauma management. Incorporation of lens injury into ocular trauma prognostic scoring systems may improve their predictive accuracy.

Keywords: Globe survival; lensectomy; lens injury; open globe injury; traumatic cataract; visual prognosis.

INTRODUCTION

Ocular trauma remains one of the leading causes of visual loss and, in severe cases, irreversible globe loss worldwide.[1] The standardization of terminology in ocular trauma is crucial for accurate communication, effective counseling patients and families, reliable comparison of studies, and the development of prognostic models. Since 1996, the Birmingham Eye Trauma Terminology (BETT) has become the most widely accepted classification scheme in both clinical and research ocular trauma settings.[2] Within this classification, open globe injury (OGI) represents a severe yet relatively uncommon subset of ocular trauma, with approximately 203,000 cases reported globally each year.[3]

Cite this article as: Yeşiltaş YS, Güngör H, Durukan AH. Impact of traumatic lens injury on visual and anatomical prognosis following open globe injuries: An analysis from a tertiary trauma referral center. Ulus Travma Acil Cerrahi Derg 2026;32:47-54.

Address for correspondence: Yağmur Seda Yeşiltaş
Department of Ophthalmology, University of Health Sciences, Gülhane Training and Research Hospital, Ankara, Türkiye
E-mail: yesiltas.seda@gmail.com

Ulus Travma Acil Cerrahi Derg 2026;32(1):47-54 DOI: 10.14744/tjtes.2025.44183
Submitted: 14.12.2025 Revised: 24.12.2025 Accepted: 27.12.2025 Published: 07.01.2026
OPEN ACCESS This is an open access article under the CC BY-NC license (http://creativecommons.org/licenses/by-nc/4.0/).

The Ocular Trauma Score (OTS) system proposed by Kuhn et al.[4] has become the most widely utilized prognostic tool to assess the visual prognosis following OGI. The OTS is based on initial visual acuity and the presence of globe rupture, endophthalmitis, perforating injury, retinal detachment (RD), and relative afferent pupillary defect (RAPD). Despite being documented in 32–52% of OGI cases, lens injury has not been formally included among these parameters.[5,6]

Lens involvement in OGI may manifest as traumatic cataract with or without capsular rupture, as well as lens subluxation or lens luxation (traumatic aphakia).[7,8] These changes are frequently associated with secondary complications, including phacoanaphylaxis, increased susceptibility to infection, corneal decompensation, and increased intraocular pressure (IOP), all of which necessitate additional surgical interventions."[9,10] In this context, clarifying the prognostic role of lens injury is clinically relevant, given its potential to further compromise visual outcomes.

Although the impact of lens injury on visual prognosis after OGI has been researched in multiple studies, the reported results remain heterogeneous. Some studies reported that lens damage adversely affects visual outcomes, often due to cataract formation or subsequent aphakia.[11-13] In contrast, other studies suggest that lens injury does not independently compromise visual prognosis, particularly when timely and appropriate surgical management is provided.[14,15] Moreover, in cases with traumatic cataract, the timing of cataract extraction was not consistently associated with final visual acuity.[14,16]

Given these contradictory findings, further research is warranted to clarify whether traumatic lens injury carries independent prognostic value beyond established parameters such as OTS. Therefore, this study aims to evaluate the impact of traumatic lens injury on visual and anatomical outcomes in patients with OGI treated at a major tertiary ocular trauma referral center in Türkiye.

MATERIALS AND METHODS

Study Design and Population

This retrospective study was approved by the local institutional review and ethics board (IRB #2024-577). The study adhered to the principles of the Declaration of Helsinki. Medical charts of all consecutive patients with OGI who were treated at a tertiary ocular trauma referral center between November 2016 and January 2025 were reviewed. Patients with missing medical records; those with pre-existing or trauma-related macular or optic disc pathology that could affect visual acuity; those with a history of prior cataract surgery in the injured eye; those who presented with end-stage ocular conditions that precluded further treatment (e.g., phthisis bulbi); and those with a follow-up period of <6 months were excluded from the analysis.

Clinical Evaluation and Surgical Management

Except for three individuals, almost all patients had received primary globe repair before being referred to our center. All patients subsequently underwent comprehensive ophthalmic evaluations both before and after surgery, including visual acuity, IOP, slit lamp and fundus examination, supplemented by ocular ultrasonography and computed tomography of the orbits. The ocular injuries were categorized using the BETT system.[17] The OTS was calculated according to the methodology proposed by Kuhn et al.[4]

As a tertiary ocular trauma referral center, most cases required one or more secondary surgical procedures, including vitrectomy procedures, intraocular foreign body (IOFB) removal, and lensectomy when indicated. Primary or secondary intraocular lens (IOL) implantation was determined by capsular integrity and the extent of ocular tissue damage.

Outcome Measures

Patient demographic and clinical information were obtained from patient medical records and included age, sex, laterality, injury type (mechanism), cause of injury, zone of injury, lens injury status, associated ocular findings at initial exam (endophthalmitis and RD), time to second surgery, time to lensectomy (in eyes with lens injury), IOL implantation timing and method, number of surgeries, best-corrected visual acuity (BCVA) at initial and last follow-up, development of secondary glaucoma, functional visual success, and globe survival.

Patients were categorized into lens injury (LI) and no lens injury (NLI) groups. As primary outcomes, BCVA at last follow-up, functional visual success, and globe survival were compared between LI and NLI groups. Secondary outcomes were time to second surgery, number of surgeries, and secondary glaucoma rate.

Lens injury was defined as any traumatic structural disruption of the lens capsule, zonules, or nucleus, including traumatic cataract, lens subluxation, or lens luxation (traumatic aphakia). Best-corrected visual acuity values were expressed in logarithm of the minimum angle of resolution (logMAR) notation, as described by Ferris et al.[18] Hand movements (HM) and counting fingers (CF) vision were assigned logMAR values of 3.0 and 2.0, respectively, according to the method proposed by Holladay.[19] In this study, light perception (LP) was given a logMAR value of 4.0,[20] whereas no light perception (NLP) was not assigned a logMAR value. Functional visual success was defined as final BCVA ≥ 0.1 (decimal). This threshold corresponds to ambulatory vision and exceeds the legal definition of blindness widely used in the United States, in which visual acuity of ≤ 20/200 (approximately decimal 0.1) in the better-seeing eye constitutes legal blindness.[21] The cutoff is also consistent with the World Health Organization (WHO) classification of visual impairment, where vision worse than 20/200 is categorized as severe visual impairment.[22] Globe survival was defined as complete retinal attachment, intraocular pressure above 6 mmHg, and BCVA of LP

or better at final follow-up.

Statistical Analysis

All statistical analyses were performed using IBM SPSS Statistics for Windows (Version 21.0; IBM Corp., Armonk, NY, USA). A p-value of <0.05 was considered statistically significant. Continuous variables were assessed for normality using the Shapiro–Wilk test and are presented as mean ± standard deviation (SD) and median with interquartile range (IQR). Comparisons between LI and NLI groups were performed using the Mann–Whitney U test due to the non-normal distribution of most continuous variables. Categorical variables are presented as numbers (n) and percentages (%). Group comparisons were carried out using the Chi-square test or Fisher's exact test when expected cell counts were <5.

Multivariate logistic regression analyses were utilized to model independent predictors of functional visual success and globe survival. Predictor variables were selected based on clinical relevance and prior trauma literature: lens injury, Zone 3 involvement, injury type, number of surgeries, and initial RD. Effect estimates were expressed as odds ratios (ORs) with 95% confidence intervals (CIs).

RESULTS

A total of 217 patients with OGIs were identified during the study period, and 98 eyes from 84 patients met the inclusion criteria. Of these, 73 eyes (74.5%) had lens injury and 25 eyes (25.5%) had no lens injury.

Baseline Characteristics

Demographics, injury characteristics, and associated clinical findings in eyes with and without lens injury are presented in Table 1. The two groups were comparable with respect to age (median, 30 vs. 26 years; p=0.769) and sex distribution (male proportion, 95.9% vs. 96.0%; p=1.000). The distribu-

Table 1. Demographics, injury characteristics, and associated clinical findings in eyes with and without lens injury

Variable	Lens injury (n=73)	No lens injury (n=25)	p value
Age (years)	31.8±15.3; 30 [17]	30.0±10.5; 26 [11]	0.769
Sex (#males, %)	70 (95.9%)	24 (96.0%)	1.000
Injury type			
Rupture	7 (9.6%)	1 (4.0%)	0.339
Penetrating	30 (41.1%)	11 (44.0%)	
IOFB	23 (31.5%)	5 (20.0%)	
Perforating	13 (17.8%)	8 (32.0%)	
Cause of injury			
Deadly weapon-related	26 (35.6%)	7 (28.0%)	0.319
Sharp-object injury	22 (30.1%)	10 (40.0%)	
Domestic accident	13 (17.8%)	13 (17.8%)	
Blunt trauma	12 (16.4%)	12 (16.4%)	
Zone of injury			
Zone 1	50 (68.5%)	6 (24.0%)	<0.001
Zone 2	17 (23.3%)	4 (16.0%)	
Zone 3	0 (0%)	11 (44.0%)	
Zone 2 and 3	6 (8.2%)	11 (44.0%)	
Endopthalmitis	0 (%)	0 (%)	-
Initial RD	34 (46.6%)	14 (56.0%)	0.457
OTS	60.9±14.6; 59 [23]	68.6±15.9; 76 [24]	0.040
OTS category			
Category 1	11 (15.1%)	0 (0%)	0.066
Category 2	28 (38.4%)	9 (36.0%)	
Category 3	32 (43.8%)	13 (52.0%)	
Category 4	2 (2.7%)	3 (12.0%)	
Initial BCVA (LogMAR)	2.33±0.63; 2.0 [1.0]	1.76 ± 0.84; 2.0 [1.08]	0.003

BCVA: Best corrected visual acuity, IOFB: Intraocular foreign body, OTS: Ocular trauma score, RD: Retinal detachment. Values are presented as mean ± standard deviation; median [interquartile range] for continuous variables, and n (%) for categorical variables. p-values obtained using the Mann–Whitney U test (continuous variables) or Chi-square /Fisher's exact test (categorical variables).

Table 2. Surgical procedures, visual and anatomical outcomes in eyes with and without lens injury

Variable	Lens injury (n=73)	No lens injury (n=25)	p value
Time to secondary surgery (days)	23.2±24.8; 14 [20]	21.4±18.4; 17.5 [11.5]	0.709
Time to lensectomy (days)	27.0±34.2; 14 [21]	N/A	-
Total number of surgeries	3.21±1.67; 3 [2]	2.68±1.11; 2 [2]	0.202
Follow-up, months	37.8±25.3; 32 [38]	35.9±20.1; 37 [26]	0.922
Secondary glaucoma	9/73 (12.3%)	3/25 (12.0%)	1.000
Final BCVA (LogMAR)	1.62±1.04; 2.0 [1.60]	1.00±1.10; 0.30 [1.90]	0.022
Functional visual success	17/73 (23.3%)	15/25 (60.0%)	0.002
Globe survival	46/73 (63.0%)	22/25 (88.0%)	0.037

BCVA: Best corrected visual acuity. Values are presented as mean ± standard deviation; median [interquartile range] for continuous variables, and n (%) for categorical variables. p-values obtained using the Mann–Whitney U test (continuous variables) or Chi-square /Fisher's exact test (categorical variables).

tion of injury type (globe rupture, penetrating injury, IOFB, perforating injury) and the cause of trauma did not differ significantly between the groups. Injury zone differed significantly between groups, with Zone 1 injuries more common in the LI group (68.5%), while Zone 3 and combined Zone 2/3 injuries were more frequent in the NLI group (p<0.001). Endophthalmitis at presentation was not identified in either group. Initial RD rates were similar (46.6% vs. 56.0%; p = 0.457). OTS scores were significantly higher in the NLI group (mean 68.6±15.9) than in the LI group (mean 60.9±14.6), indicating less severe injury in eyes without lens involvement. Initial BCVA was significantly worse in the LI group (mean logMAR 2.33 vs. 1.76; p=0.003).

Lens Injury Characteristics and Surgical Management

Among the 73 eyes with lens injury, traumatic cataract was noted in 42 eyes (57.5%), lens subluxation in 12 eyes (16.4%), and lens luxation (traumatic aphakia) in 19 eyes (26.1%). Lensectomy varied according to the extent and morphology of the lens damage. Lensectomy was performed in the majority of eyes (50 eyes, 92.6%) with a median of 15 days after primary globe repair, whereas in 4 eyes the procedure was conducted concurrently with primary globe repair.

Of the eyes with lens injury, 49 (67.1%) received IOL implantation, while 24 eyes (32.9%) were left aphakic. Among those who underwent IOL implantation, 29 eyes (59.2%) received the IOL during the lensectomy procedure, whereas 20 eyes (40.8%) underwent secondary implantation. In terms of fixation techniques, 20 eyes (40.8%) had in-the-bag IOL placement, 17 eyes (34.7%) required scleral fixation, and 12 eyes (24.5%) received a sulcus-placed IOL.

Visual and Anatomical Outcomes

Surgical procedures, visual and anatomical outcomes in eyes with and without lens injury are summarized in Table 2. The median follow-up duration was 32 months (range: 6–85 months) in the LI group and 37 months (range: 10–80 months) in the NLI group. Regarding surgical variables, time to secondary surgery, total number of surgeries, and follow-up duration did not differ significantly between groups. Eyes without lens injury achieved significantly better final BCVA (mean logMAR 1.00 vs. 1.62; p=0.022) and significantly higher rates of functional visual success, defined as final decimal VA ≥0.1 (60.0% vs. 23.3%; p=0.002). Secondary glaucoma rates did not differ between groups. Globe survival, defined as retinal attachment with IOP > 6 mmHg and LP vision or better, was significantly higher in the NLI group (88.0% vs. 63.0%; p=0.037).

Multivariate Analysis

Multivariate logistic regression analyses were performed to identify independent predictors of functional visual success and globe survival after OGI (Table 3). Forest plot representations of the multivariate models are provided in Figure 1. Independent predictors included lens injury, Zone 3 involvement, injury type, number of surgeries, and initial RD. In the model for functional visual success, initial RD had the strongest negative impact on visual outcomes (adjusted OR 0.07; 95% CI 0.02-0.44; p<0.001). Lens injury (adjusted OR 0.40; 95% CI 0.11-0.81; p=0.019) and a higher number of surgeries (adjusted OR 0.53; 95% CI 0.31–0.91; p=0.022) were also independently associated with reduced functional visual success.

In the model for globe survival, initial RD remained the dominant independent predictor of globe survival (adjusted OR 0.13; 95% CI 0.04-0.40; p<0.001). Injury type also demonstrated a significant association with globe survival (adjusted OR 1.86; 95% CI 1.04–3.32; p=0.035), with rupture and perforating injuries showing poorer anatomical prognosis. A higher number of surgeries showed a modest but statistically significant association with poorer globe survival (adjusted OR 1.58; 95% CI 1.04–2.40; p=0.030). However, lens injury

Table 3. Multivariate logistic regression analysis of functional visual success and globe survival after open globe injury.

	Functional visual success			Globe survival		
Predictor	**Adjusted OR**	**95% CI**	**p value**	**Adjusted OR**	**95% CI**	**p value**
Lens injury	0.40	0.11-0.81	0.019	0.24	0.06-1.01	0.050
Zone 3 (vs Zone I-2)	1.41	0.26-5.33	0.620	1.23	0.08-17.91	0.881
Injury type	1.03	0.35-1.87	0.617	1.86	1.04-3.32	0.035
Number of surgeries	0.53	0.31-0.91	0.022	1.58	1.04-2.40	0.030
Initial RD	0.07	0.02-0.44	<0.001	0.13	0.04-0.40	<0.001

BCVA: Best corrected visual acuity; CI: Confidence interval; IOFB: Intraoculer foreign body; OR: Odd ratio; OTS: Ocular trauma score; RD: Retinal detachment.

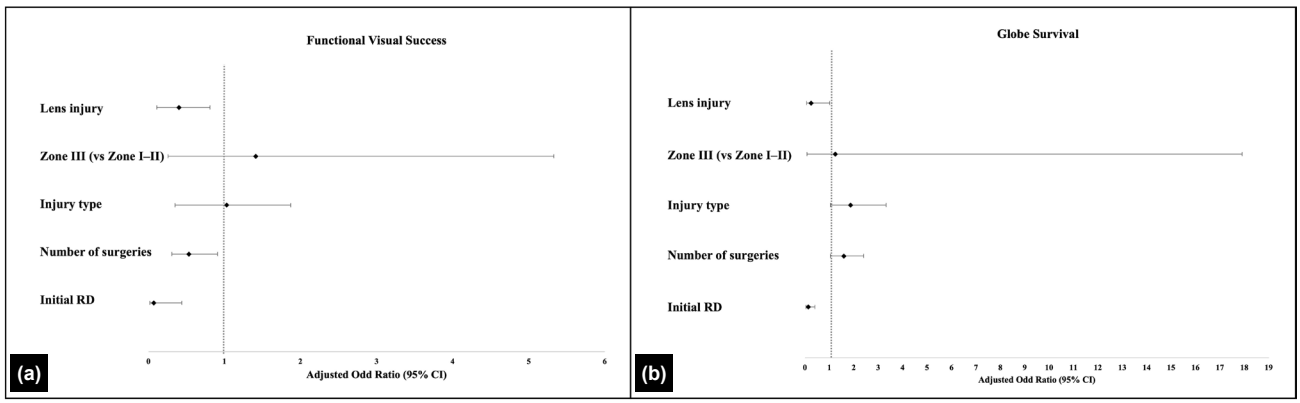

Figure 1. Forest plots showing adjusted odds ratios (ORs) for predictors of **(a)** functional visual success and (**b)** globe survival after open globe injury. Lens injury, initial retinal detachment, and the number of surgeries significantly influenced functional outcomes, while globe survival was primarily determined by initial retinal detachment, injury type, and surgical burden. Error bars indicate 95% confidence intervals.

demonstrated a borderline association (adjusted OR 0.24; 95% CI 0.06–1.01; p=0.051).

DISCUSSION

The present study evaluates the prognostic role of traumatic lens injury in OGI by comparing demographic features, surgical approaches, and visual and anatomical outcomes. Our findings indicate a distinct divergence between functional visual recovery and anatomical globe survival, revealing that lens involvement is associated with poorer functional outcomes, but it does not independently determine anatomical prognosis after adjusting for injury severity markers.

The high rate of lens injury observed in our cohort (74.5%) lies within the higher spectrum of rates reported by major tertiary ocular trauma referral centers, where lens involvement has been documented in approximately 32% to 52% of OGIs.[5,6] Studies focusing on referral populations and high-energy trauma mechanisms have reported particularly elevated rates of lens damage, reflecting greater injury severity. As a tertiary referral center, our institution predominantly manages complex cases following primary globe repair, which likely contributes to the higher prevalence of lens injury observed in this study.

In line with our results, multiple studies have demonstrated that traumatic lens injury is associated with worse visual outcomes.[8,13,23-25] Chou et al.[8] reported that eyes with lens involvement at Zone 1–2 OGIs had significantly poorer final BCVA (median logMAR of 2.3 in the LI group compared to 1.3 in the NLI group) and a substantially higher rate of endophthalmitis, reflecting the additive inflammatory and infectious risks associated with capsule violation. In combat-related ocular trauma, Smith et al.[24] showed that lens damage, especially when caused by improvised explosive devices, commonly coexisted with severe corneal and retinal pathologies and contributed to reduced visual recovery. Likewise, in a univariate analysis of preoperative factors, Agrawal et al.[25] identified traumatic cataract as a marker of poor visual prognosis in Zone 3 injuries. Although these studies evaluated different injury subsets (focusing exclusively on Zone 1–2 or Zone 3 involvement), our findings suggest that lens injury

constitutes a significant functional burden in OGI regardless of injury zone.

Conversely, some studies have questioned whether lens injury independently predicts visual outcomes when accounting for overall trauma severity. Rodrigues et al.,[14] analyzing 102 OGI cases with and without lens damage, found that traumatic cataract was associated with poor visual outcomes but did not remain a significant predictor in multivariate analysis once RD, scleral laceration, and hyphema were included. In contrast, a previous study conducted at our ocular trauma referral center showed that, in addition to initial visual acuity (OR: 8.7) and the OTS category (OR: 5.7), the zone of injury (OR: 3.0), the need for additional surgeries (OR: 2.8), and initial lens damage (OR: 1.6) were associated with poorer visual outcomes in OGI.[13] Our current analysis, by directly comparing LI and NLI eyes within a homogeneous OGI population and modeling initial RD as an independent predictor, was able to isolate the functional impact of lens injury and demonstrate its independent prognostic contribution. These findings suggest that lens injury meaningfully influences visual outcome when posterior severity is adequately accounted for, rather than being overshadowed by it.

Another key finding of our analysis is the consistently dominant role of initial RD as an adverse prognostic factor for functional and anatomical results. In agreement with our study, Chou et al.[8] demonstrated that the presence of RD with lens injury at presentation dramatically worsened final visual outcomes in Zone 1–2 OGIs. Similarly, Rodrigues et al.[14] identified RD as the strongest independent predictor of poor final visual acuity in their OGI cohort. A military trauma cohort had comparable results, with RD present in 39.3% of cases and serving as a principal determinant of severe visual impairment and structural loss. Our results confirm this universal pattern, showing that initial RD is by far the most influential determinant of both functional visual success (OR: 0.07) and anatomical globe survival (OR: 0.13).

Interestingly, although Zone 3 injuries have consistently been associated with poor outcomes in OGI across several large studies,[13,23,26] Zone 3 involvement did not independently predict either functional visual success or globe survival in our multivariate model. Several explanations can account for this: (1) Zone 3 injuries were relatively infrequent in our sample; (2) their adverse impact may have been fully mediated through RD, which was modeled explicitly; and (3) logistic regression can exhibit quasi-separation when the number of Zone 3 cases is small. Thus, our findings should not be interpreted as conflicting with prior evidence but rather as reflecting dataset characteristics and the statistical dominance of RD as a posterior segment predictor.

In our study, the number of surgeries emerged as a significant independent predictor of both worse visual and anatomical outcomes. Consistent with the prognostic analysis by Guven et al.,[13] eyes requiring repeated interventions tend to represent more severe or complicated trauma patterns and achieve inferior visual outcomes.[27] Since the total number of surgeries did not differ significantly between LI and NLI groups in our dataset, our results reinforce the view that surgical burden serves as a surrogate for underlying trauma severity and postoperative complications.

Existing literature on IOL implantation timing and technique supports that surgical details themselves are not independent determinants of visual prognosis in traumatic cataract. Rumelt and Rehany found comparable visual recovery regardless of whether IOL implantation was performed primarily or secondarily.[28] Similarly, Chou et al.[8] demonstrated that secondary IOL implantation, regardless of IOL location, yielded functional outcomes equivalent to those of primary procedures. In our cohort, various IOL implantation timings and fixation techniques, including in-the-bag, sulcus, and scleral fixation, were used among eyes with lens injury; however, the study was not designed to statistically evaluate whether these different approaches influenced final BCVA. Therefore, no conclusions regarding the prognostic relevance of IOL timing or implantation site can be drawn from the present data.

The strengths of this study include a relatively large single-center cohort, the use of standardized injury classification systems, including BETT and OTS, together with a consistent surgical approach that reflects real-world trauma care. In addition, the use of multivariate models allowed us to distinguish functional from anatomical predictors, an approach not commonly undertaken in prior OGI studies.

Several limitations should also be acknowledged. The retrospective design and the limited number of Zone 3 injuries may have reduced statistical power in subgroup analyses. As a tertiary trauma referral center, our cohort may also be subject to referral bias.

CONCLUSION

In conclusion, traumatic lens injury is associated with poorer functional visual recovery after OGIs, while anatomical globe survival is determined predominantly by posterior segment pathology-particularly RD-and injury mechanism rather than lens status. This distinction underscores the need to consider functional and anatomical prognostic pathways separately in OGI. Lens injury may therefore be more appropriately viewed as a marker of functional prognosis and could be considered in future refinements of OTS-based assessment systems. Such an approach may aid clinical decision-making and patient counseling, particularly in complex trauma settings.

Ethics Committee Approval: This study was approved by the Health Sciences University Gülhane Sientific Researches Ethics Committee (Date: 10.12.2024, Decision No: 2024-577).

Peer-review: Externally peer-reviewed.

Authorship Contributions: Concept: Y.S.Y., H.G., A.H.D.;

Design: Y.S.Y., H.G., A.H.D.; Supervision: Y.S.Y., H.G., A.H.D.; Resource: Y.S.Y., H.G., A.H.D.; Materials: A.H.D.; Data collection and/or processing: Y.S.Y., H.G.; Analysis and/or interpretation: Y.S.Y., H.G., A.H.D.; Literature review: Y.S.Y., H.G.; Writing: Y.S.Y., H.G., A.H.D.; Critical review: A.H.D.

Conflict of Interest: None declared.

Financial Disclosure: The author declared that this study has received no financial support.

REFERENCES

1. Thylefors B. Epidemiological patterns of ocular trauma. Aust N Z J Ophthalmol 1992;20:95–8. [CrossRef]
2. Kuhn F, Morris R, Witherspoon CD, Heimann K, Jeffers JB, Treister G. A standardized classification of ocular trauma. Graefes Arch Clin Exp Ophthalmol 1996;234:399–403. [CrossRef]
3. Negrel AD, Thylefors B. The global impact of eye injuries. Ophthalmic Epidemiol 1998;5:143–69. [CrossRef]
4. Kuhn F, Maisiak R, Mann L, Mester V, Morris R, Witherspoon CD. The Ocular Trauma Score (OTS). Ophthalmol Clin North Am 2002;15:163–5. [CrossRef]
5. Dannenberg AL, Parver LM, Brechner RJ, Khoo L. Penetration eye injuries in the workplace. The National Eye Trauma System Registry. Arch Ophthalmol 1992;110:843–8. [CrossRef]
6. Mansouri M, Faghihi H, Hajizadeh F, Rasoulinejad SA, Rajabi MT, Tabatabaey A, et al. Epidemiology of open-globe injuries in Iran: analysis of 2,340 cases in 5 years report no. 1. Retina 2009;29:1141–9. [CrossRef]
7. Shoshany TN, Torjani A, Zhang Q, Syed ZA. Management and outcomes of traumatic cataract during open globe repair. Am J Ophthalmol 2024;266:248–54. [CrossRef]
8. Chou BW, Feng S, Ding L, Mudumbai RC. Lens injury in setting of zone I and II open globe injuries. Indian J Ophthalmol 2025;73:59–63. [CrossRef]
9. Muga R, Maul E. The management of lens damage in perforating corneal lacerations. Br J Ophthalmol 1978;62:784–7. [CrossRef]
10. Moisseiev J, Segev F, Harizman N, Arazi T, Rotenstreich Y, Assia EI. Primary cataract extraction and intraocular lens implantation in penetrating ocular trauma. Ophthalmology 2001;108:1099–103. [CrossRef]
11. Pieramici DJ, Au Eong KG, Sternberg P Jr, Marsh MJ. The prognostic significance of a system for classifying mechanical injuries of the eye globe in open-globe injuries. J Trauma 2003;54:750–4. [CrossRef]
12. Thompson CG, Kumar N, Billson FA, Martin F. The aetiology of perforating ocular injuries in children. Br J Ophthalmol 2002;86:920–2. [CrossRef]
13. Guven S, Durukan AH, Erdurman C, Kucukevcilioglu M. Prognostic factors for open-globe injuries: variables for poor visual outcome. Eye Lond 2019;33:392–7. [CrossRef]
14. Rodricks D, Loya A, Mohamed M, Al-Mohtaseb Z. Visual outcomes of open globe injury patients with traumatic cataracts. Int Ophthalmol 2022;42:2039–46. [CrossRef]
15. Lee CH, Lee L, Kao LY, Lin KK, Yang ML. Prognostic indicators of open globe injuries in children. Am J Emerg Med 2009;27:530–5. [CrossRef]
16. Tabatabaei SA, Rajabi MB, Tabatabaei SM, Soleimani M, Rahimi F, Yaseri M. Early versus late traumatic cataract surgery and intraocular lens implantation. Eye Lond 2017;31:1199–204. [CrossRef]
17. Kuhn F, Morris R, Witherspoon CD. Birmingham Eye Trauma Terminology BETT: terminology and classification of mechanical eye injuries. Ophthalmol Clin North Am 2002;15:139–43. [CrossRef]
18. Ferris FL 3rd, Kassoff A, Bresnick GH, Bailey I. New visual acuity charts for clinical research. Am J Ophthalmol 1982;94:91–6. [CrossRef]
19. Holladay JT. Proper method for calculating average visual acuity. J Refract Surg 1997;13:388–91. [CrossRef]
20. Ozdek S, Hasanreisoglu M, Yuksel E. Chorioretinectomy for perforating eye injuries. Eye Lond 2013;27:722–7. [CrossRef]
21. National Research Council US Committee on Disability Determination for Individuals with Visual Impairments. Visual impairments: determining eligibility for social security benefits. Washington DC: National Academies Press US; 2002.
22. World Health Organization. List of official ICD-10 updates ratified October 2006. Geneva: World Health Organization; 2006.
23. Fujikawa A, Mohamed YH, Kinoshita H, Matsumoto M, Uematsu M, Tsuiki E, et al. Visual outcomes and prognostic factors in open-globe injuries. BMC Ophthalmol 2018;18:138. [CrossRef]
24. Smith MP, Colyer MH, Weichel ED, Stutzman RD. Traumatic cataracts secondary to combat ocular trauma. J Cataract Refract Surg 2015;41:1693–8. [CrossRef]
25. Agrawal R, Ho SW, Teoh S. Pre-operative variables affecting final vision outcome with a critical review of ocular trauma classification for posterior open globe zone III injury. Indian J Ophthalmol 2013;61:541–5. [CrossRef]
26. Bauza AM, Emami P, Soni N, Holland BK, Langer P, Zarbin M, et al. A 10-year review of assault-related open-globe injuries at an urban hospital. Graefes Arch Clin Exp Ophthalmol 2013;251:653–9. [CrossRef]
27. Pieramici DJ, MacCumber MW, Humayun MU, Marsh MJ, de Juan E Jr. Open-globe injury. Update on types of injuries and visual results. Ophthalmology 1996;103:1798–803. [CrossRef]
28. Rumelt S, Rehany U. The influence of surgery and intraocular lens implantation timing on visual outcome in traumatic cataract. Graefes Arch Clin Exp Ophthalmol 2010;248:1293–7. [CrossRef]

ORİJİNAL ÇALIŞMA - *ÖZ*

Travmatik lens hasarının açık göz yaralanmalarında görsel ve anatomik prognoza etkisi: Üçüncü basamak travma sevk merkezinden bir analiz

AMAÇ: Bu çalışmada açık göz yaralanmalarında (AGY) travmatik lens hasarının görsel ve anatomik sonuçlar üzerindeki etkisinin değerlendirilmesi amaçlanmıştır.

GEREÇ VE YÖNTEM: Kasım 2016-Ocak 2025 arasında üçüncü basamak bir oküler travma referans merkezinde tedavi edilen AGY'li olgulara ait tıbbi kayıtlar retrospektif olarak incelendi. Olgular, lens hasarı varlığına göre lens hasarı olan (LH) ve olmayan (LHO) olmak üzere 2 gruba ayrıldı. Birincil sonuçlar; son vizitteki en iyi düzeltilmiş görme keskinliği (EİDGK), fonksiyonel görsel başarı (EİDGK ≥0.1 [ondalık]) ve glob sağkalımı idi. Fonksiyonel görsel başarı ve glob sağkalımını etkileyen bağımsız faktörler çok değişkenli lojistik regresyon analizi ile değerlendirildi. Önceki literatür ve klinik önemleri temel alınarak belirlenen bağımsız faktörler; lens etkilenimi, Zon 3 tutulumu, yaralanma tipi, cerrahi sayısı ve başlangıç retina dekolmanı varlığı idi.

BULGULAR: Çalışmaya toplam 98 göz dahil edildi; 73 gözde LH mevcut iken, 25 gözde lens hasarı izlenmedi. Lens hasarlı gözlerde başlangıç EİDGK anlamlı derecede daha düşüktü (ortalama logMAR 2.33 ve 1.76; p=0.003) ve Zon 1 yaralanmaları daha sık izlenmekteydi (p<0.001). Son EİDGK (logMAR 1.62 ve 1.00; p=0.022), fonksiyonel görsel başarı (%23.3 ve %60.0; p=0.002) ve glob sağkalımı (%63.0 ve %88.0; p=0.037) LH grubunda anlamlı olarak daha düşüktü. Çok değişkenli analizde lens hasarının fonksiyonel görsel başarı olasılığını bağımsız olarak azalttığı saptandı (düzeltilmiş OR 0.40; %95 GA 0.11–0.81; p=0.019); ancak glob sağkalımında bağımsız bir belirleyici değildi. Başlangıç retina dekolman varlığı, hem fonksiyonel görsel başarı (düzeltilmiş OR 0.07; %95 GA 0.02–0.44; p<0.001) hem de glob sağkalımı için (düzeltilmiş OR 0.13; %95 GA 0.04–0.40; p<0.001) için en güçlü olumsuz faktör olarak belirlendi.

SONUÇ: Travmatik lens hasarı, AGY sonrası fonksiyonel görsel başarının bağımsız bir göstergesidir. Başlangıç retina dekolmanı ise hem görsel hem anatomik prognozu belirleyen en önemli etken olup, travma yönetiminde kritik öneme sahiptir. Lens hasarının oküler travma skorlama sistemlerine dahil edilmesi, prognozun daha doğru öngörülmesine katkı sağlayabilir.

Anahtar sözcükler: Açık göz yaralanması; glob sağkalımı; görsel prognoz; lens hasarı; lensektomi; travmatik katarakt.

Ulus Travma Acil Cerrahi Derg 2026;32(1):47-54 DOI: 10.14744/tjtes.2025.44183